Iranian Journal of Veterinary Surgery

ORIGINAL ARTICLE

Protective Role of Melatonin on Testicular Function, BCL-2 Expression, and Platelet Indices in Varicocele-Induced Mature Rats

Mohammad Hossein Fayazi[1], Hamid Reza Moslemi ✉[1], Mahmood Ahmadi-Hamedani[1], Hamid Staji[2]

[1] Department of Clinical Sciences, Faculty of Veterinary Medicine, Semnan University, Semnan, Iran. [2] Department of Pathobiology, Faculty of Veterinary Medicine, Semnan University, Semnan, Iran.

ARTICLE INFO

Article History:

Received: 30 July 2025
Revised: 12 December 2025
Accepted: 27 December 2025

Keywords:

BCL-2
Melatonin
Platelet indices
Testosterone
Varicocele

ABSTRACT

Varicocele is a common disorder in men characterized by abnormal dilation and tortuosity of the pampiniform venous plexus, often leading to testicular dysfunction. This study evaluated the protective effects of melatonin on serum testosterone levels, testicular histopathology, B-cell lymphoma 2 (BCL-2) gene expression, and platelet indices in experimentally induced varicocele in rats. Twenty-four adults male Wistar rats (7 weeks old) were randomly divided into four groups (n = 6): Control (sham-operated + saline), VC (varicocele-induced + saline), MEL (sham + melatonin 5 mg/kg orally), and VC-MEL (varicocele-induced + melatonin 5 mg/kg for 4 weeks). Body weight (BW1, BW2), testes weight (TW), hormone levels, BCL-2 mRNA expression, and platelet parameters were analyzed. The VC group showed the greatest BW2 reduction and lowest TW (213.84 g and 0.604 g, respectively), along with the lowest BCL-2 expression (0.102) and testosterone levels (0.87 ng/ml). Histologically, only spermatocyte cells were observed in this group based on Johnson's score. The control group had the highest platelet count (PLT: 241.004 $\times 10^3/\mu l$), while the VC group exhibited elevated PCT (0.42%), MPV (5.96 fL), and PDW (18.4%). Melatonin administration significantly improved all measured parameters, likely due to its antioxidant and anti-inflammatory properties. It enhanced testosterone production, upregulated BCL-2 expression, improved testicular histology, and normalized platelet indices. These findings suggest that melatonin may offer therapeutic benefits in managing varicocele-related damage in experimental models.

Introduction

Varicocele is a common condition in men characterized by abnormal dilation and tortuosity of the spermatic veins, affecting approximately 10–15% of the male population. Clinical manifestations vary widely among individuals, including differences in severity grading, pain intensity, and impact on fertility, contributing to inconsistencies in diagnosis and treatment timing. Although recognized as a major treatable cause of male infertility, varicocele has also been reported in fertile men. Three main pathogenic mechanisms have been proposed: (1) venous valve dysfunction causing retrograde blood flow; (2) anatomical differences in vein angles between the left renal vein and vena cava; and (3) external compression of the left renal vein by the superior mesenteric artery—known as the "nutcracker effect"—leading to increased venous pressure and reflux.[1] Despite extensive research, the full pathogenesis remains unclear, involving upright posture-related hemodynamic changes, oxidative stress (OS), inflammation, and heat stress. OS, driven by excessive reactive oxygen species (ROS), plays a central role in testicular damage and male infertility associated with

✉ Corresponding author. Email: h.moslemi@semnan.ac.ir
© Iranian Veterinary Surgery Association, 2026
https://doi.org/10.30500/ivsa.2025.538017.1456

This work is licensed under the Creative Commons Attribution-NonCommercial 4.0 International License. To view a copy of this license, visit http://creativecommons.org/licenses/by-nc/4.0/

varicocele.[1] Men with varicocele often show elevated levels of sperm DNA fragmentation, lipid peroxidation, and abnormal morphology, along with reduced protamine content.[2]

Apoptosis, a tightly regulated mechanism for eliminating damaged or unnecessary cells, is dysregulated in varicocele-induced testicular dysfunction. The B-cell lymphoma 2 (BCL-2) family proteins regulate apoptosis, with some members inhibiting cell death (e.g., BCL-2, BCL-XL, MCL-1), and others promoting it (e.g., BAX, BAK, BAD).[3] In spermatogenesis, apoptosis plays a crucial role in balancing germ cell numbers during mitosis, meiosis, and maturation. Disruption of this process can impair fertility. Testosterone deficiency, defined by low serum testosterone and related symptoms, affects multiple organ systems beyond sexual function.[4] Varicocele is associated with smaller, softer testes and lower testosterone levels, especially in older patients with bilateral or high-grade disease.[5] Elevated scrotal temperature due to varicocele damages Leydig cells, reduces Sertoli cell function, and impairs spermatogenesis. Histopathological findings in experimental models include loss of seminiferous tubules, interstitial edema, connective tissue proliferation, and arrested sperm maturation.[6] Human studies also report germ cell sloughing, Sertoli cell detachment, basement membrane thickening, and Leydig cell atrophy or hyperplasia.[7] These changes highlight the variable impact of varicocele on testicular architecture.

Platelets play a vital role in hemostasis, with their size reflecting functional status. Mean platelet volume (MPV) reflects platelet activation and is elevated in cardiovascular diseases.[8] Platelet distribution width (PDW) indicates variability in platelet size and is used as an inflammatory marker. Low platelet counts with increased MPV have been linked to varicocele.[9] Melatonin (N-acetyl-5-methoxytryptamine), primarily secreted by the pineal gland at night, is also synthesized in extrapineal tissues such as the skin, gut, and kidney.[10] With potent antioxidant, anti-inflammatory, and anti-apoptotic properties, melatonin modulates immune responses, hormone secretion, and cellular survival.[11] It shows therapeutic potential in neurodegenerative disorders like Alzheimer's, Parkinson's, and Huntington's disease, and protects against ischemia-reperfusion injury in myocardial infarction and stroke.[12] Melatonin also exhibits antitumor effects by suppressing cancer cell growth and protecting normal cells from apoptosis.[13]

In male reproduction, melatonin enhances Leydig cell function, increases serum and testicular testosterone bioavailability, and reduces gonadotropin levels (FSH, LH).[14] Its antioxidant activity includes scavenging free radicals, enhancing superoxide dismutase and glutathione peroxidase activity, stimulating glutathione production, and activating DNA repair enzymes.[15] Lower melatonin levels in seminal fluid and serum have been observed in infertile men, particularly those with varicocele. However, its exact protective role in varicocele remains incompletely understood. Therefore, this study aimed to evaluate the effects of melatonin administration on BCL-2 gene expression, testosterone levels, and platelet indices in an experimental rat model of varicocele.

Materials and Methods

Experimental Animals

Twenty-four mature male Wistar rats, aged seven weeks and weighing between 290 and 310 grams, were acquired from the Laboratory Animal Center. They were kept in custom cages with 12 hours of light, temperatures maintained at 19-25 °C, and humidity levels maintained at 45-55%. During the week leading up to the experiment, the rats became familiar with their surroundings and ate pellets. They had unrestricted access to water. The study followed ethical principles approved (Ethical code: IR.SU.REC.1401.4) by the International Committees for the Protection of Laboratory Animals.

Experimental Design

In the current study, the rats were divided into four groups (6 rats each):

Control group (group I): Rats that underwent laparotomy surgery without varicocele induction and received normal saline orally for up to 4 weeks.

VC group (group II): Rats in which varicocele is induced and receive normal saline orally for up to 4 weeks.

MEL group (group III): Rats that underwent laparotomy surgery without varicocele induction received melatonin orally at 5 mg/kg for up to 4 weeks.[14]

VC-MEL (group IV): Rats in which varicocele is induced and receive melatonin orally at 5 mg/kg dosage for four weeks.[14]

Varicocele Induction

Varicocele was induced according to the Koksal surgical method.[16] Rats were anesthetized by intraperitoneal injection of 10% ketamine hydrochloride (60 mg/kg) and 2% xylazine hydrochloride (5 mg/kg). After preparing the surgical site, an incision was made in the midline of the abdomen. After finding the left renal vein and the entry point of the internal spermatic vein, the area around the left renal vein was slowly released. Then, an angiocath (20 Gauge x 1.88 inches) was placed parallel to the vein and tied with 0-4 silk thread on the left renal vein so that the knot could be located after the entrance

of the internal spermatic vein to the renal vein. After ligation, the angiocath was slowly removed, and the vein was allowed to return to normal. This work reduces the diameter of the left renal vein by about 50% and causes a unilateral varicocele (Figure 1). All treatments started one week after varicocele induction and continued for four weeks. After finishing the treatment phase, all rats were anesthetized using xylazine (2%, 10 mg/kg) and ketamine (10%, 40 mg/kg). The animals were first weighed, and then the left testes were isolated to assess BCL-2 gene expression and for histopathological evaluation. Blood samples were collected in tubes containing citrate anticoagulant to measure platelet indices using an automatic cell counter (Nihon Kohden). Additionally, blood samples were collected in simple tubes without anticoagulants to obtain serum and evaluate testosterone concentration.

Body and Testis Weight Measurement

Before induction of varicocele and laparotomy, BW1 was measured. On the last day of the experiment (after the experiments and the end of the treatment period), BW2 was measured. Then, the rats were anesthetized, the testis were removed, and the weight of the left testis was measured.

Assessment of BCL-2 Expression in Testis Tissues

The rats' testes were isolated, lysed, and homogenized following the manufacturer's instructions. The RNA extracted was utilized for cDNA synthesis through a reverse reaction using ferments. The cDNA was produced using a master mix, and specific primers were used to measure the mRNA levels of the BCL-2 anti-apoptotic protein through RT-PCR.

BCL-2 forward: “5'-TGCAGAGATGTCCAGTCAG-3'”,

BCL-2 reverse: “5'-GAACTCAAAGAAGGCCACAATC-3'”

The Glyceraldehyde 3-phosphate dehydrogenase (GAPDH) gene is considered a housekeeping gene and an internal control.

GAPDH forward: "5'-GCAGCTCCTTCGTTGCCGGT-3'";

GAPDH reverse: "5'- CCCGCCCATGGTGTCCGTTC-3'."

The expression ratio of the target gene to the housekeeping gene is estimated based on the $2^{-\Delta\Delta ct}$ method.

Assessment of Testosterone Serum Level

Blood samples were taken from the hearts of rats using a 5 ml syringe. The samples were then centrifuged in tubes with EDTA anticoagulant to measure platelet indices and in plain tubes without anticoagulant at 3000 rpm for 10 minutes. The serum was separated and stored in a -80 °C freezer for analysis of serum testosterone levels. Available kits (Demeditec Diagnostics kit, Germany) were used to measure serum testosterone concentration.

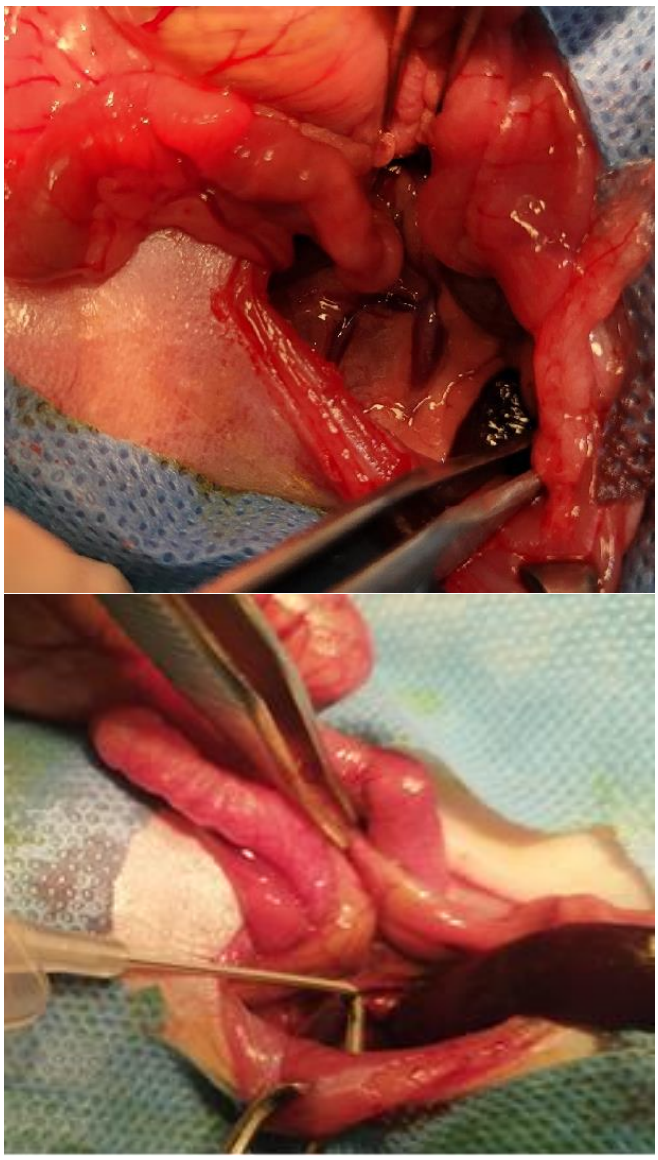

Figure. 1. Varicocele induction in rats.

Histopathology Assessment

The rat's testicular tissues were fixed in a 10% formalin solution. The tissues were then processed using a tissue processor, involving dehydration, cleaning, and impregnation. After preparation, the tissues were embedded in melted paraffin and cut into five-micron-thick sections using a microtome. Hematoxylin and eosin staining were used to color the cytoplasm purple and the tissue nuclei blue for microscopic examination. The severity of testicular damage was then evaluated using the Johnson grading system, which ranges from grade 1 to 10. Each tubular section was given a score from 1 to 10 based on the presence of cells. After 7 days of varicocele induction, the histopathology of the left and right testis was measured, and varicocele induction was confirmed.

Assessment of Platelet Indices

Blood samples collected in tubes containing citrate anticoagulant were used to evaluate platelet indices, including PLT, PCT, PDW, MPV, and the ratio of MPV to PLT.

Statistical Analysis

Statistical analysis was conducted using SPSS statistical software version 23 (SPSS Inc., Chicago, IL, USA). The data were presented as mean ± standard deviation (SD). Data with a normal distribution among groups were compared using the one-way ANOVA statistical test (and Tukey's *post hoc* test). In contrast, the Kruskal-Wallis statistical test (and Mann-Whitney U *post hoc* test) compared data with a non-normal distribution. p values less than 0.05 were considered to indicate statistically significant differences.

Results

Body and Testis Weight Measurement

The results of the present study showed that BW decreased in groups I (266.88 gr) and II (213.84 gr) after surgery. Melatonin compensated for this weight loss in groups III (290.66 gr) and IV (252.48 gr). The most statistical difference in BW1 and BW2 was observed in group II and the lowest in group III. However, no significant statistical difference was observed between the groups. Group II had the lowest TW (0.604 gr). Varicocele operation decreased the TW in group II, and melatonin use improved it. A significant statistical difference was observed between group II and other groups.

BCL-2 Gene Expression

Induction of varicocele decreased BCL-2 gene expression. The lowest amount of BCL-2 was observed in group II (0.102). As shown in the Table 1, the use of melatonin increased gene expression. A statistically significant difference was observed between group II and other groups (Table 1).

Testosterone Serum Level

Induction of varicocele decreased the amount of testosterone and melatonin could compensate for this decrease. The lowest amount of testosterone was observed in group II (0.87 ng/ml). The statistical difference between group II and other groups was significant ($p < 0.05$) (Table 1).

Histopathology

Microscopic evaluation of testicular sections demonstrated clear differences among the experimental groups (Figure 2). In the control group, the seminiferous tubules showed normal morphology with intact basement membranes and a well-organized germinal epithelium. The spermatogenic series was complete, with active spermatogenesis and the presence of mature spermatids in the lumen. Interstitial tissue and Leydig cells appeared normal without signs of degeneration or inflammation.

The VC group exhibited marked pathological alterations. Seminiferous tubules were irregular in outline and showed thinning and disorganization of the germinal epithelium. Vacuolization and sloughing of germ cells into the lumen were frequently observed. Many tubules displayed reduced spermatogenic layers and lacked mature spermatids. Interstitial edema and inflammatory cell infiltration were also apparent. The Johnsen's score was significantly reduced, indicating severe impairment of spermatogenesis.

In the VC-MEL group, melatonin treatment considerably improved testicular architecture compared with the VC group. Most seminiferous tubules demonstrated preserved morphology with partial to complete recovery of germinal epithelial thickness and better organization of spermatogenic layers. Vacuolization and germ cell depletion were reduced, and many tubules contained spermatids, reflecting restoration of spermatogenesis. Interstitial edema and inflammation were notably diminished. Johnsen's scores were significantly higher than those of the VC group, confirming the protective effect of melatonin.

The MEL group exhibited regular histological features, similar to those of the Control group. Seminiferous tubules appeared intact, with complete spermatogenesis and absence of degenerative or inflammatory changes, indicating that melatonin administration in healthy animals did not adversely affect testicular morphology.

Platelet Indices

The study found the highest levels of PDW in group II (18.4 %). There was a statistically significant difference in PDW between group II and group I ($p < 0.05$). Similarly, the highest levels of MPV were observed in group II (5.96 fL), with a significant statistical difference compared to groups I and III ($p < 0.05$). The highest levels of PCT were found in Group II (0.42 %). There was a statistically significant difference between Group II and the other groups examined ($p < 0.05$). Group I had the highest levels of PLT (241.004 $\times 10^3$/µl), with a statistically significant difference between them and Group II ($p < 0.05$). Group II had the highest MPV/PLT ratio (0.021), and the statistical difference between it and the other groups was significant ($p < 0.05$; Table 1).

Discussion

A varicocele is an abnormal enlargement of the veins above the testis. It is the primary correctable cause of male-factor infertility, present in 35–44% of men with primary infertility and 45–81% of men with secondary infertility.[17] Many studies have found different reasons for varicocele disease. Researchers have looked more at the main reasons for infertility in varicocele diseases, like

Table 1. Effects of Melatonin treatments on BCL-2 expression, platelet indices, and TE levels in experimental groups (Mean ± SD).

Parameter	Group I (n = 6)	Group II (n = 6)	Group III (n = 6)	Group IV (n = 6)
BCL-2	1.67 ± 0.28[a]	0.10 ± 0.12[b]	2.89 ± 0.30[a]	1.74 ± 0.06[a]
PLT (×10³/µL)	614.83 ± 241.00[a]	277.20 ± 41.75[b]	470.80 ± 162.62[ab]	463.00 ± 153.94[ab]
PCT (%)	0.16 ± 0.02[c]	0.42 ± 0.10[a]	0.21 ± 0.04[bc]	0.27 ± 0.04[b]
MPV (fL)	5.63 ± 0.28[b]	5.96 ± 0.18[a]	5.66 ± 0.18[b]	5.72 ± 0.16[ab]
PDW (%)	16.96 ± 1.28[b]	18.40 ± 0.58[a]	17.36 ± 0.85[ab]	17.76 ± 0.25[ab]
MPV/PLT	0.010 ± 0.003[b]	0.021 ± 0.003[a]	0.013 ± 0.003[b]	0.013 ± 0.004[b]
TE (ng/mL)	1.19 ± 1.05[a]	0.34 ± 0.08[b]	2.18 ± 1.58[a]	1.05 ± 0.88[a]

[a,b] Different superscript letters in the same row indicate statistically significant differences ($p < 0.05$).

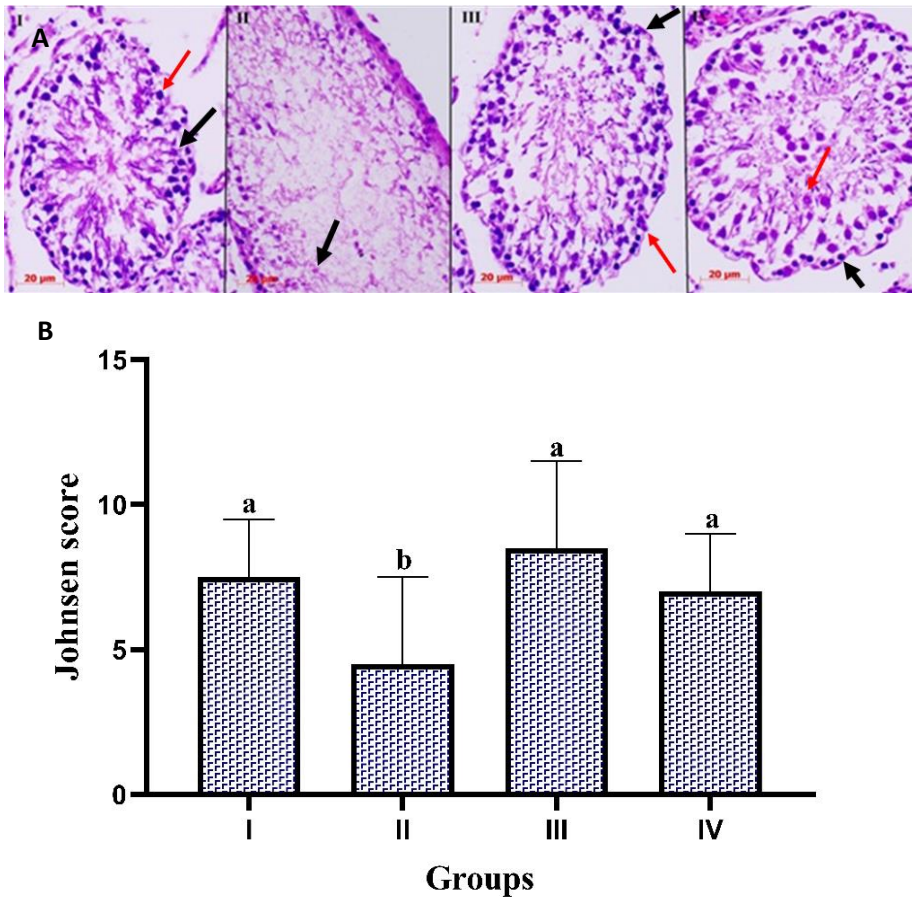

Figure 2. A) Comparison of seminiferous tubules of testicular histoplathology in studied groups. (I): Normal seminiferous tubules, sertoli (black arrow) and spermatogonia cells (red arrow), (II): Degenerated seminiferous tubules, primary spermatocyte cells (black arrow), (III): Seminiferous tubules, sertoli (black arrow) and spermatogonia cells (red arrow), (IV): Seminiferous tubules, spermatogonia (black arrow), primary spermatocyte cells (red arrow). B) Comparison of the pathology of the studied groups based on the Johnson grading system (6 rats each group). Group I: Control group: Rats that underwent laparotomy surgery without varicocele induction and received normal saline, Group II: VC group: Rats in which varicocele is induced and receive normal saline. Group III: MEL group: Rats that underwent laparotomy surgery without varicocele induction received melatonin orally at 5 mg/kg, Group IV: VC-MEL: Rats in which varicocele is induced and receive melatonin orally at 5 mg/kg.

apoptosis, hypoxia, hyperthermia, and OS.[18] Treatment with antioxidants as part of medical care may help decrease OS and cell death in cases of infertility caused by varicocele. The present study examines the protective effect of melatonin on BCL-2 gene expression, testosterone levels, testicular histopathology, and platelet indices in rats with varicocele.. The present study's results showed that in the varicocele group, BW2 decreased more than in other groups, and melatonin compensated for this weight loss. Previous studies have reported that varicocele causes weight loss in patients, consistent with the present study's results.[19] A study reported that the BW did not change significantly after two months of varicocele induction, but TW decreased.[20] Researchers have reported that melatonin improved the histopathological changes in the testes and TW, which is consistent with the results of the present study.[21] In another study, it was reported that although melatonin improved spermatogenesis and sperm quality parameters, it did not have a significant effect on TW, which is inconsistent with the results of the present study.[22] A reduction in the size of the testes may indicate

potential damage caused by brief episodes of increased temperature in the testis, impacting the production of sperm in individuals with subclinical varicocele.[23] Exogenous melatonin can help reduce testicular damage from prolonged exposure to light. Previous studies have demonstrated that prolonged exposure to light reduces the gonadal index and sperm count in rats.Melatonin can improve TW and testosterone levels in male rats with reproductive decline.[24] It was reported that apoptosis, also known as programmed cell death, significantly contributes to the pathophysiology of varicocele. Individuals with varicocele experience increased levels of apoptosis in developing germ cells, testis tissues, and ejaculated spermatozoa.[23] Excess ROS and also genetic mechanisms can promote apoptosis.[25] The processes associated with varicocele, including heat stress, excess ROS, and increased apoptosis, are interconnected. Heat stress leads to higher levels of ROS and OS, which can trigger apoptosis. It is supported by the connection between varicocele and reduced expression of heat-shock proteins, as well as more significant variations in glutathione S-transferase and nitric oxide (NO) synthase genes, increased BAX and protein levels, and decreased BCL-2 gene and protein levels..[23] Regarding the mechanism of changes in BCl-2 family proteins due to varicocele, it is likely that an increase in ROS production leads to an imbalance between the anti-apoptotic BCL-2 proteins and the pro-apoptotic BAX proteins, which contributes to the cell's sensitivity to apoptosis. In explaining this relationship, findings indicate that varicocele causes changes in testis hemodynamics and the cellular microenvironment. As a result, ROS increases, and antioxidant capacity decreases.[25] The increased OS caused by the varicocele may lead to increased Bax expression and decreased BCL-2 expression, leading to cell death, as the current study supports. Melatonin possesses antioxidant properties. It has been reported that melatonin increases the expression of apoptotic genes such as BAX, BCL-2, Fas, and P53. Melatonin can reduce apoptosis induced by physiological and pathological processes.[26] It has been reported that melatonin inhibits apoptosis primarily by reducing the level of p-AKT and increasing the expression of BCL-2.[27] These results are consistent with those of the present study regarding the decrease in BCL-2 gene expression level due to varicocele induction and the compensation of this decrease with melatonin. A survey on the effect of minocycline on reducing testicular apoptosis in varicocele patients, it was reported that BCL-2 gene expression was decreased in these patients, and treatment with minocycline compensated for this decrease.[28] A study investigating the effect of melatonin on the gonads of dairy goats found that melatonin increased testosterone levels in response to heat stress inhibition.[27] Testosterone levels have been reported to decrease in patients with varicocele.[29] The harmful effects of varicocele have negatively affected spermatogenesis, Leydig cell function, and testosterone levels.[5] It has been reported that there is a significant relationship between the protective effect of melatonin on spermatogenic cells and its modulating effect on testosterone.[27] Research has demonstrated that melatonin directly controls testosterone production by binding to specific receptors.[30] Melatonin treatment improved Leydig cells' function, increasing testosterone levels in the blood and the testis. This decrease in testosterone levels also led to lower levels of the hormones FSH and LH. Melatonin not only directly regulates testosterone production but also controls the secretion of LH and gonadotropin-releasing hormone (GnRH).[31] Melatonin protects the testis from inflammatory processes and ROS production and reduces the severity of testicular damage due to varicocele.[32] It was reported that the testicular parenchyma's diffusion coefficient in varicocele patients was lower than that in healthy subjects. The authors proposed that the ischemic and fibrotic processes in varicocele patients were related to this decrease.[33] In varicocele rats, the mRNA levels of the proinflammatory cytokines tumor necrosis factor-alpha (TNF-α), CD45, CD3g, and CD3d can increase, leading to changes in the permeability of the blood-testis and immunological barriers typically found in normal testes.[34] During testicular development, melatonin helps Sertoli cells respond better to FSH and influences various testicular cell types' growth, proliferation, and secretory activity.[35] Melatonin modulates inflammatory and oxidant/antioxidant status in testicular pathology, affecting testicular function and male reproduction.[36] In the histological evaluation of the testicular tissue of varicocele patients, it was reported that the varicocele caused severe damage to the testicular tissue, and treatment with minocycline improved the testicular tissue.[28] There is evidence for the involvement of ROS and NO as mediators of testicular damage. Severe varicocele causes severe histopathological changes in the testis, reducing antioxidant levels and increasing malondialdehyde and NO levels.[37] Melatonin has two important roles: it helps protect normal tissue by neutralizing harmful superoxide ions and inhibiting NO production. In the present study, melatonin improved the damage caused by varicocele to testicular tissue, consistent with the results of previous studies. Melatonin makes Sertoli cells more responsive to FSH during testicular development. It also regulates the growth, reproduction, and secretion of various testicular cells.Melatonin also helps protect the testis from local inflammation and the production of ROS. Melatonin treatment has been reported to reduce testis tissue damage in animal models with conditions such as

hyperlipidemia, testicular torsion, and varicocele.[38] Melatonin affects cells by binding to specific receptors on plasma membranes and activating certain signaling pathways, including redox pathways.[39] Melatonin and its byproducts are expected to affect levels of ROS and provide protection for the mitochondria by activating essential signaling pathways such as stress-activated/mitogen-activated protein kinases. These specialized proteins control most of the activities in eukaryotic cells by relaying signals from the cell surface to the nucleus.[40] Varicocele is a vascular disorder that can lead to local and systemic inflammation. It might be caused by an inflammatory incident that has a detrimental effect on spermatogenesis, although the exact pathophysiology of varicocele-induced harm is not fully understood. Researchers investigated whether varicocele is associated with higher levels of inflammatory markers to understand the role of inflammation in the development of varicocele.. Platelets vary in size and density within an individual.[41] Platelet volume indices can be affected by various factors, including a history of coronary artery disease, high blood pressure, hyperlipidemia, peripheral vascular disease, diabetes mellitus, splenectomy, thrombocytopenia, and leukemia.[42] The MPV is one of the reliable laboratory indicators of inflammation status, and it was significantly higher in subfertile patients with varicocele compared to fertile men.[23] It was reported that MPV is a widely accepted measurement for platelet count. An increase in varicocele patients has been observed, and a decrease after surgical correction of the condition. It has been reported that an increase in the level of MPV is associated with the degree of varicocele. As the degree of varicocele increases, the amount of MPV also increases.[43] One study found that PDW levels were higher in varicocele patients. PDW can be used to confirm a varicocele diagnosis and follow up after varicocelectomy, which is consistent with this study. A low PLT level may indicate increased blood clotting and platelet activity in cardiovascular diseases, as it can lead to elevated levels of glycoprotein VI and inflammatory markers. The present study showed that PLT in the varicocele group without treatment was lower than in other groups, consistent with previous studies' results.[44] An elevated MPV/PLT ratio often suggests decreased PLT and increased MPV due to the inverse relationship between the two. MPV/PLT ratio rises in patients with varicocele. Unlike PLT, other indices, such as PCT, MPV, PDW, and MPV/PLT ratios, significantly increased in rats. These indicators are suitable for diagnosing and monitoring varicocele, and this discovery aligns with the current study's findings.[44] Based on these studies, the change in platelet indices of varicocele patients results from inflammation, consistent with previous studies.[41] When platelets are more active, the body produces specific cytokines, such as interleukin-6 (IL-6) and C-reactive protein (CRP). This happens when MPV levels are higher. It was reported that a significant association exists between platelet gene expression and circulating inflammatory biomarkers, such as C-reactive protein and IL-6, particularly in individuals with obesity and cardiovascular disease.[45] An inflammatory event may have caused a varicocele, leading to local or systemic inflammation. The increased MPV levels in varicocele patients are likely due to inflammation. This low-grade inflammation may be the underlying mechanism for the elevated MPV levels.[41] In conclusion, high MVP levels may cause local and systemic inflammation or endothelial dysfunction. It could ultimately impact the development of varicocele by prompting the release of specific cytokines. There is evidence linking testicular aging and idiopathic male infertility with inflammatory events and local OS. On the other hand, melatonin, with its anti-inflammatory and antioxidant properties, focuses on improving male fertility and aging.[46] It was reported that melatonin has a significant anti-inflammatory effect on IL-1, IL-6, and IL-8.[47] Researchers have suggested that exogenous melatonin can lower levels of inflammatory markers, which could help prevent and treat inflammatory disorders. Melatonin is considered safe and has few side effects, making it an excellent option for this purpose.[48] Melatonin has additional anti-inflammatory effects, likely linked to a direct interaction with specific binding sites found in lymphocytes and macrophages.[49] In the present study, melatonin improved the platelet indices that were changed due to the inflammation caused by the varicocele, which seems to have improved through the reduction of inflammatory cytokines.

In conclusion, the present study investigated the effects of melatonin on testosterone hormone levels, testis histopathology, expression of the BCL-2 gene, and platelet indices in an experimental varicocele rat model.

The results demonstrated that melatonin increased serum testosterone levels, upregulated BCL-2 expression, improved testicular histology, and normalized platelet indices in rats with induced varicocele. These findings indicate that melatonin exerts a protective effect against varicocele-associated testicular alterations. However, the precise mechanisms underlying these effects were not specifically evaluated in this study and warrant further investigation.

Acknowledgment

The authors thank all participants for their cooperation and sample contribution. This research was supported by Semnan University, Semnan, Iran.

Conflict of Interest

The authors declare no conflict of interest.

References

1. Wang K, Gao Y, Wang C, Liang, M, Liao Y, Hu K. Role of oxidative stress in varicocele. *Frontiers in Genetics*. 2022; 13: 850114. doi: 10.3389/fgene.2022.850114
2. Talebi-Yazdabadi Z, Jahanbakhsh N, Dormiani K, Forouzanfar M, Lachinani L, Zohrabi D, Tavalaee M, Nasr-Esfahani MH. Assessment of MUSASHI 1 and MUSASHI 2 expression in spermatozoa and testicular tissue. *Andrologia*. 2021; 53(10): e14187. doi: 10.1111/and.14187
3. Almeida C, Correia S, Rocha E, Alves A, Ferraz L, Silva J, Sousa M, Barros A. Caspase signalling pathways in human spermatogenesis. *Journal of Assisted Reproduction and Genetics*. 2013; 30: 487-495. doi: 10.1007/s10815-013-9938-8
4. Chen H, Lam Fok K, Jiang X, Chan HC. New insights into germ cell migration and survival/apoptosis in spermatogenesis: lessons from CD147. *Spermatogenesis*. 2012; 2(4): 264-272. doi: 10.4161/spmg.22014
5. Besiroglu H, Otunctemur A, Dursun M, Ozbek E. The prevalence and severity of varicocele in adult population over the age of forty years old: a cross-sectional study. *Aging Male*. 2019; 22(3): 207-213. doi: 10.1080/13685538.2018.1465913
6. Gürdal M, Kireççi S, Huri E, Karaman I, Türkeri L. Correlation between duration of varicocele and apoptosis in testicular tissue in an experimental model. *Urology*. 2008; 72(4): 933-936. doi: 10.1016/j.urology.2008.01.060
7. Kang C, Punjani N, Lee RK, Li PS, Goldstein M. Effect of varicoceles on spermatogenesis. *Seminars in Cell Developmental Biology*. 2022; 121: 114-124. doi: 10.1016/j.semcdb.2021.04.005
8. Xia W, Li Y, Wang B, Chen J, Wang X, Sun Q, Sun F, Li Z, Zhao Z. Enhanced store-operated calcium entry in platelets is associated with peripheral artery disease in type 2 diabetes. Cellular *Physiology and Biochemistry*. 2015; 37(5): 1945-1955. doi: 10.1159/000438555
9. Pyo JS, Cho WJ. Mean platelet volume, platelet distribution width, and platelet count in varicocele: a systematic review and meta-analysis. *Cellular Physiology and Biochemistry*. 2016; 38(6): 2239-2246. doi: 10.1159/000445579
10. Läubli H, Varki A. Sialic acid–binding immunoglobulin-like lectins (Siglecs) detect self-associated molecular patterns to regulate immune responses. *Cellular and Molecular Life Sciences*. 2020; 77(4): 593-605. doi: 10.1007/s00018-019-03288-x
11. Gurunathan S, Qasim M, Kang MH, Kim, J-H. Role and therapeutic potential of melatonin in various type of cancers. *Onco Targets and Therapy*. 2021; 18(14): 2019-2052. doi: 10.2147/OTT.S298512
12. Reiter RJ, Mayo JC, Tan DX, Sainz RM, Alatorre-Jimenez M, Qin L. Melatonin as an antioxidant: under promises but over delivers. *Journal of Pineal Research*. 2016; 61(3): 253-278. doi: 10.1111/jpi.12360
13. Pourhanifeh MH, Mehrzadi S, Kamali M, Hosseinzadeh A. Melatonin and gastrointestinal cancers: Current evidence based on underlying signaling pathways. *European Journal of Pharmacology.* 2020; 5(886): 173471. doi: 10.1016/j.ejphar.2020.173471
14. Abo El Gheit RE, Soliman NA, Nagla SA, El-Sayed RM, Badawi GA, Emam MN, Abdel Ghafar MT, Elswaidy NRM, Radwan DA, Alshenawy HA, Khaled HE, Kamel S, El-Saka MH, Madi NM, Younis RL . Melatonin epigenetic potential on testicular functions and fertility profile in varicocele rat model is mediated by silent information regulator 1. *British Journal of Pharmacology*. 2022; 179(13): 3363-3381. doi: 10.1111/bph.15804
15. Bonnefont-Rousselot D, Collin F. Melatonin: action as antioxidant and potential applications in human disease and aging. *Toxicology*. 2010; 278(1): 55-67. doi: 10.1016/j.tox.2010.04.008
16. Koksal T, Erdogru T, Toptas B, Gülkesen KH, Usta M, Baykal A, Baykara M. Effect of experimental varicocele in rats on testicular oxidative stress status. *Andrologia*. 2002; 34(4): 242-247. doi: 10.1046/j.1439-0272.2002.00500.x
17. Jensen CFS, Østergren P, Dupree JM, Ohl DA, Sønksen J, Fode M. Varicocele and male infertility. *Nature Reviews Urology*. 2017; 14(9) 523-533. doi: 10.1038/nrurol.2017.98
18. Munoz-Lopez C, Wong A, Lewis K, Bole R, Vij SC, Lundy SD. The evolving landscape of male varicocele pathophysiology in the era of multi-omics: a narrative review of the current literature. *Biology*. 2024; 13(2): 80. doi: 10.3390/biology13020080
19. Gorur S, Candan Y, Helli A, Akcin S, Cekirge SD, Kaya YS, Cekic C, Kiper AN. Low body mass index might be a predisposing factor for varicocele recurrence: a prospective study. *Andrologia*. 2015; 47(4): 448-454. doi: 10.1111/and.12287
20. Babaei A, Asadpour R, Mansouri K, Sabrivand A, Kazemi-Darabadi S. Lycopene improves testicular damage and sperm quality in experimentally induced varicocele: Relationship with apoptosis, hypoxia, and hyperthermia. *Food Science and Nutrition*. 2022; 10(5): 1469-1480. doi: 10.1002/fsn3.2762
21. Dehdari Ebrahimi N, Shojaei-Zarghani S, Taherifard E, Dastghaib S, Parsa S, Mohammadi N, Sabet Sarvestani F, Moayedfard Z, Hosseini N, Safarpour H, Sadeghi A, Azarpira N, Safarpour AR. Protective effects of melatonin against physical injuries to testicular tissue: A systematic review and meta-analysis of animal models. *Frontiers in Endocrinology*. 2023; 14: 1123999. doi: 10.3389/fendo.2023.1123999
22. Moradi M, Goodarzi N, Faramarzi A, Cheraghi H, Hashemian AH, Jalili C. Melatonin protects rats testes against bleomycin, etoposide, and cisplatin-induced toxicity via mitigating nitro-oxidative stress and apoptosis. *Biomedicine and Pharmacotherapy*. 2021; 138: 111481. doi: 10.1016/j.biopha.2021.111481
23. Hassanin AM, Ahmed HH, Kaddah AN. A global view of the pathophysiology of varicocele. *Andrology*. 2018; 6(5): 654-661. doi: 10.1111/andr.12511
24. Muratoğlu S, Akarca Dizakar OS, Keskin Aktan A, Ömeroğlu S, Akbulut KG. The protective role of melatonin and curcumin in the testis of young and aged rats. *Andrologia*. 2019; 51(3): e13203. doi: 10.1111/and.13203
25. Cho CL, Esteves SC, Agarwal A. Novel insights into the pathophysiology of varicocele and its association with reactive oxygen species and sperm DNA fragmentation. Asian Journal of *Andrology*. 2016; 18(2): 186-193. doi: 10.4103/1008-682X.170441
26. Asadi E, Jahanshahi M, Golalipour MJ. Effect of vitamin E on oocytes apoptosis in nicotine-treated mice. *Iranian Journal of Basic Medical Sciences*. 2012; 15(3): 880. doi: 10.22038/ijbms.2012.4873
27. Liu Y, Cai H, Guo X, Aierken A, Hua J, Ma B, Peng S. Melatonin alleviates heat stress-induced testicular damage in dairy goats by inhibiting the PI3K/AKT signaling pathway. *Stress Biology*. 2022; 2(1): 47. doi: 10.1007/s44154-022-00068-9
28. Shokoohi M, Khaki A, Roudi Rasht Abadi A, MohammadZadeh Boukani L, Hassanpour Khodaie S, KalarestaghiH, Khaki AF, Moghimian M, Niazkar HR, Shoorei H. Minocycline can reduce testicular apoptosis related to varicocele in male rats. *Andrologia*. 2022; 54(4): e14375. doi: 10.1111/and.14375
29. Bernstein AP, Najari BB. Varicocele treatment and serum testosterone. *Androgens Clinical Research and Therapeutics.* 2022; 3(1): 133-137. doi:10.1089/andro.2021.0028
30. Frungieri MB, Mayerhofer A, Zitta K, Pignataro OP, Calandra RS, Gonzalez-Calvar SI. Direct effect of melatonin on Syrian

hamster testes: melatonin subtype 1a receptors, inhibition of androgen production, and interaction with the local corticotropin-releasing hormone system. *Endocrinology*. 2005; 146(3): 1541-1552. doi: 10.1210/en.2004-0990
31. Lu XL, Liu JJ, Li JT, Yang QA, Zhang JM. Melatonin therapy adds extra benefit to varicecelectomy in terms of sperm parameters, hormonal profile and total antioxidant capacity: A placebo-controlled, double-blind trial. *Andrologia*. 2018; 50(6): e13033. doi: 10.1111/and.13033
32. Zhang K, Lv Z, Jia X, Huang D. Melatonin prevents testicular damage in hyperlipidaemic mice. *Andrologia*. 2012; 44(4): 230-236. doi: 10.1111/j.1439-0272.2012.01272.x
33. Karakas E, Karakas O, Cullu N. Badem OF, Boyac FN, Gulum M, Cece H. Diffusion-weighted MRI of the testes in patients with varicocele: a preliminary study. *American Journal of Roentgenology*. 2014; 202(2): 324-328. doi: 10.2214/AJR.13.10594
34. Oh YS, Jo NH, Park JK, Gye MC. Changes in inflammatory cytokines accompany deregulation of claudin-11, resulting in inter-sertoli tight junctions in varicocele rat testes. *Journal of Urology*. 2016; 196(4): 1303-1312. doi: 10.1016/j.juro.2016.05.004
35. Rossi SP, Windschuettl S, Matzkin ME, Terradas C, Ponzio R, Puigdomenech E, Levalle O, Calandra RS, Mayerhofer A, Frungieri MB. Melatonin in testes of infertile men: evidence for anti-proliferative and anti-oxidant effects on local macrophage and mast cell populations. *Andrology*. 2014; 2(3): 436-449. doi: 10.1111/j.2047-2927.2014.00207.x
36. Frungieri MB, Calandra RS, Rossi SP. Local actions of melatonin in somatic cells of the testis. *International Journal of Molecular Sciences.* 2017; 18(6): 1170. doi: 10.3390/ijms18061170
37. Semercioz A, Onur R, Ogras S, Orhan I. Effects of melatonin on testicular tissue nitric oxide level and antioxidant enzyme activities in experimentally induced left varicocele. *Neuro Endocrinology Letters*. 2003; 24(1/2): 86-90.
38. Lee KM, Lee IC, Kim SH, Moon C, Park SH, Shin DH, Kim SH, Park SC, Kim HC, Kim JC. Melatonin attenuates doxorubicin-induced testicular toxicity in rats. *Andrologia* 2012; 44: 796-803.
39. Tan DX, Manchester LC, Terron MP, Flores LJ, Tamura H, Reiter RJ. Melatonin as a naturally occurring co-substrate of quinone reductase-2, the putative MT3 melatonin membrane receptor: hypothesis and significance. *Journal of Pineal Research*. 2007; 43(4): 317-320. doi: 10.1111/j.1600-079X.2007.00513.x
40. McCubrey JA, LaHair MM, Franklin RA. Reactive oxygen species-induced activation of the MAP kinase signaling pathways. *Antioxidants and Redox Signaling*. 2006; 8(9-10): 1775-1789. doi: 10.1089/ars.2006.8.1775
41. Demirer Z, Karademir I, Uslu AU, Güragac A, Aksu Y. The relationship between inflammation and mean platelet volume in varicocele pathophysiology. *Revista International de Andrologia*. 2018; 16(4): 137-142. doi: 10.1016/j.androl.2017.06.005
42. Leader A, Pereg D, Lishner M. Are platelet volume indices of clinical use? A multidisciplinary review. *Annals of Medicine*. 2012; 44(8): 805-816. doi: 10.3109/07853890.2011.653391
43. Bozkurt Y, Soylemez H, Sancaktutar AA, Islamoglu Y, Kar A, Penbegul N, Atar M, Nuri Bodakci M, Hatipoglu NK. Relationship between mean platelet volume and varicocele: a preliminary study. *Urology*. 2012; 79(5): 1048-1051. doi: 10.1016/j.urology.2012.01.019
44. Noori Alavije H, Ahmadi-hamedani M, Moslemi H. Evaluation of platelet indices and mean platelet volume to platelet count ratio in experimentally varicocele-induced adolescent and adult rats. *Andrologia*. 2022; 54(3): e14345. doi: 10.1111/and.14345
45. McManus DD, Beaulieu LM, Mick E, Tanriverdi K, Larson MG, Keaney Jr GF, Benjamin EJ, Freedman JE. Relationship among circulating inflammatory proteins, platelet gene expression, and cardiovascular risk. Arteriosclerosis, *Thrombosis, and Vascular Biology*. 2013; 33(11): 2666-2673. doi: 10.1161/ATVBAHA.112.301112
46. Frungieri MB, Calandra RS, Matzkin ME, Rossi SP. Melatonin as a natural anti-inflammatory and anti-oxidant therapy in the testis: a focus on infertility and aging. *Biology of Reproduction*. 2024; 111(3): 543-556. doi: 10.1093/biolre/ioae087
47. Zlowodzki M, Poolman RW, Kerkhoffs GM, Tornetta P, Bhandari M. How to interpret a meta-analysis and judge its value as a guide for clinical practice. *Acta Orthopedica*. 2007; 78(5): 598-609. doi: 10.1080/17453670710014284
48. Cho JH, Bhutani S, Kim CH, Irwin MR. Anti-inflammatory effects of melatonin: a systematic review and meta-analysis of clinical trials. *Brain, Behavior and Immunity*. 2021; 93: 245-253. doi: 10.1016/j.bbi.2021.01.034
49. Pajović SB, Saićić ZS, Spasić MB, Petrović VM. The effect of ovarian hormones on antioxidant enzyme activities in the brain of male rats. *Physiological Research*. 2003; 52(2): 189-194.