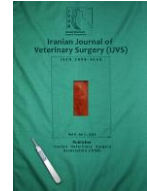



Iranian Veterinary Surgery Association

IRANIAN JOURNAL OF VETERINARY SURGERY

Journal homepage: www.ivsajournals.com

ORIGINAL ARTICLE

Topical Application of *Lactobacillus Plantarum* on Burn Wound Healing in Diabetic Rats

Masoud Salaran¹, Ahmad Oryan^{2,*}, Behrooz Nikahval¹, Amir Kamali², Mehran Ghaemi³,
Fatemeh Abbasi-Teshnizi⁴, Mohammad Azizzadeh⁵

¹ Department of Clinical Studies, School of Veterinary Medicine, Shiraz University, Shiraz, Iran.

² Department of Pathology, School of Veterinary Medicine, Shiraz University, Shiraz, Iran.

³ Department of Biotechnology, School of Veterinary Medicine, Shiraz University, Shiraz, Iran.

⁴ Department of Biochemistry, School of Veterinary Medicine, Shiraz University, Shiraz, Iran.

⁵ Department of Clinical Science, Faculty of Veterinary Medicine, Ferdowsi University of Mashhad, Mashhad, Iran.

Received: 10 February
2019

Accepted: 20 April 2019

Available Online: 20 April
2019

Keywords:

Wound Healing, Diabetes;
Burn;
Lactobacillus plantarum;
Transforming growth
factor-beta1 (TGF-β1).

Abstract

Objective- This study was designed to investigate the effect of *Lactobacillus plantarum* gel on cutaneous burn wound healing in diabetic rats.

Design- Randomized experimental study

Animals- Forty adult male rats

Procedures- Two circular 1 cm cutaneous wounds were created in the dorsum back of each rat. 48 h post-burning, debridement with a 1 cm biopsy punch was performed. The wounds were divided into the following four treatment groups (n= 10, each): 1. Untreated or negative control (NC), 2. silver sulfadiazine (positive control-SSD), 3. base gel (BG) 4. *Lactobacillus plantarum* Gel (LP gel). The wound surface area and epithelialization were monitored. The animals were euthanized at 10 (n = 5), and 20 (n = 5) days post-injury (DPI) and the skin samples were used for histopathological, biochemical, TGF-β gene expression and biomechanical investigations.

Results- It was indicated that the *L. plantarum* and SSD treated lesions had the lowest percentage of wound size and collagen content and also the *L. plantarum* treated group showed shortest inflammatory period and highest amount of TGF-β at 10 days post injury. The *L. plantarum* gel treated lesions also demonstrated greater ultimate load compared to the untreated and based gel treated wounds.

Conclusions and Clinical Relevance- In conclusion, *L. plantarum* gel therapy improved wound healing and resulted in better outcomes after severe burn injury in diabetic rats compared with the silver sulfadiazine treatment.

* Correspondence to: Ahmad Oryan, Department of Pathology, School of Veterinary Medicine, Shiraz University, Shiraz, Iran.

E-mail: oryan@shirazu.ac.ir

www.ivsajournals.com© Iranian Journal of Veterinary Surgery, 2019

This work is licensed under the terms of the Creative Commons Attribution (CC BY-NC 4.0)

DOI: 10.22034/ivsa.2019.171577.1173

1. Introduction

Wound healing is a process in skin or other organs that occurs after injury.^{1,2} It is a body's natural process of regenerating dermal and epidermal tissue in skin and is a complex process involving inflammation, cellular proliferation, and tissue remodeling which is regulated by a cascade of inflammatory mediators, including cytokines and growth factors. Scientists are still interested in wound healing, especially with regard to factors that delay or hinder this process.³ A fibrous scar with collagen is the end product of this process. Collagen provides strength and integrity to dermis.⁴ Although numerous growth factors are involved in the process of wound healing, transforming growth factor-beta (TGF- β) exerts the greatest fibrogenic effect during repair.³ Complications may happen in the wound healing process in patients with underlying metabolic disorders. As an instant, in both experimental and clinical diabetes disease, complications such as compromises in cellular migration, vascular proliferation, and extracellular matrix remodeling make negative impact on tensile strength and wound healing process.⁵

Diabetes mellitus is a chronic metabolic disease. In diabetes hyperglycemia due to impaired secretion and/or action of insulin, and disturbances in carbohydrate, fat and protein metabolism may occur.⁶ In diabetic patients poor wound healing is a common complication, but the mechanisms underlying impaired healing is not completely understood.^{7,8} One of the reasons of delayed healing is connective tissue abnormalities. In diabetes, as a result of reduced synthesis and enhanced degradation of collagen the collagen content is reduced and this may be one of the abnormalities contributed to poor wound healing seen in diabetes.⁹ Treatment of chronic wounds in diabetes has remained a challenging clinical problem.¹⁰

Burn is characterized by a hypermetabolic state which compromises the immune system leading to chronic wound healing. Thermal exposure to the body surface causes damage to the skin by membrane destabilization, protein coagulation, associated energy depletion and hypoxia at the cellular level which leads to extensive tissue necrosis.⁶ In burn patients, diabetes may have implications for length of hospitalization, hospital course, number of surgical procedures, and burn outcome.¹¹ Silver sulfadiazine (SSD) is the gold standard therapy in topical burn treatment,¹² but due to its adverse effects, bacterial resistance and its ineffectiveness on the healing process, scientists are still searching for alternative compounds that can enhance the wound healing process.¹³⁻¹⁵

Probiotics are either a single strain or a mixture of different organisms and have the ability to strengthen the immune

system, produce anti-inflammatory action and enhance the wound healing process following accumulation of inflammatory cells like polymorphonuclear cells, macrophages, lymphocytes and plasma cells in the wound bed.¹⁶ In new ways, for treating wounds, probiotics can eliminate pathogenic microbes and improve wound healing. Probiotics have also anti-infective properties and can also promote wound healing, hence they have potency to inhibit infection.¹⁷ *L. plantarum* is a probiotic organism producing lactic acid, this product has antibacterial properties that can inhibit the proliferation of pathogenic microorganisms. *L. plantarum* is a commensal microorganism that does not produce virulence factors and succumbs easily to the antimicrobial battery of host defenses, particularly the polymorphonuclear cell activity, and for these properties, the effects of *L. plantarum* gel was tested on cutaneous wound healing in the burn induced injury in diabetic rats.¹⁸

2. Materials and Methods

All the procedures were conducted in accordance with the Iranian community guidelines for laboratory animals and the principles of laboratory animal care (NIH publication NO. 86-23, revised 1985) was followed. This experiment was approved by the local Ethics Committee of "Regulations for using animals in scientific procedures" in School of Veterinary Medicine of our University.

L. Plantarum and gel preparation

Lactobacillus plantarum was grown in MRS broth at 37 °C for 24 h in an incubator. The gel was formulated by adding 2% carboxy methyl cellulose (CMC) in medium with *Lactobacillus plantarum* (1×10^9 CFU/ml). The solution was stirred at room temperature for 2 h.¹⁹

Experimental animals

Forty mature male Sprague-Dawley rats, weighing 200-250 g were housed in individual cages with controlled light, temperature and humidity. The rats were fed commercial rat food and water ad libitum.

Induction of diabetes mellitus in rats

Diabetes was induced after an overnight fasting, using one single shot intraperitoneal injection of 65 mg/kg streptozotocin (STZ) (Sigma, St. Louis, MO), a toxin specific for insulin-producing cells, in saline-sodium citrate buffer. The blood glucose level was measured, using

an acute glucometer (Johnson & Johnson Co., USA). 21 days after STZ injection, the animals with blood glucose level above 300 mg/dl were defined as diabetic and entered in the study.²⁰

Skin burn wound model

The animals were positioned in sternal recumbency and generally anesthetized by intramuscular (IM) injection of ketamine (Ketamin hydrochloride, Alfasan, Woerden Holland, Netherlands, 40 mg/kg) and xylazine (Xylazine hydrochloride, Alfasan, Woerden Holland, Netherlands, 5 mg/kg). The dorsum was then shaved and sterilized with povidone-iodine solution. A template was used to standardize the location and distance of the burn wounds. A standard iron bar, 1 cm in diameter, was maintained at a temperature of 100 °C and applied for 15 seconds to create second degree burns wounds. The rats were placed in an isolated cage to inhibit transmission of infection. The wounds were examined after 24 h and for debridement of necrotic tissue two full-thickness excisional wounds (10 mm in diameter, Figure 1A) were created under aseptic conditions in the back of each rat, using a biopsy punch.

Treatment design

The animals were randomly divided into the following groups (n=10, each):

- Group 1: Diabetic animals received no treatment (NC)
- Group 2: Diabetic animals received silver sulfadiazine (SSD) twice a day for 14 days
- Group 3: Diabetic animals received base gel (BG) twice a day for 14 days
- Group 4: Diabetic animals received *L. plantarum* gel (LP) twice a day for 14 days

Tissue sampling

The rats were euthanized at 10 (n=5) and 20 (n=5) days post-injury (DPI). The right side wounds were collected for histological investigation and hydroxyproline content estimation and mRNA TGF- β expression. Tissue sections were collected from the center of the lesions to a rim of normal skin surrounding the wound. Moreover, the left wounds were carefully dissected for biomechanical testing (Figure 1 A).

Gross Morphology of the Wounds

The wound area was observed and photographed at 10 and 20 DPI. The images were transferred to Image Pro Plus

software[®] V.6 (Media Cybernetics, Inc., Silver Spring, USA) for morphometric analysis including measurement of the wound surface area at these time points (Figure 1A).

Histopathologic and histomorphometric analysis

Five animals from each group were euthanized at 10 and five other at 20 days post-treatment and the skin tissues were harvested and immediately fixed in 10% neutral buffered formalin (pH=7.26) for 48 h. The fixed tissue samples were then processed, embedded in paraffin, and sectioned to 5 μ m thickness. Finally, the sections were stained with hematoxylin and eosin (H&E). The histological sections were evaluated by two independent pathologists, using light microscopy (Olympus BX51; Olympus, Tokyo, Japan) in a double-blind fashion. Epithelialization, inflammatory cell infiltration, fibroplasia and granulation tissue formation were assessed in different groups, comparatively. Magnification \times 400 was employed to count different cells and calculation was repeated in five fields for each tissue section. Finally, the average number of each criterion for these fields was then recorded. Epithelialization was assessed, on 10 and 20 DPI, semi-quantitatively on 5-point scores: 0 (without new epithelialization), 1 (25%), 2 (50%), 3 (75%), and 4 (100%) epithelialization.²¹ For these parameters, the results were validated by comparative analysis of two independent observers blinded to the treatment groups.

Tensile testing

After shaving, the skin samples containing the burned area were excised in a rectangular shape (10 \times 2 cm). The samples were kept frozen (-20 °C) until the time of testing. Prior to testing the samples were then thawed at room temperature. A Universal Instron testing machine was used for tensile testing of the specimens (TT-CM-L, United Kingdom). The skin samples were mounted on tensiometer holders, where both sides of the skin strip were clamped into a pair of holders so that a constant length of 4 cm, with the wound in the middle of the strip, was used for tensile testing. The skin strip was stretched, using a constant strain rate of 10 mm/min and the ultimate tensile strength was calculated based on the created load-deformation curve.²²

Hydroxyproline content

After thawing, the samples were dried in a hot air oven at 60-70° C until a constant weight was achieved. The samples were then hydrolyzed with 6 N HCL for 2 hours at

120° C. The hydrolyzed samples were adjusted to pH=7 and subjected to chloramines T oxidation, and finally, the colored adduct formed with the aldehyde perchloric acid reagent at 60° C, was read at 550 nm after cooling for 5 min. A modified assay to determine hydroxyproline content in a tissue hydrolizate was used.²³

Real-time RT-PCR

The mRNA expression of TGF- β were determined by real-time RT-PCR. RNA was isolated from wound tissues using High Pure RNA Isolation Kit (Roche, Germany) and cDNA was synthesized using Transcriptor First Strand cDNA Synthesis kit (Roche, Germany) according to the manufacturer's instruction. CDNA was used as a template for the subsequent real time RT-PCR. The real time PCR assay was performed, using Light Cycler 480 SYBR Green I Master (Roche, Germany) in the LightCycler 480 real time PCR system (Roche, USA). The real time RT-PCR experiment was carried out according to the manufacturer's instruction and after an initial denaturation of 95 for 10 min, the following thermal cycling profile was used (50 cycles): 95 C for 10 s, 55 C for 20 s and 72 C for 30 s. Finally melting curve analysis from 65 to 95 was performed and the data was processed using the LightCycler 480 software with basic relative quantification program ($\Delta\Delta CT$ method). Primer sequences (Supplementary Table 1) were designed by Beacon Designer software (Version 7.9).

Statistical analysis

The quantitative data were presented as the mean \pm standard deviation (SD) and One-way ANOVA with subsequent tukey post-hoc tests was used to compare the data between the groups. Kruskal-Wallis H and non-parametric ANOVA were used for statistical analysis of the qualitative data obtained from the scored values, and if the differences were significant ($P < 0.05$), then analyzed by Mann-Whitney U test. The results with P values less than 0.05 were considered statistically significant. Statistical analyses were performed using the SPSS software (IBM SPSS Statistics for Windows, Version 20.0, Armonk, NY: IBM Corp).

3. Results

Gross morphology

Gross morphology of the lesions is illustrated in Figure 1, A. At the end of day 10 PI the wound sizes were

significantly lower in the *L. plantarum* gel ($p < 0.05$) treated group as compared to the base gel and untreated groups. The wounds size was lower in the *L. plantarum* and SSD, in 20 DPI, as compared to other two treatment groups, but there were no significant differences between the *L. plantarum* gel treated and the other groups. The treated wounds with *L. plantarum* and silver sulfadiazine had better cosmetic appearance at 20 DPI than the other experimental groups. No wounds became infected and normal healing response occurred in all the wounds (Figure 1A).

Biomechanical performance

Treatment with *L. plantarum* and SSD increased the ultimate tensile strength compared to the negative control and base gel lesions, at 10 and 20 DPI. However, the differences were not statistically significant at 10 DPI, whereas the differences between the *L. plantarum* and other groups were statistically significant at 20 DPI and the *L. plantarum* treated group showed higher ultimate tensile strength ($p < 0.05$) at this time point (Figure 1B).

Histopathologic and histomorphometric findings

The wounds in the negative control group (diabetic rats without any treatment) displayed evident inflammatory cell infiltration and granulation tissue formation, however, re-epithelialization was not completed, even at the 20 DPI. Histopathological evaluation of the SSD group showed moderate infiltration of leukocytes into the wound area, at 10 days. The epithelialization process was completed at 20-day post-treatment. The inflammatory cells were significantly fewer when compared to the negative control group, at 20 DPI.

The histological findings of the base gel treated group showed a close similarity to the negative control group, with hemorrhages, hyperemia and infiltration of inflammatory cells in the tissue sections, at 10-DPI. Re-epithelialization was not completed at 20 DPI, and the inflammatory response significantly decreased in comparison to day 10 post-injury in this group. The photomicrographs of the wounds treated by *L. plantarum* showed a considerable reduction in inflammatory cells, at 10 DPI and 20 DPI in comparison to other groups ($p < 0.05$). A complete epithelial layer with presence of rete ridges was formed in the *L. plantarum* treated wounds, at 20 DPI. This group showed more resemblance to normal skin and demonstrated a thin epidermis with presence of normal rete ridges, rejuvenation of hair follicles and other

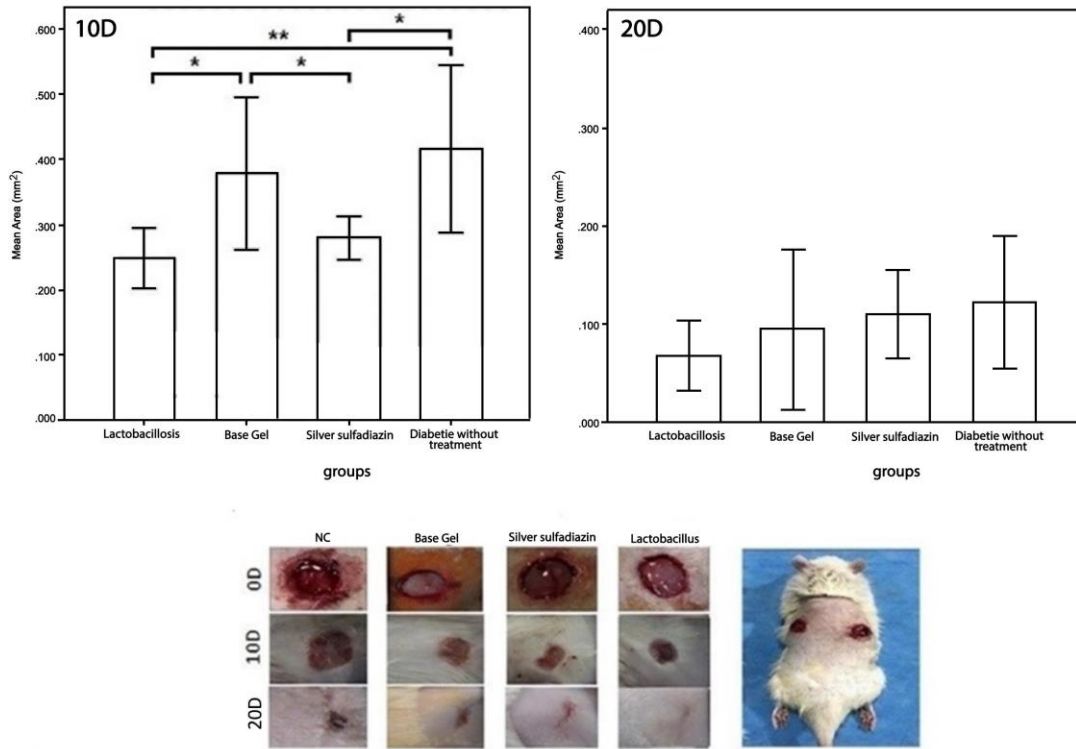
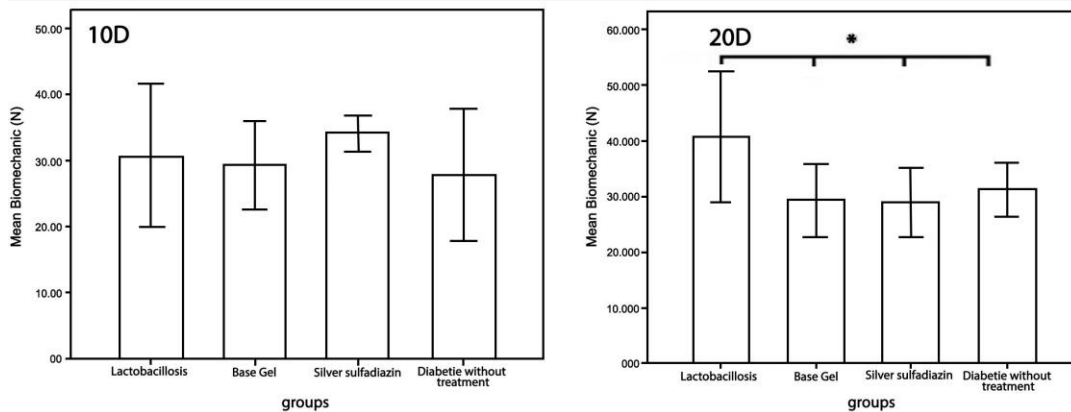



Figure 1. A, Template of burn wounds on the dorsum of rat (four full thickness burn wounds at day 0), gross morphology of the burn wounds and the percentage of wounds size after inducing burn wounds at the 10th and 20th days of treatment in different experimental groups (Mean ±SD). The mean surface area of the wounds (mm²) was significantly lower in the *L. plantarum* and SSD treated wound when compared to the base gel and untreated group at 10 DPI. However, there was no statistically significant differences between all groups in terms of wounds' mean surface area. **B,** Ultimate tensile strength in different experimental groups at the 10th and 20th DPI. Picture of the Universal Instron tensile testing machine while loading a skin specimen. The *L. plantarum* treated group showed a considerable improvement in biomechanical properties at 20 DPI when compared to other groups. * $p < 0.05$, * $p < 0.01$. SSD: Silver sulfadiazine, NC: negative control (untreated), BG: Base Gel, *L. plantarum* Gel.

A



B



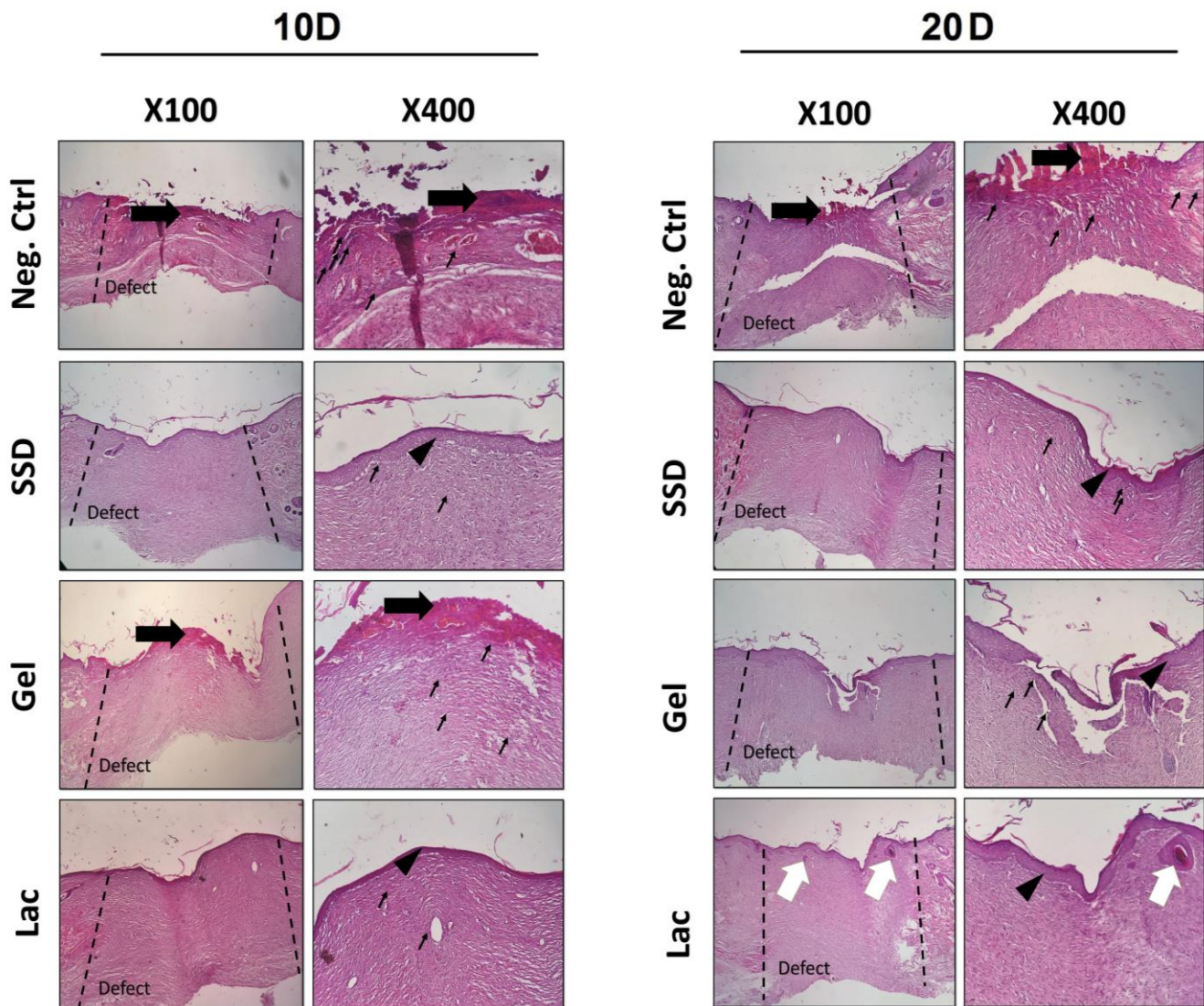


Figure 2. Histopathological sections of the healing incisional wounds at 10 and 20 DPI. The re-epithelialization process was completed in the SSD and *L. plantarum* treated groups at 20 DPI (stained by H&E). Moreover, rejuvenation of the skin appendages such as hair follicles was seen in the *L. plantarum* treated group at 20 DPI. Thick arrows: crusty scab, thin arrows, infiltration of inflammatory cells, arrowheads: Re-epithelialization, white arrows: rejuvenation of the skin appendages.

Table 1. Histomorphometric analysis of wounds at the 10th and 20th day post-treatment

Groups	Epithelialization Scores (N=5)	Fibrocytes and fibroblasts 174.2±15.2	Inflammatory cells 86.2±4.1	Blood vessels 5.7±1.2
Negative control	0,0,0,0,0 (10 d)	174.2±15.2 (10 d)	86.2±4.1(10 d)	5.7±1.2 (10 d)
	0,1,0,1,0 (20 d)	275.2±14.5 (20 d)	54.4±7.5(20 d)	14.5± 1.3(20 d)
SSD	1,0,2,1,2 (10 d)*	193.5±9.6(10 d)	42.8±4.6 (10 d) *	12.0±2.5 (10 d) *
	4,2,4,3,3 (20 d)***	104.5±28.2 (20 d) ***	17.3±2.8 (20 d) **	7.2± 1.6 (20 d) *
Gel	1,0,0,1,0 (10 d)	221.3±11.1*(10 d)	75.5±7.4(10 d)	10.3±1.8 (10 d)
	3,2,3,2,1 (20 d)**	217.8±11.3 (20 d) *	29.7±2.5 (20 d) **	15.1± 3.4 (20 d)
<i>Lactobacillus spp.</i>	2,2,1,3,3 (10 d)**	325.7±19.8 (10 d) ***	26.2±4.5 (10 d) **	8.1±1.3 (10 d)
	4,2,3,4,2 (20 d)***	135.9±7.4 (20 d) **	7.8±1.1 (20 d) ***	10.5± 2.8 (20 d)

*, **, ***: values indicates treatment group versus un-treatment group (negative control); * $p<0.05$, ** $p<0.01$, *** $p<0.001$

skin appendages.²⁴ Therefore, the *L. plantarum* treated wounds showed the best results when compared to the negative control and other experimental groups.

The histomorphometric analysis was done at 10 and 20 days after burn injuries and the results have been presented in Table 1. Amongst all groups, re-epithelialization was minimum in the negative control group and the wounds in the animals of this group were mostly filled with immature granulation tissue ($p < 0.05$). The best re-epithelialization was seen in the *L. plantarum* treated group. Moreover, the total inflammatory cell counts significantly reduced in the *L. plantarum* treated group in comparison to other groups, at 10 and 20 DPI ($p < 0.05$). Overall, the healing condition of the *L. plantarum* treated diabetic wounds was more similar to those of the normal skin, and the wounds had the best cosmetic appearance with normal thickness of the epidermal layer and rejuvenation of the skin appendages (Figure 2).

Hydroxyproline content

Since collagen formation is a critical step in wound healing, so we evaluated the hydroxyproline content as a marker of collagen content.²⁵ Hydroxyproline content in the *L. plantarum* and SSD treated wounds were higher than the negative control and base gel groups in 10 and 20 PDI. Although the hydroxyproline contents in the *L. plantarum* and SSD treated groups were more than the other groups but the differences between the groups were not statistically significant (Figure 3A).

TGF- β mRNA expression

Relative mRNA expression of TGF- β significantly increased in the *L. plantarum* treated group on day 10 post-wounding as compared to the SSD, NC and untreated groups ($p < 0.05$). Although the expression level of TGF- β in the SSD group was higher among the other groups, no significant differences were seen, at day 20 PI (Figure 3B). The result of gene expression level in Day 10 post-treatment are shown in the supplementary Table 2.

4. Discussion

The results of the present study indicate that local application of *L. plantarum* can successfully suppress the inflammatory response and promote burn wound healing in diabetic rats. Development of new and effective interventions in wound care remains an area of intense research. Several studies have been done to find new products for treating wounds.²⁶⁻²⁹ Some diseases like

diabetes may cause hinder in wound healing.³⁰ Diabetes even in its early stages impairs the normal course of wound healing, thus leading to chronic wounds. It has been speculated that diabetes interferes with various phases of repair by decreasing growth-factor levels in the wound environment.⁵ Delay in cellular infiltration and formation of granulation tissue are possible reasons for prolonged epithelialization in diabetes.³¹ Diabetes causes reductions in collagen organization; diminished blood supply; impaired leukocyte function; unbalanced production of growth factors, cytokines and proteases; increased blood viscosity and delayed conversion of acute to chronic inflammation.^{4,9,32,33} In the present study, therefore, the STZ-induced diabetic rats were used as the model of diabetes to study diabetic wound healing. Our results showed that *L. plantarum* can accelerate the wound healing process by decreasing duration of inflammatory response.

A probiotic is a single strain or a mixture of different organisms and it is proposed that probiotics can enhance wellbeing through immunomodulatory, metabolic and barrier activities against pathological processes.³ Probiotics can provide local immunity and protection to the gastric ulcers and it has been stated that the probiotic microbes such as *Lactobacillus* improved healing of the gastric ulcers in rats.³⁴ It has also been showed that probiotics have the ability to enhance healing of the gastric ulcers specifically by enhanced angiogenesis and expression of growth factors, such as VEGF, TGF- β and EGF.³⁵ Probiotics can enhance the overall body immunity by immunomodulation.³⁶ New data based on human fibroblast cultures and DNA microarrays suggest that probiotics possess the distinct ability to naturally stimulate the skin's immune response. In essence, probiotics boost skin repair and healing.¹⁶ *L. plantarum* is a probiotic organism that produces lactic acid.³⁷ It is a micro-organism that does not produce virulent factors and succumbs easily to the antimicrobial battery of host defenses, particularly activation of the polymorphonuclear cell activity.¹⁸

L. plantarum has been shown to have beneficial effects in the wound healing process in our study and our results were in harmony with other studies. The antimicrobial activity of kefir 96 h gel has been shown to be similar to silver sulfadiazine 1% ointment but the wound healing time has been shown to be lower in kefir 96 h gel when compared to silver sulfadiazine ointment.¹⁷ Rodrigues et al found that probiotics can both decrease inflammation and restore the wounded area.³⁸ The anti-inflammatory properties of polysaccharides present in the Kefir extracts also influence the wound healing process and stimulate innate immune responses in defense against pathogens.¹⁷ Our investigation was in harmony with other studies and

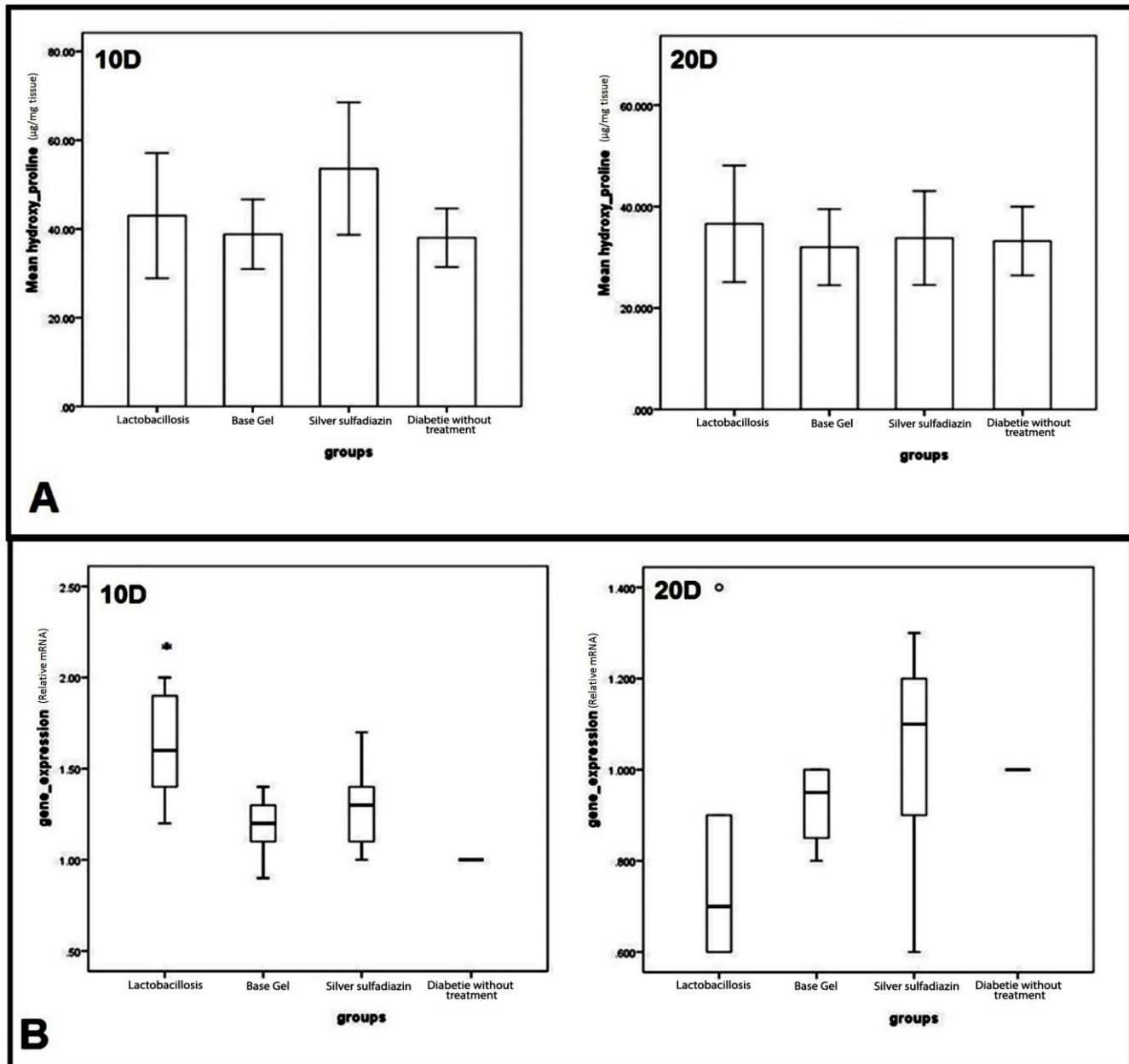


Figure 3. A, Hydroxyproline content in the wound tissue during wound healing. Values are mean \pm SD, n = 5 for each group. There were no significant differences between all groups in terms of mean hydroxyproline content ($\mu\text{g}/\text{mg}$ tissue) on the 10th or 20th DPI. **Bb** mRNA expression of TGF- β in different experimental groups on days 10 and 20 PI. The TGF- β mRNA expressions significantly increased on day 10 in the *L. plantarum* treated wounds. *P* value indicates the *L. plantarum* treated group in comparison to all other treated and un-treated groups: **p* < 0.05.

the total number of inflammatory cells in the *L. plantarum* treated group was significantly lower in comparison to others at 10 and 20 days post-treatment.

The wound status in the *L. plantarum* and SSD treated groups was obviously improved on day 10 compared to the gel based treated and untreated groups while the wound area in the gel treated and untreated groups showed little recovery on day 10. The wound surface area was significantly smaller in the *L. plantarum* treated group in

both 10 and 20 days post injury in our study and this emphasizes better wound contraction compared to the other groups. *L. plantarum* treatment, in this study, decreased inflammatory cell infiltration by reducing the number of inflammatory cells at day 10 and 20 post injury and increased the number of fibroblasts and fibrocytes at this stage.

Collagen formation is a critical step in wound healing and collagen is a major extracellular matrix protein which

confer strength and integrity to tissue and also plays a role in hemostasis by interacting with thrombocytes.³⁹ Collagen provides tensile strength, organization and integrity to connective tissues, and in the present study we evaluated the hydroxyproline content as a marker of collagen content.⁴⁰ It has been shown that diabetes can cause reductions in collagen content.⁹ Treatment by *L. plantarum* gel, in the present study, resulted in enhanced level of hydroxyproline content on day 10 after injury in comparison to the negative control and untreated group and the hydroxyproline content was comparable to the silver sulfadiazine treated group at this time point. Increased level of hydroxyproline in the *L. plantarum* and SSD treated groups provided more strength to the wound and this data was supported by enhanced biomechanical performance of the *L. plantarum* and SSD treated groups that showed higher ultimate tensile strength compared to the other groups although the difference in biomechanical evaluation were not significant.

It has been speculated that the effect of *L. plantarum* culture on diabetic burn wounds could be because of the fact that the cytokine and growth factor pattern induced by *L. plantarum* in inflammatory cells is different from those induced by pathogens like *P. aeruginosa*.⁴¹ *P. aeruginosa* induced higher levels of PGE2 (prostaglandin E2) compared with the low level induced by *L. plantarum*, and it also should be highlighted that *L. plantarum* demonstrated a great anti-inflammatory activity.⁴²⁻⁴⁴ Our study also showed that treatment by *L. plantarum* enhances the expression level of TGF- β in wound at early stages of wound healing. TGF- β was significantly higher in the *L. plantarum* treated lesions than the base gel and untreated wounds at day 10 post injury. TGF- β is a critical peptide which is responsible to control repair, chemotactically attract inflammatory cells to a wound, and promote deposition of ground substance and collagen; therefore, it has been aptly called a “wound hormone”.⁴⁵ TGF- β has been shown to be deficient in models of impaired healing. Topical application of TGF- β accelerated biomechanical performance in incisional wounds in rats.⁴⁵ In addition, increase in TGF- β expressions could promote fibroblasts to synthesize collagen proteins, fiber connexin and integrin, and enhance migration of epithelial cells.⁴⁵ Increased TGF- β in the *L. plantarum* treated group could be the reason for earlier wound closure, greater degree of collagen deposition, better biomechanical performance and also having the best cosmetic appearance compared to other groups. It should be mentioned that Becaplermin, a drug for treatment of diabetic wounds, promotes healing in diabetic wounds by increasing the expression level of TGF- β .^{45,46} In addition, it has been stated that *L. plantarum*

showed great anti-inflammatory activity and this feature could be another reason for its potent wound healing capacity.¹⁸ It has been reported that the positive effects of hyaluronic acid on burn injuries are due to its anti-inflammatory effects.⁴⁷ Therefore, the anti-inflammatory properties present in *L. plantarum* may have a potential role in enhanced wound healing.

Amongst all groups, re-epithelialization was minimum in the negative control group and it was mostly filled with immature granulation tissue. The best re-epithelialization was seen in the *L. plantarum* treated group specially, at day 20 after injury, and this treatment regimen showed better results than silver sulfadiazine which is a standard burn wound treatment regimen. Therefore, quicker collagen deposition, earliest and highest TGF- β expression and the anti-inflammatory effect of *L. plantarum* may be act as the main mechanisms in improving wound healing in diabetic rats. Overall, the healing criteria of the *L. plantarum* treated diabetic wounds were more similar to those of the normal skin and demonstrated the best cosmetic appearance, with normal thickness of epidermal layer and rejuvenation of the hair follicles and skin appendages.

Topical application of *L. plantarum* gel not only promoted wound healing by enhancing collagen synthesis, it also increased the number of fibroblasts and fibrocytes and increased TGF- β level and decreased the risk of infection. Thereby, *L. plantarum* may provide a safe, effective, and less expensive alternative in managing diabetic and also burn wound treatment. The results of our investigation demonstrated that *L. plantarum* can be used as a topical treatment regimen in treatment of delayed wound healing and can be introduced as a promising alternative to conventional methods in treating delayed wound healing.

Conflict of interest

The authors declare that they have no conflict of interests.

References

1. Cardoso C, Favoreto Jr S, Oliveira L, Vancim J, Barban G, Ferraz D, Silva J. Oleic acid modulation of the immune response in wound healing: a new approach for skin repair. *Immunobiology*, 2011; 216(3): 409-415.
2. Nilani P, Pranavi A, Duraisamy B, Damodaran P, Subhashini V, Elango K. Formulation and evaluation of wound healing dermal patch. *African Journal of Pharmacy and Pharmacology*, 2011; 5(9): 1252-1257.
3. Simova E, Beshkova D, Angelov A, Hristozova T,

- Frangova G, Spasov Z. Lactic acid bacteria and yeasts in kefir grains and kefir made from them. *Journal of Industrial Microbiology and Biotechnology*, 2002; 28(1): 1-6.
4. Pradhan L, Cai X, Wu S, Andersen ND, Martin M, Malek J, Guthrie P, Veves A, Logerfo FW. Gene expression of pro-inflammatory cytokines and neuropeptides in diabetic wound healing. *Journal of Surgical Research*, 2011; 167(2): 336-342.
 5. Bitar MS, Labbad ZN. Transforming growth factor- β and insulin-like growth factor-I in relation to diabetes-induced impairment of wound healing. *Journal of Surgical Research*, 1996; 61(1): 113-119.
 6. Arturson G. Pathophysiology of the burn wound and pharmacological treatment. The Rudi Hermans Lecture, 1995. *Burns*, 1996; 22(4): 255-274.
 7. Pirbalouti AG, Azizi S, Koochpayeh A. Healing potential of Iranian traditional medicinal plants on burn wounds in alloxan-induced diabetic rats. *Revista Brasileira de Farmacognosia*, 2012; 22(2): 397-403.
 8. Witte MB, Thornton FJ, Tantry U, Barbul A. L-Arginine supplementation enhances diabetic wound healing: involvement of the nitric oxide synthase and arginase pathways. *Metabolism-Clinical and Experimental*, 2002; 51(10): 1269-1273.
 9. Goodson WH, Hunt TK. Studies of wound healing in experimental diabetes mellitus. *Journal of Surgical Research*, 1977; 22(3): 221-227.
 10. Jeffcoate WJ, Harding KG. Diabetic foot ulcers. *The lancet*. 2003; 361(9368): 1545-1551.
 11. Shalom A, Friedman T, Wong L. Burns and diabetes. *Annals of Burns and Fire Disasters*, 2005; 18(1): 31.
 12. Atiyeh BS, Costagliola M, Hayek SN, Dibo SA. Effect of silver on burn wound infection control and healing: review of the literature. *Burns*, 2007; 33(2): 139-148.
 13. Hollinger MA. Toxicological aspects of topical silver pharmaceuticals. *Critical Reviews in Toxicology*, 1996; 26(3): 255-260.
 14. Lansdown A, Williams A. How safe is silver in wound care? *Journal of Wound Care*, 2004; 13(4): 131-136.
 15. MacKay DJ, Miller AL. Nutritional support for wound healing. *Alternative Medicine Review*, 2003; 8(4): 359-378.
 16. Sekhar MS, Unnikrishnan M, Vijayanarayana K, Rodrigues GS, Mukhopadhyay C. Topical application/formulation of probiotics: Will it be a novel treatment approach for diabetic foot ulcer? *Medical Hypotheses*, 2014; 82(1): 86-88.
 17. Huseini HF, Rahimzadeh G, Fazeli MR, Mehrazma M, Salehi M. Evaluation of wound healing activities of kefir products. *Burns*, 2012; 38(5): 719-723.
 18. Valdez J, Peral M, Rachid M, Santana M, Perdigon G. Interference of *Lactobacillus plantarum* with *Pseudomonas aeruginosa* in vitro and in infected burns: the potential use of probiotics in wound treatment. *Clinical Microbiology and Infection*, 2005; 11(6): 472-479.
 19. Solanki HK, Shah DA. Formulation Optimization and Evaluation of Probiotic *Lactobacillus sporogenes*-Loaded Sodium Alginate with Carboxymethyl Cellulose Mucoadhesive Beads Using Design Expert Software, *Journal of Food Processing*, 2016, Article ID 6041671.
 20. Qiu Z, Kwon A-H, Kamiyama Y. Effects of plasma fibronectin on the healing of full-thickness skin wounds in streptozotocin-induced diabetic rats. *Journal of Surgical Research*, 2007; 138(1): 64-70.
 21. Oryan A, Jalili M, Kamali A, Nikahval B. The concurrent use of probiotic microorganism and collagen hydrogel/scaffold enhances burn wound healing: An in vivo evaluation. *Burns*, 2018; 44(7): 1775-1786.
 22. Oryan A, Khalafi-Nezhad A, Toloo N, Soltani Rad MN. Effects of 4-chloro-2,6-bis-(2-hydroxybenzyl)-phenol on healing of skin wounds and growth of bacteria. *Journal of Veterinary Medicine A, Physiology, Pathology, Clinical Medicine*, 2007; 54(10): 585-591.
 23. Edwards C, O'Brien Jr W. Modified assay for determination of hydroxyproline in a tissue hydrolyzate. *Clinica Chimica Acta*, 1980; 104(2): 161-167.
 24. Takeo M, Lee W, Ito M. Wound healing and skin regeneration. *Cold Spring Harb Perspect Med*. 2015; 5(1): a023267.
 25. Caetano GF, Fronza M, Leite MN, Gomes A, Frade MA. Comparison of collagen content in skin wounds evaluated by biochemical assay and by computer-aided histomorphometric analysis. *Pharmaceutical Biology*, 2016; 54(11): 2555-2559.
 26. Oryan A, Alemzadeh E, Moshiri A. Biological properties and therapeutic activities of honey in wound healing: a narrative review and meta-analysis. *Journal of Tissue Viability*, 2016; 25(2): 98-118.

27. Oryan A, Khalafi- Nezhad A, Toloo N, Rad S. Modulation of cutaneous wound healing by silymarin in rats. *Journal of Wound Care*, 2012; 21: 457-464
28. Oryan A, Mohammadalipour A, Moshiri A, Tabandeh M. Avocado/soybean unsaponifiables: a novel regulator of cutaneous wound healing, modelling and remodelling. *International Wound Journal*, 2015; 12(6): 674-685.
29. Oryan A, Mohammadalipour A, Moshiri A, Tabandeh MR. Topical application of aloe vera accelerated wound healing, modeling, and remodeling: an experimental study. *Annals of Plastic Surgery*, 2016; 77(1): 37-46.
30. Guo Sa, DiPietro LA. Factors affecting wound healing. *Journal of Dental Research*, 2010; 89(3): 219-229.
31. Pelegrinelli FF, Thirone AC, Gasparetti AL, Araujo EP, Velloso LA, Saad MJ. Early steps of insulin action in the skin of intact rats. *Journal of Investigative Dermatology*, 2001 ;117(4): 971-976.
32. Bohlen HG, Niggel BA. Arteriolar anatomical and functional abnormalities in juvenile mice with genetic or streptozotocin-induced diabetes mellitus, *Circulation Research*. 1979; 45(3): 390-396.
33. Jeffcoate W, Van Houtum W. Amputation as a marker of the quality of foot care in diabetes. *Diabetologia*, 2004; 47(12): 2051-2058.
34. Lam EK, Yu L, Wong HP, Wu WK, Shin VY, Tai EK, So WH, Woo PC, Cho CH. Probiotic *Lactobacillus rhamnosus* GG enhances gastric ulcer healing in rats. *European Journal of Pharmacology*, 2007; 565(1-3): 171-179.
35. Dharmani P, De Simone C, Chadee K. The probiotic mixture VSL 3 accelerates gastric ulcer healing by stimulating vascular endothelial growth factor, *PLoS One*. 2013; 8(3): e58671.
36. Isolauri E, Sütas Y, Kankaanpää P, Arvilommi H, Salminen S. Probiotics: effects on immunity-. *The American Journal of Clinical Nutrition*, 2001; 73(2): 444s-450s.
37. Meydani SN, Ha W-K. Immunologic effects of yogurt-. *The American Journal of Clinical Nutrition*, 2000; 71(4): 861-872.
38. Rodrigues KL, Caputo LRG, Carvalho JCT, Evangelista J, Schneedorf JM. Antimicrobial and healing activity of kefir and kefir extract. *International Journal of Antimicrobial Agents*, 2005; 25(5): 404-408.
39. Rasik A, Raghubir R, Gupta A, Shukla A, Dubey M, Srivastava S, Jain HK, Kulshrestha DK. Healing potential of *Calotropis procera* on dermal wounds in Guinea pigs. *Journal of Ethnopharmacology*, 1999; 68(1-3): 261-266.
40. Rodnan GP, Lipinski E, Luksick J. Skin thickness and collagen content in progressive systemic sclerosis and localized scleroderma, *Arthritis & Rheumatology*. 1979; 22(2): 130-140.
41. Hessle C, Andersson B, Wold AE. Gram-positive bacteria are potent inducers of monocytic interleukin-12 (IL-12) while gram-negative bacteria preferentially stimulate IL-10 production. *Infection and Immunity*, 2000; 68(6): 3581-3586.
42. Hessle CC, Andersson B, Wold AE. Gram-negative, but not Gram-positive, bacteria elicit strong PGE 2 production in human monocytes. *Inflammation*, 2003; 27(6): 329-332.
43. de Vos WM. Lipoteichoic acid in lactobacilli: D-alanine makes the difference. *Proceedings of the National Academy of Sciences of the United States of America*, 2005; 102(31): 10763-10764.
44. Sidhu GS, Mani H, Gaddipati JP, Singh AK, Seth P, Banaudha KK, Patnaik GK, Maheshwari RK. Curcumin enhances wound healing in streptozotocin induced diabetic rats and genetically diabetic mice. *Wound Repair and Regeneration*, 1999; 7(5): 362-374.
45. Ammann AJ, Beck LS, DeGUZMAN L, Hirabayashi SE, Pun Lee W, McFATRIDGE L, Nguyen T, Xu Y, Mustoe TA. Transforming Growth Factor- β Effect on Soft Tissue Repair. *Annals of the New York Academy of Sciences*, 1990; 593(1): 124-134.
46. Nall AV, Brownlee RE, Colvin CP, Schultz G, Fein D, Cassisi NJ, Nguyen T, Kalra A. Transforming growth factor β 1 improves wound healing and random flap survival in normal and irradiated rats. *Archives of Otolaryngology-Head & Neck Surgery*, 1996; 122(2): 171-177.
47. Medeiros AdC, Ramos AMdO, Dantas Filho AM, Azevedo RdCFd, Araújo FLFB. Tratamento tópico de queimaduras do dorso de ratos com ácido hialurônico. *Acta Cirúrgica Brasileira*, 1999; 14(4): 203-207.

نشریه جراحی دامپزشکی ایران
سال ۲۰۱۹، جلد ۱۴ (شماره ۱)، شماره پیاپی ۳۰

چکیده

درمان موضعی زخم های سوختگی در موش های صحرایی دیابتی شده به وسیله باکتری پروبیوتیک
لاکتوباسیلوس پلانتاروم

مسعود سالاران^۱، احمد عریان^۲، بهروز نیک احوال^۱، امیر کمالی^۲، مهران قائمی^۳، فاطمه عباسی تشنیزی^۴، محمد
عزیززاده^۵

^۱بخش علوم درمانگاهی، دانشکده دامپزشکی، دانشگاه شیراز، شیراز، ایران
^۲بخش پاتولوژی، دانشکده دامپزشکی، دانشگاه شیراز، شیراز، ایران
^۳بخش بیوتکنولوژی، دانشکده دامپزشکی، دانشگاه شیراز، شیراز، ایران
^۴بخش بیوشیمی، دانشکده دامپزشکی، دانشگاه شیراز، شیراز، ایران
^۵بخش علوم درمانگاهی، دانشکده دامپزشکی، دانشگاه فردوسی مشهد، مشهد، ایران

هدف- این مطالعه در جهت بررسی اثرات باکتری لاکتوباسیلوز پلانتاروم بر روی زخم های سوختگی در رت های دیابتی شده انجام شده است.

طرح مطالعه- مطالعه تجربی تصادفی

حیوانات- ۴۰ قطعه موش صحرایی نر

روش کار- ابتدا موش ها به وسیله داروی استرپتوزوتوسین دیابتی شدند. ۲۱ روز پس از دیابتی شدن، موش هایی که دیابت آن ها تأیید شد وارد مطالعه شدند و به صورت تصادفی به ۴ گروه درمانی تقسیم شدند: ۱. گروه بدون درمان ۲. گروه درمان با پماد سیلور سولفادیازین ۳. گروه پایه ژل ۴. گروه درمان شده با باکتری لاکتوباسیلوز پلانتاروم. دو عدد زخم سوختگی بر روی پشت موش های صحرایی ایجاد شد و سپس ۴۸ ساعت بعد از ایجاد سوختگی زخم ها با پانچ بیوپسی دربرید شدند. حیوانات در روز ۱۰ (تعداد = ۵) و روز ۲۰ (تعداد = ۵) بعد از ایجاد جراحی پوتنایز شدند و نمونه های پوستی جهت انجام آزمایش هیستولوژی، سنجش میزان هیدروکسی پرولین، میزان بیان ژن TGF- β و آزمون های بیومکانیک گرفته شد.

نتایج- آنالیز داده های آماری نشان داد زخم های درمان شده با باکتری پروبیوتیک لاکتوباسیلوس پلانتاروم سطح زخم کوچک تری در مقایسه با سایر گروه های درمانی داشته اند و میزان بیان ژن TGF- β در روز ۱۰ بعد از جراحی از سایر گروه ها بیشتر بوده است، همچنین میزان هیدروکسی پرولین که شاخصی از میزان کلاژن می باشد در گروه لاکتوباسیل در روز ۲۰ بعد از جراحی از تمام گروه های دیگر بیشتر بود.

نتیجه گیری و کاربرد بالینی- استفاده از باکتری پروبیوتیک لاکتوباسیلوس پلانتاروم برای درمان زخم می تواند درمان مناسبی باشد و در آینده می تواند به عنوان جایگزین مناسبی برای داروهای سنتتیک مورد استفاده قرار بگیرد.

واژه های کلیدی- ترمیم زخم، دیابت، سوختگی، باکتری پروبیوتیک لاکتوباسیلوس پلانتاروم، ژن TGF- β

Supplementary Table 1. Primer sequences of Real-time RT-PCR

Gene name	Primer name	Primer sequence
TGF- β	Tgf F	5`-GGACCGCAACAACGCAATCT-3`
	Tgf R	5`-TCTGGCACTGCTTCCCGAAT-3`
β -actin	Actin F	5`-TGGCACCACCATGTACCCAG-3`
	Actin R	5`-TCCACACAGAGTACTTGCGCTCA-3`

Supplementary Table 2. Result of gene expression ratio in Day 10 post treatment

Group name	Average of gene expression ratio ($\Delta\Delta CT$)	SD
Base gel	1.18	0.19
	1.04	0/27
Silver sulfadiazine	1.3	0.27
	1/02	0/28
Diabetic without treatment	1	0.00
	1	0.00
Lactobacillose	1.62	0.33
	0.84	0.34