



Clinical Report

Occurrence of Xanthelasma in a Cow (the First Report)

**Amin Derakhshanfar^{*1} Ph.D
Mohammad Mehdi Molaei² DVSc**

*¹Department of Pathobiology and ²Department of Clinical Sciences,
Faculty of Veterinary Medicine, Shahid Bahonar University of Kerman,
Kerman, Iran.*

Abstract

Case Description- An eight-year-old Holstein cow with inflamed and abnormal left eyelid was referred to the veterinary clinic of Shahid Bahonar University of Kerman.

Treatment and Outcome- Because of involvement of all structures of the eye, exentration was done and abnormal tissues sent for histopathologic examination. Microscopic evaluations revealed mononuclear histiocytes filled with lipid in the dermis. Therefore, xanthelasma was diagnosed.

Clinical Relevance- Xanthelasma is a kind of xanthoma of the eyelid which appeared as yellow, raised plaques contain foamy lipid laden macrophages. This tumor-like lesion is reported in human and rarely in dog, cat and birds. Some authors believe that hyperlipoproteinemia is the cause of the disease. This is the first report of occurrence of xanthelasma in cow.

Key words : Xanthelasma, Xanthoma. Eyelid, Cow

***Corresponding Author:**

Amin Derakhshanfar

Department of Pathobiology, Faculty of Veterinary Medicine, Shahid Bahonar Univ. of Kerman, Kerman , Iran.

E-mail: damin @mail.uk.ac.ir

Case Description

An eight-year-old Holstein cow with severe inflammation of the left third eyelid was referred to veterinary clinic of Shahid Bahonar university of Kerman. The formation of inflamed, yellow, abnormal tissues began from 15 months before. The lesion was resected, two times, by veterinary technicians, but recovery was not achieved and purulent abnormal tissues were reformed. Clinical examination revealed the involvement of all structures of the eye ball (fig.1), therefore, the exentration of the eye was the choice.

Treatment and Outcome

After surgical preparation and lacrimal and supraorbital nerve block, exentration of the abnormal eye was done. The rest of the skin around the eye was then sutured. After operation, penicillin + streptomycin (Nasr Pharmaceutical, Fariman, Iran), (15000 IU / Kg body weight) and dexamethazone (Nasr Pharmaceutical, Fariman, Iran), (1 mg TD), were administered. For histopathologic evaluation, some parts of the lesions were transferred to 10% buffered formalin for one week. After routine processing of the tissues, sections of 5 microns thickness were stained by haematoxylin and eosin and examined under light microscope.

Histopathologic findings revealed the accumulation of foamy macrophages in deep dermis. These full fill fat histiocytes possessed one nucleus, but there was not remarkable fibrosis (fig.2). Microscopic studies confirmed the absence of cholesterol clefts in tissue slides, therefore, xanthelasma was diagnosed. To this time, the disease has not been returned.

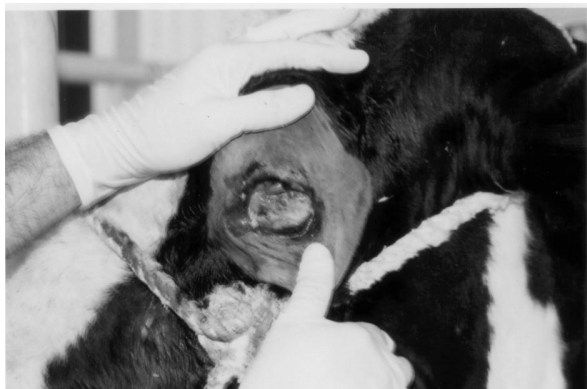

Fig. 1: The eye of the cow is affected by inflamed, abnormal tissues

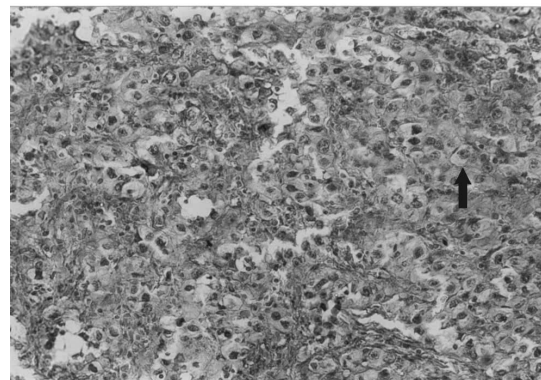


Fig.2: A collection of lipid laden foamy macrophages (arrow) in dermis of the eyelid is seen. H&E stain; 400 \times .

Discussion

Clinical examination of the patient showed that because of erroneously manipulation and treatment, damage of the eye, expansion of abnormal mass and suppuration of the lesion occurred.

Xanthelasma is the most common of the cutaneous xanthoma, consists of slightly raised, yellow, soft plaques on the eyelids¹. The term xanthoma, from the Greek for yellow, is used to describe conditions in which lipid accumulates in macrophages in the skin or other organs. In these tumor-like lesions, the macrophages are called histiocytes². Other researchers believe that xanthoma is a non-neoplastic mass of foamy macrophages occurs in domestic animals and birds. Such lesions, usually are associated with increase in plasma levels of cholesterol or

triglycerids. In this condition, focal or multifocal raised, white-yellow skin nodules create. Xanthelasma occurs in human and rarely in cat, dog and birds but there is no report in equidae and cattle³. Therefore, this is the first report of occurrence of xanthelasma in a cow. In human, xanthelasma occurs with or without hyperlipoproteinemia. Microscopic studies have shown the nearly complete absence of fibrosis in human specimens. Xanthoma cells are foam macrophages that, because of their ability to phagocytize, have become filled with lipid droplets¹. Systemic xanthomatosis in a cat associated with hyperchylomicronaemia and involvement of internal organs such as liver, spleen, kidney, adrenal, mesenter and colon is reported⁴. Long term consumption of corticosteroids is recognized as the cause of atherosclerotic changes of the vessels, hyperlipoproteinemia and cutaneous xanthomatosis in cat⁵. Previously, xanthomatous lesion of the iris and ciliary body of a dog was reported⁶. Interestingly, corneal lipidosis, and xanthomatosis with hypercholesterolemia has been occurred in amphibians⁷. This condition is rarely seen in poultry today. It is characterized by an accumulation of semi fluid yellowish material under the skin of chickens. Later, they became firm with chalky white areas of cholesterol clefts, fibrous tissue, foamy macrophages and giant cells⁸. A typical multiple xanthomatous lesion is seen in a 18 months old goose affected by hypercholesterolemia and hypertriglyceridemia⁹. Xanthoma must be differentiated from granulomatous inflammation. Histiocytic type of mast cell tumor in cat is similar to xanthoma, but infiltration of eosinophils and lymphocytes in the former is characteristic. Surgical treatment for xanthoma is recommended³.

References

1. Lever WF, Lever GS. *Histopathology of the skin*. 7th ed. Philadelphia: J.B.Lippincott Co., 1990:427-430.
2. Ritchie AC. *Boyd's text book of pathology*. 9th ed. Philadelphia: Lea & Febiger, 1990:2055.
3. Meuten DJ (). *Tumors in domestic animals*. 4th ed. London: Blackwell Publishing Co, 2002:111.
4. Chanut F, Colle MA, Deschamps JY, et al. Systemic xanthomatosis associated with hyperchylomicronaemia in a cat. *J Vet Med A Physiol Pathol Clin Med* 2005; 52:272-274.
5. Wissulink MA, Koeman JP, Wensing T, et al. Hyperlipoproteinaemia associated with atherosclerosis and cutaneous xanthomatosis in a cat. *Vet Quart* 1994;16:199-202.
6. Mays MB, Nguyen HT, Wolf ED, et al. A xanthomatous lesion resembling balloon cell melanoma of the iris and ciliary body of a dog. *J Comp Pathol* 1985;95:217-25.
7. Wright K. Cholesterol, corneal lipidosis, and xanthomatosis in amphibians. *Vet Clin North Am Exot Anim Pract* 2003;6:155-67.
8. Saif YM. *Diseases of poultry*. 11th ed. London: Blackwell Publishing Co, 2003;558.
9. Jaensch SM, Butler R, O'hara A, et al. A typical multiple, papilliform, xanthomatous, cutaneous neoplasia in a goose (*Anser anser*). *Aust Vet J* 2002;80:277-80.

اولین گزارش وقوع گزانت لاسما در گاو

دکتر امین درخشانیفر^۱، دکتر محمد مهدی مولایی^۲

^۱ گروه پاتوبیولوژی، دانشکده دامپزشکی، دانشگاه شهید باهنر کرمان، کرمان، ایران.
^۲ گروه علوم درمانگاهی، دانشکده دامپزشکی، دانشگاه شهید باهنر کرمان، کرمان، ایران.

توصیف بیمار: یک رأس گاو هولشتین ۸ ساله با تورم و بافت های غیر طبیعی پلک چشم چپ به کلینیک دانشکده دامپزشکی دانشگاه شهید باهنر کرمان ارجاع گردید.

درمان و نتیجه آن: نظر به درگیری تمامی ساختارهای چشم اقدام به تخلیه چشم و ارسال نمونه های غیر طبیعی به آزمایشگاه پاتولوژی شد. مطالعات میکروسکوپی منجر به تشخیص هیستوسیت های تک هسته ای سرشار از چربی در عمق درم گردید و از اینرو عارضه گزانت لاسما تشخیص داده شد.

کاربرد بالینی: گزانت لاسما به انواعی از گزانتوما در پلک اطلاق می شود که بصورت پلاک های برآمده و زرد رنگی متشکل از ماکروفاژهای کف آلود حاوی چربی ظاهر می یابد. این ضایعه شبه توموری در انسان و ندرتاً در سگ و گربه و پرندگان گزارش شده است. برخی هیپرلیپوپروتئینمی را عامل بیماری دانسته اند. مقاله حاضر اولین گزارش وقوع این عارضه در گاو است.
کلید واژه گان: گزانت لاسما، گزانتوما، پلک، گاو