



Original study

Arthroscopic Findings Following Experimental Cranial Cruciate Ligament Desmotomy in Dog

Kamran Sardari¹, DVSc

Associate Professor of Veterinary Surgery

Ahmad Reza Raji², Ph.D

Assistant Professor of Veterinary Anatomical Sciences

Nazanin Farazan³, DVM

¹Department of Clinical Sciences, Faculty of Veterinary Medicine, Ferdowsi University of Mashhad, Meshad, Iran.

²Department of Basic Sciences, Faculty of Veterinary Medicine, Ferdowsi University of Mashhad, Meshad, Iran.

³Veterinary Student, Faculty of Veterinary Medicine, Ferdowsi University of Mashhad, Iran.

Abstract:

Objective- Using the arthroscopic surgery technique for experimental transection of cranial cruciate ligament and arthroscopic findings of stifle joint following ligament transection.

Design- Experimental study.

Animals- Five healthy mixed breed dogs.

Corresponding author

Kamran Sardari,

Department of Clinical Sciences, Faculty of Veterinary Medicine, Ferdowsi University of Mashhad, Mashhad, Iran.

P.O. Box 91775-1793

Telephone#: 0098 511 6620101-2

Fax #: 0098 511 6620166

E-mail: sardari@ferdowsi.um.ac.ir

Procedures- Five dogs (mean weight 27±3 kg, mean age 3 years) selected to study the stifle joint changes after experimental cranial cruciate ligament desmotomy. The cranial cruciate ligament of the one stifle joint was transected via arthroscopy in all dogs under general anesthesia. One month after cranial cruciate ligament desmotomy the arthroscopic examination of the joints was performed again. Lateral and anteroposterior radiography were also carried out before transected of the ligament and one month after ligament surgery just before second arthroscopy.

Results- All dogs had various degree of lameness during the study and showed inflammatory changes in the joint. In all animals arthroscopic observation showed various degrees of the articular cartilage damage and meniscal injuries.

Conclusion and Clinical Relevance- According to the results of present study, the cranial cruciate ligament is vital to normal function and rupture of this ligament results in progressive and permanent degenerative changes within the joint.

Key Words- arthroscopic surgery, stifle, dog, cruciate ligament

Introduction

Arthroscopy is used for definitive diagnosis and surgical treatment of selected conditions^{1,2}. Treatment of Osteochondrosis dissecans (OCD) of the shoulder, elbow, stifle, and hock joint in dog and horse have been described^{3,4}. Internal stabilization of the stifle joint after rupture of the cranial cruciate ligament has been performed successfully in dogs, however, carbon fiber implants failed and instability returned^{2,5}. Tissues are traumatized less with arthroscopy than with arthrotomy, producing shortened recovery times³. Arthroscopy facilitates inspection of intra-articular soft tissue and cartilage not apparent on radiographs, and the visibility of most structure is better than with arthrotomy^{2,6}. Direct examination of joint surfaces with magnification and optimal lighting improves diagnostic accuracy. With proficiency, operative time, anesthesia time, and the potential for complications from anesthesia are reduced⁶.

Complete and incomplete rupture of the cranial cruciate ligament is the most common cause of stifle lameness in the dog^{2,7,8}. The condition was first described in 1926¹⁷, and numerous papers have been published on all aspects of the problem with the greatest emphasis being placed on methods of treatment^{2,9-11}. Classical contributions to understanding and treatment of this condition have been made by several workers⁹⁻¹². Despite the frequency of this condition, a number of aspects still remain controversial^{11,13}. The main subjects of the controversy are the pathogenesis of the injury, the need for and the technique of treatment, and lastly the best method of rehabilitation. The significance of the cranial cruciate ligament to normal joint function can be assessed by studying the dynamic function of the cranial cruciate ligament⁸, and the reaction within the joint to experimental transection of the ligament¹³. The cranial cruciate ligament function is the primary stabilizer to cranial displacement of the tibia. The significance of this function is magnified by the fact that the normal angulations of the joint during weigh-bearing and load transfer is 130 degree of flexion¹³. In conjunction with the caudal cruciate and collateral ligaments, the cranial cruciate ligament limits internal rotation, particularly during flexion¹⁴. The cranial cruciate ligament is also the primary check against hyperextension of the stifle⁸. Transection or rupture of the cranial cruciate ligament results in increase cranial tibial displacement, increased internal rotation during flexion and hyperextension of the joint¹³. Abnormal motion between the articular surfaces of the joint results in early changes to the consistency of the hyaline cartilage^{14,15}. Changes in the ground substance and superficial cellular layers results in fibrillation of the cartilage, that may followed by developing of fissures through of this layers of the articular cartilage^{14,16}. Peri-articular new bone formation (osteophytes) occurs as a result of increased vascularity of the subchondral bone¹⁴. The cranial cruciate ligament is vital to normal joint function and rupture of the ligament results in progressive and permanent degenerative changes within the joint^{13,14}. The purpose of this study was to use the arthroscopy technique for experimental transection of cranial cruciate ligament and arthroscopic findings following ligament transection.

Materials and Methods

Animals:

Five mixed breed dogs (mean weight 27 ± 3 kg, mean age 3 years) were used in this study. Dogs were housed in kennel and fed a maintenance ration twice daily and had free access to water. They were given rabies vaccine and antiparasitic drugs (praziquantel 5 mg/kg and piperazine 100 mg/kg, PO). Also, all of dogs were treated against ectoparasite and housed for two weeks before surgery. For investigation of animal's health, clinical examination, CBC (complete blood count) and blood serum biochemical analysis (BUN, creatinine, ALT, AST, ALP, GGT, cholesterol, glucose) were performed. All dogs were free of lameness. Lateral and anteroposterior radiography were carried out to confirm the soundness of both stifle joint in all dogs and that no detectable lesion was observed. The radiographic examination was performed again at the end of the study.

Experimental set up

One pelvic limb was randomly chosen for aseptic stifle arthroscopy. Anesthesia was induced by using acepromazine 0.1 mg/kg, IM and sodium thiopental 2.5% 15 mg/kg IV and followed by halothane and oxygen. Under general anesthesia and lateral recumbency with the limb rotated externally, the cranial cruciate ligament was found (Figure 1) and transected using arthroscopic guide near the cranial intercondylar area of the tibia (Figure 2). An 18 gauge needle was inserted above the fat at the lateral to the patellar tendon and normal saline was injected to distend the joint capsule. The arthroscopic cannula was inserted through a skin incision using a blunt obturator at the lateral to the patellar ligament proximal to the fat pad. Fluids were attached to the ingress port on the arthroscopic cannula and the egress portal was inserted to the joint at the opposite site of the arthroscopic cannula. Ringer solution was used to flush the joint during arthroscopy. Skin incision was sutured by Nylon No. 0 Post surgical antibiotic and analgesic therapy included cefazolin 20 mg/kg IM for 4 days and diazepam 5 mg/kg IM once daily for 3 days, respectively. Four days after surgery, the dogs walking with a person for 20 minutes every day for 4 weeks. After this time, under general anesthesia with previously mention method the arthroscopy was performed again in all dogs to observe the joint cavity.

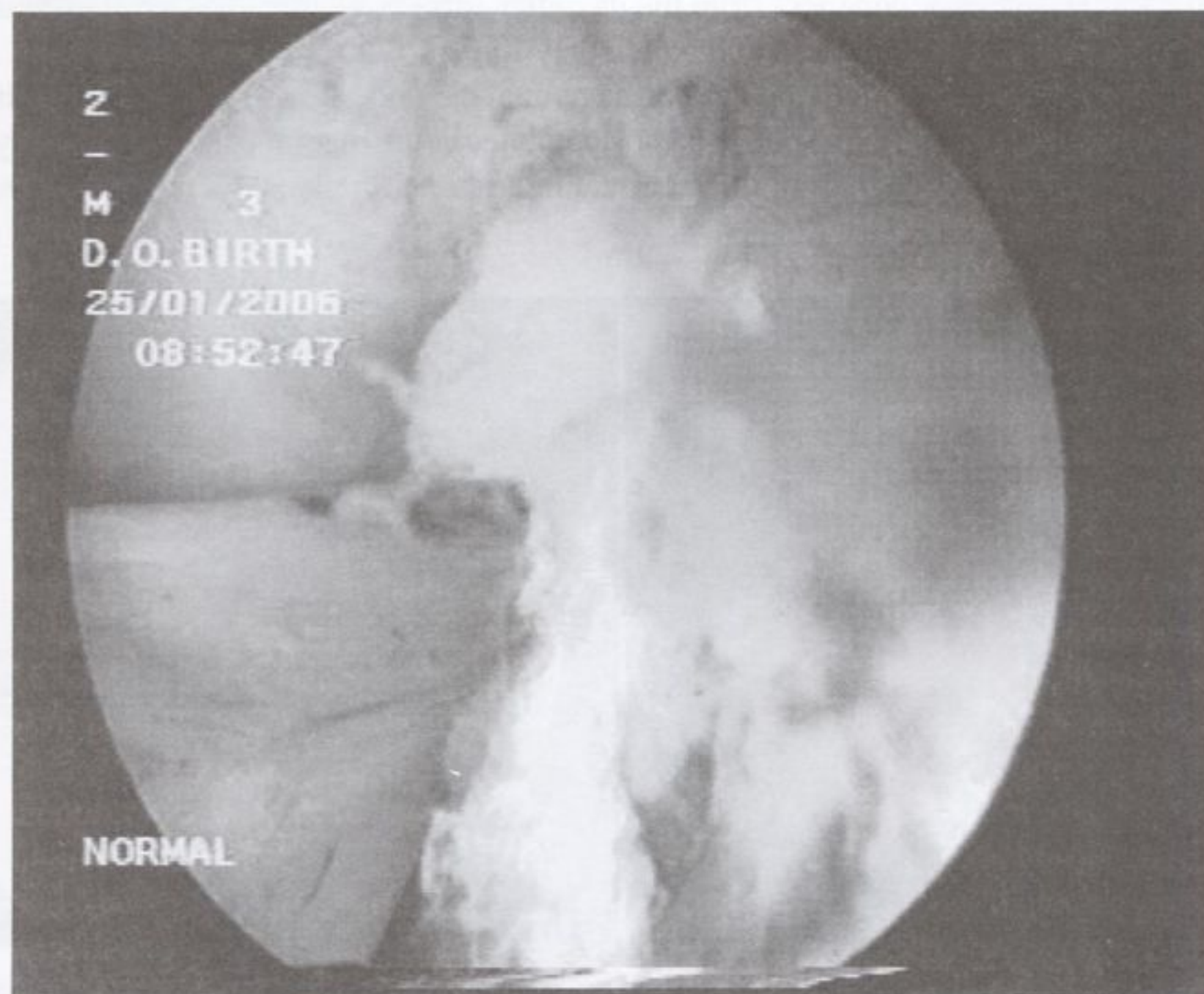


Fig 1: Normal cranial cruciate ligament .

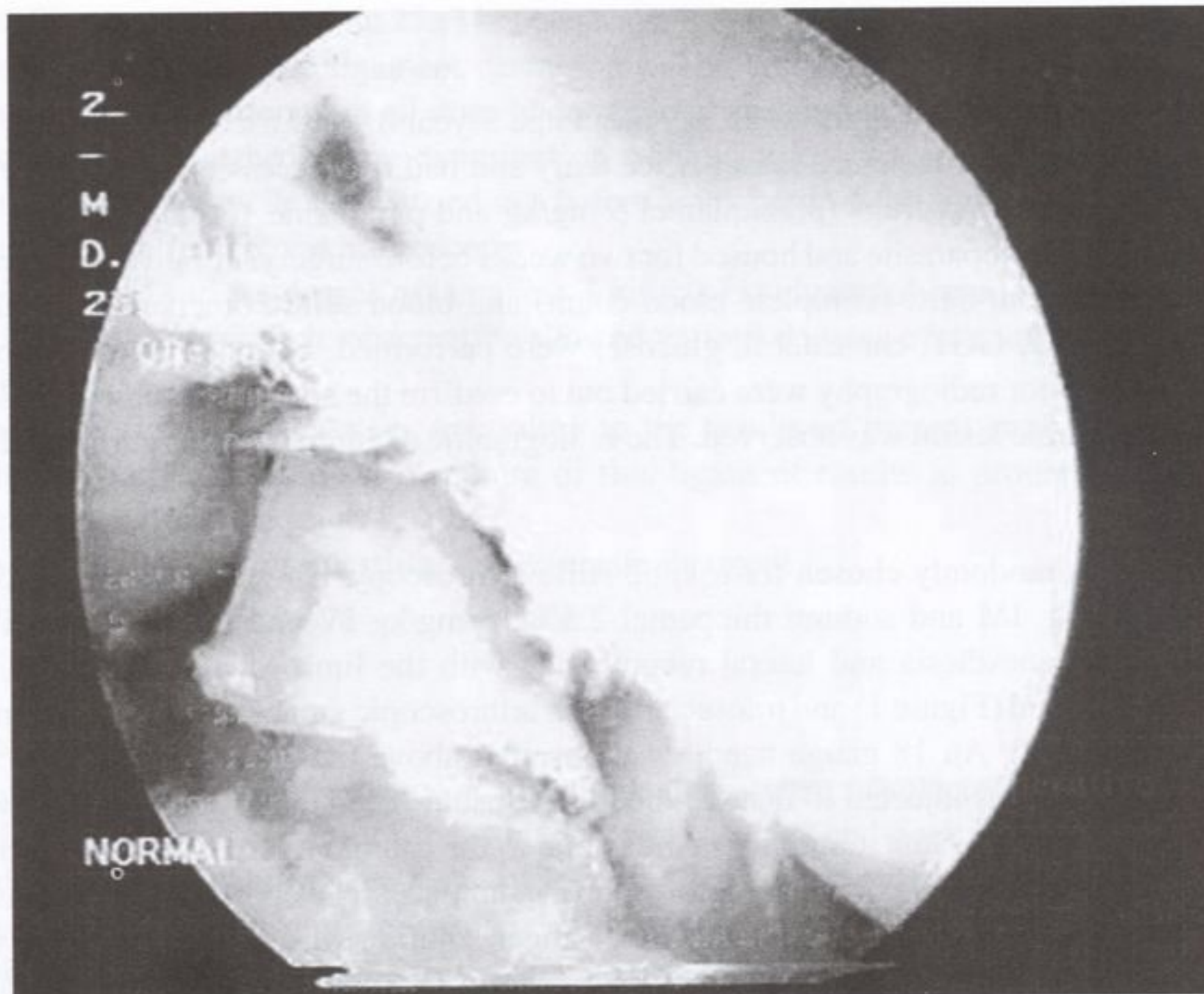


Fig 2 : Cranial cruciate ligament after transection.

Results

All dogs had various degree of lameness from the day after surgery up to end of the study, but at the end of the study the dogs showed the lameness only when they forced to run.

All dogs had various degrees of the articular cartilage damage and one dog had cartilage damage with subchondral bone injury (Figure 3) Four dogs had osteophytes at the margins of femoral condyles (Figure 4). All five dogs showed various degrees of the meniscal injuries especially at the medial meniscus (Figure 5).

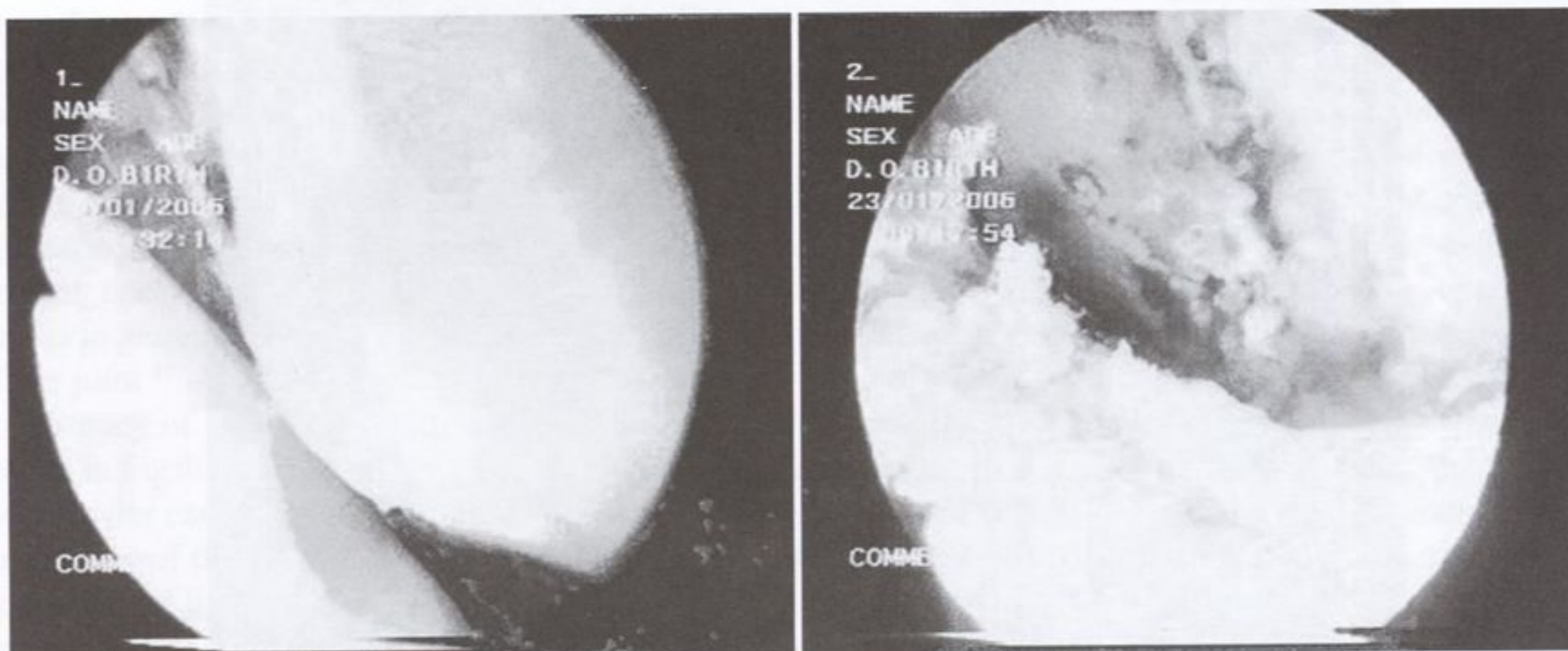


Fig 3: A) Articular cartilage damage on the lateral femoral condyle. B) Articular cartilage damage at the medial femoral condyle.

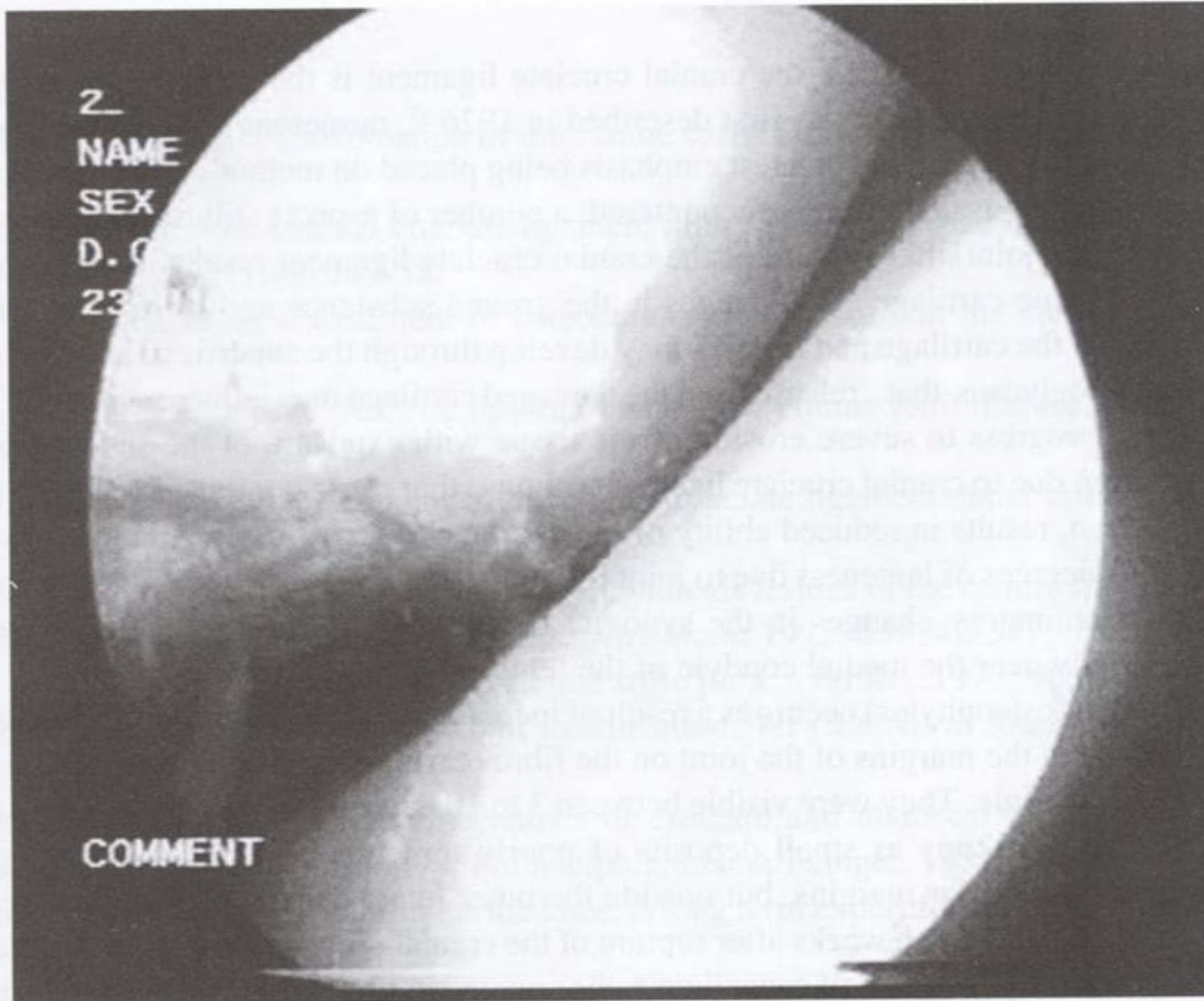


Fig 4: Osteophytes at the margins of femoral condyle

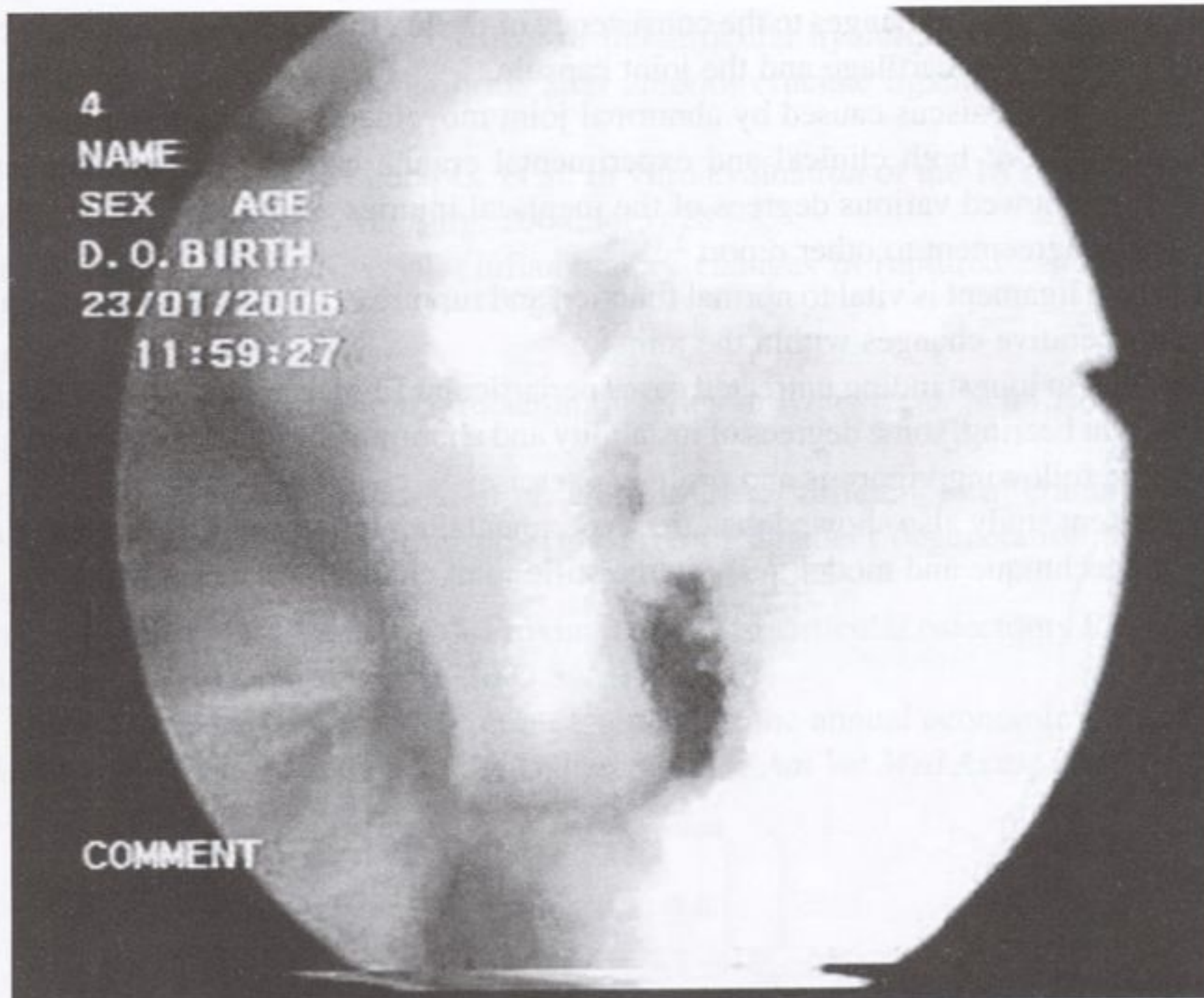


Fig 5: Meniscal injuries at the medial meniscus.

Discussion

Complete and incomplete rupture of the cranial cruciate ligament is the most common cause of stifle lameness in the dog². The condition was first described in 1926¹⁷, numerous papers have been published on all aspects of the problem with the greatest emphasis being placed on methods of treatment^{2,18}. Despite the frequency with which this condition is encountered, a number of aspects still remain controversial^{11,19}. Abnormal motion of the joint after rupture of the cranial cruciate ligament results in early changes to the consistency of the hyaline cartilage^{2,15}. Changes in the ground substance and superficial cellular layers, results in fibrillation of the cartilage and fissures may develop through the superficial layers of the articular cartilage. Glycosaminoglycans that release from the damaged cartilage may induce secondary⁹. Fibrillation of the cartilage may progress to severe erosion of the tissue with exposure of the subchondral bone^{3,19}. Abnormal joint motion due to cranial cruciate ligament rupture, that cause continued wear and tear and also poor cartilage nutrition, results in reduced ability of the cartilage to repair itself¹⁹. In the present study all dogs showed various degrees of lameness due to joint inflammation and synovitis. Also at the present study all dogs showed inflammatory changes in the synovial membrane with proliferations of the superficial synovial cells especially near the medial condyle of the femur.

New bone formation (osteophytes) occurs as a result of increased vascularity to the subchondral bone. The osteophytes developed at the margins of the joint on the fibro- cartilaginous junction between the articular cartilage and the joint capsule. They were visible between 3 to 10 days after experimental transaction of the criciate ligament by arthroscopy as small deposits of poorly mineralized cartilage covering cancellous bone, developing at the articular margins, but outside the outer intact cortex¹⁹. These nodules ossify and were visible radiographically 3 to 6 weeks after rupture of the cranial cruciate ligament^{4,19}. Isolated nodules gradually coalesce to form large strips of cancellous bone covered in fibro cartilage. Gradually, they become incorporated into the femoral condyles to produce and overall enlargement of the joint^{2,19}. At the present study four dogs had osteophytes at the margins of femoral condyles. The osteophytes in four dogs were visible radiographically at the end of the study at the margins of the femoral condyles. This observation showed that abnormal motion between the articular surfaces of the joint after resection of the cranial cruciat ligament, results in early changes to the consistency of the hyaline cartilage at the fibro cartilaginous junction between the articular cartilage and the joint capsule.

Damage to the medial meniscus caused by abnormal joint movement is a common finding with cranial cruciate ligament rupture of both clinical and experimental cranial cruciate ligament rupture¹⁸. At the present study all dogs showed various degrees of the meniscal injuries especially at the medial meniscus. This observation is in agreement to other report^{2,18,19}.

The cranial cruciate ligament is vital to normal function and rupture of the ligament results in progressive and permanent degenerative changes within the joint².

Despite the fact that in longstanding untreated cases periarticular fibrosis may provide sufficient stability to allow normal weight bearing, some degrees of instability and abnormal joint motion remains, and lameness is the likely outcome following vigorous and prolong exercise^{2,13}.

The results of present study also showed that, the experimental resection of the cranial cruciate ligament in dog is a valuable technique and model to study the stifle joint changes via arthroscopy.




Fig. 3. An anteroposterior radiograph of the stifle joint showing the femoral condyles and the joint space.

References:

- 1- Miller CW, Presnell KR. Examination of the canine stifle: arthroscopy versus arthrotomy. *J Am Anim Hosp Assoc* 1985; 21: 623-629.
- 2-Jerram RM, Walker AM. Cranial cruciate ligament injury in the dog: pathophysiology, diagnosis and treatment. *N Z Vet J* . 2003;51(4):149-58.
- 3-Person MW. Arthroscopic treatment of osteochondritis dissecans in the canine shoulder. *Vet Surg* 1989; 18: 175-189.
- 4- McIlwraith CW, Fessler JF. Arthroscopy in diagnosis of equine joint disease. *J Am Vet Med Assoc* 1978; 172: 263-268
- 5- Person MW. Prosthetic replacement of the cranial cruciate ligament under arthroscopic guidance: a pilot project. *Vet Surg* 1987; 16:37-43.
- 6-Van Bree H, Van Ryssen B, Desmidt M. Osteochondrosis lesions of the canine shoulder: correlation of positive arthrography and arthroscopy. *Vet Radial Ultrasound* 1992; 33: 342-347.
- 7- Turgari M, Vaughan LC. Arthritis of the canine stifle joint. *Vet Rec* 1977; 96: 394.
- 8-Saunders DG, Walker JR, Levine D. Joint mobilization. *Vet Clin North Am Small Anim Pract* 2005; 35(6):1287-316.
- 9- Arnoczky SP, Marshall JL. Pathomechanics of cruciate and meniscal injuries. In Bojrab MJ, ed *Pathophysiology in Small Animal Surgery*, Philadelphia, Lea & Febiger, 1981; 345-354.
- 10- Marshall JL, Olsson SE. Instability of the knee: A long term experimental study in dogs. *J Bone Joint Surg*, 1971; 53A: 1561.
- 11-Vasseur PB. Clinical results following nonoperative management of rupture of the cranial cruciate ligament in dogs., *Vet Surg* 1984; 13: 243.
- 12-Fernandes JC, Jovanovic D, Dehnade F, et al. Resection of the anterior cruciate ligament of the knee using arthroscopy induces arthrosis in dogs. Validity of the Pond-Nuki model. *Ann Chir*1998; 52(8):768-75.
- 13-Smith G Jr, Myers SL, Brandt KD. Effect of intraarticular hyaluronan injection on vertical ground reaction force and progression of osteoarthritis after anterior cruciate ligament transection. *J. Rheumatol* 2005; 32(2):325-34.
- 14-Banwell MN, Kerwin SC, Hosgood G, et al. In vitro evaluation of the 18 and 36 kg Securos Cranial Cruciate Ligament Repair System. *Vet Surg*. 2004;34(3):283-8.
- 15-Barrett JG, Hao Z, Graf BK, et al. Inflammatory changes in ruptured canine cranial and human anterior cruciate ligaments. *Am J Vet Res* 2005; 66(12):2073-80.
- 16- Carlin I. Ruptur des ligamentum cruciatum anterius in Kniegelenk beim Hund. *Arch. Wissensch Prakt Tierhalk* 1926;54: 420.
- 17-Comerford EJ, Tarlton JF, Wales A, et al. Ultrastructural differences in cranial cruciate ligaments from dogs of two breeds with a differing predisposition to ligament degeneration and rupture. *J Comp Pathol* 2006;134(1):8-16.
- 18-Jerram RM, Walker AM, Warman CG. Proximal tibial intraarticular ostectomy for treatment of canine cranial cruciate ligament injury. *Vet Surg* 2005;34(3):196-205.
- 19-Wilke VL, Robinson DA, Evans RB, et al. Estimate of the annual economic impact of treatment of cranial cruciate ligament injury in dogs in the United States. *J Am Vet Med Assoc* 2005;15;227(10):1604-7

چکیده:

یافته های آرتروسکوپی متعاقب قطع تجربی وتر ضربدری قدامی

در مفصل رانی درشت نی سگ

دکتر کامران سرداری

دانشیار بخش جراحی، گروه علوم درمانگاهی، دانشکده دامپزشکی،

دکتر احمد رضا راجی

استادیار بخش آناتومی، گروه علوم پایه، دانشکده دامپزشکی، دانشگاه فردوسی مشهد، مشهد، ایران.

نازنین فرازان

دانشجوی دامپزشکی، دانشکده دامپزشکی، دانشگاه فردوسی مشهد، مشهد، ایران.

هدف: بررسی تغییرات آرتروسکوپیک مفصل رانی درشت نی در سگ پس از قطع تجربی رباط ضربدری قدامی.

طرح: مطالعه تجربی.

حیوانات: پنج قلابه سگ نژاد مخلوط با میانگین وزن ۲۷ کیلوگرم و میانگین سن ۳ سال.

روش کار: تحت بیهوشی عمومی و با استفاده از آرتروسکوپی رباط ضربدری قدامی در یک پای سگها قطع گردید. یک ماه

پس از قطع وتر، عمل آرتروسکوپی مجددا تکرار و مفصل مورد بررسی قرار گرفت. رادیوگرافی جانبی و جلوئی پشتی از مفاصل

فوق در حالت طبیعی و همچنین قبل از آرتروسکوپی دوم اخذ گردید.

نتایج: هر پنج قلابه سگ درجات مختلف لنگش را در طول تحقیق نشان می دادند. تمامی سگها مقادیر متفاوت التهاب

در مفصل را هنگام آرتروسکوپی دوم نشان دادند. تغییرات حاکی از آسیب غضروف مفصلی و همچنین جراحات مینیسک در

هر پنج قلابه سگ کاملا آشکار بود.

نتیجه گیری: از نتایج حاصل از تحقیق حاضر می توان نتیجه گرفت، که وتر ضربدری قدامی در مفصل رانی درشت نی برای

حرکات طبیعی مفصل حیاتی بوده و در صورت قطع و یا پارگی آن تغییرات استحالهای دائمی در مفصل شکل می گیرد.

کلید واژه ها: جراحی آرتروسکوپی، استایفل، سگ، رباط ضربدری