



Original Study

Beneficial Effects of Ag-Exchanged Zeolite Nanocomposite on Excisional Wound in Rats

Sara Javanmardi^{1*}, Baharak Divband,²

Abstract

Objective-The aim of this study was to investigate the healing effects of Ag+- zeolite/gelatin nanocomposite on excisional wound healing in rat animal model.

Design-Experimental study

Animals-Eighteen male Sprague-Dawley rats weighing 200-220g

Procedure- Ag+- zeolite/gelatin nanocomposite was fabricated by sol-gel method, and characterized by scanning electron microscopy (SEM) and X-ray diffraction (XRD) techniques. MTT assay and antimicrobial activity evaluation of the nanocomposite were performed. Under general anesthesia, a full thickness wound measuring 1.5×1.5 cm was created on dorsal area of each rat. The animals were equally and randomly divided into three groups of 6 each i.e. group I (0.9% sodium chloride), group II (gelatin – treated) and group III (nanocomposite –treated). The solutions and the formulation were applied topically on the wound once daily for 14 days. Photograph of each wound was taken on days 0,3,6,9,12 and 14 post wound creation. The area of wound was determined planimetrically. At 14 days, animals euthanized and skin samples were taken to histopathological evaluation (H&E staining).

Results- In this work, we successfully prepared Ag+- zeolite/gelatin nanocomposite. The prepared nanocomposite showed antimicrobial activity due to Ag ion-exchanging. The results indicate nanocomposite is safe up to 0.1 mg/ml of Ag+- zeolite/gelatin nanocomposite. Nanocomposite treated group exhibited enhancement of wound closure and accelerate wound healing time ($p<0.05$). Furthermore, nanocomposite treated group showed higher neovascularization and collagen content and faster regrowth of epidermis in repair area compared to other groups.

Conclusion and clinical relevance- In conclusion, biocompatible Ag+- zeolite/gelatin nanocomposite might have great application for open and full thickness wound healing.

Key words- Nanocomposite, Ag+- zeolite/gelatin, Excisional wound, Rat

Received: 29 June 2017; **Accepted:** 30 July 2017; **Online:** 1 September 2017

Introduction

Skin is often injured by wounds or physical traumas. Damages to skin commence a series of complex and well-orchestrated events of repair processes that result in the complete reestablishment of the integrity of wounded tissue and the restoration of this functional barrier.

However, the morbidity of the prolonged periods required for the repair and regeneration of the injured tissue, the bleeding, the risk of infections and septicemias, and the keloids and scar formation cause the deep lesions to the skin to remain a major clinical problem.¹

Although new therapeutic approaches for the treatment of such large and full thickness skin lesions have made progress, there is still need for better methods to improve wound healing and recovery especially in severely wounded patients. One of the approaches for treating the wounds and diminishing the risk of wound infection is the use of biocompatible composites incorporated with antibacterial agents.² Ion-exchange zeolite has attracted

¹Department of Clinical Sciences, Faculty of Veterinary medicine, University of Tabriz, Tabriz, Iran.

²Department of Inorganic chemistry, Faculty of Chemistry, University of Tabriz, Tabriz, Iran.

Address all correspondence to Sara Javanmardi (DVM, DVSc)

E-mail: s.javanmardi@tabrizu.ac.ir

www.ivsajournals.com © Iranian Journal of Veterinary Surgery, 2017

This work is licensed under the terms of the Creative Commons Attribution (CC BY-NC-SA 4.0)

DOI: 10.22034/ivsa.2017.50823

a lot of attention due to its renewable nature, good biocompatibility and excellent physical properties, which are important for a range of applications in pharmaceutical and biomedical fields.^{3,4} Several polymers are used for the fabrication of such composites including pectin, chitin, chitosan, alginate and gelatin.⁵⁻⁹ Among these, gelatin is regarded to be a suitable matrix due to its natural abundance, biocompatibility, biodegradability and non-immunogenicity.⁹ Recently, inorganic minerals such as clays and zeolites containing metals have become important in comparison with the conventional antibacterial agents. The incorporation of metallic ions whitens the silicate framework which is allowed for their controlled release and prevents the concentration dependent toxicity.⁴ In the present study, we investigated the potential of Ag-exchanged zeolite based nanocomposite for wound healing in the rat's excisional skin wound model.

Materials and method

Preparation of Ag+-zeolite/gelatin nanocomposite

First, Ag+-zeolite was prepared by a 24-h ion exchanging with a solution of 10g of zeolite and 300 ml of silver nitrate (1M) at ambient temperature. After each exchange process, the modified zeolite suspension was filtered and washed with copious amounts of deionized water. 0.4 gr gelatin was dissolved in 20 ml deionized water and a proper amount (0.5%wt of gelatin) of Ag+-zeolite was added and stirred for 1h. Finally, Ag+-zeolite/gelatin was prepared. Philips diffractometer was used to obtain X-ray diffraction pattern (XRD), (Fig.1). Scanning electron microscope (Philips ES 30 KW0) was used to investigate the morphology and size of nanoparticles (SEM image) (Fig. 2).

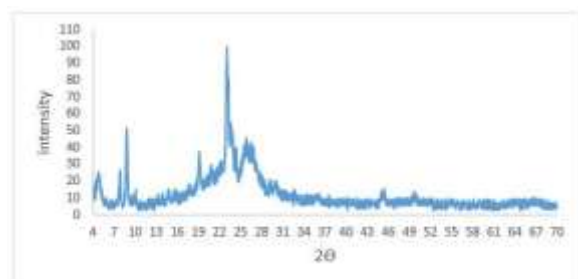


Figure 1. XRD pattern of Ag+-zeolite/gelatin nanocomposite




Figure 2. SEM image of Ag+-zeolite/gelatin nanocomposite

Cytocompatibility assay

The cytotoxicity of the prepared nanocomposite was evaluated using a colorimetric test named MTT assay. MCF-7 cells (9×10^3 cell/well) were incubated in 96-well plates each containing 200 ml of supplemented cell culture media for 24 h at 37 °C and 5% CO₂. The cells were divided into 4 groups in quadruplicates: blank and the Ag+-Zeolite/gelatin different concentrations of 0.1, 0.5, and 1 mg/ml were treated. After an incubation period of 24 h, the spent media were removed and the plate wells were washed with Phosphate buffered solution. Briefly, 50 IL of 2 mg/ml MTT and 150 IL culture media were added to each well. The cells were incubated at 37 °C and 5% CO₂ for 4 h. Then, the media were discarded and dimethyl sulfoxide and Sorenson buffer were added to each well as solubilizer buffers. Finally, absorbance was read using an ELISA plate reader (BioTeck, Bad Friedrichshall, Germany) at 570 nm wavelength.

Antimicrobial analysis

The antimicrobial activity of Ag+-Zeolite/gelatin nanocomposite was tested qualitatively. Three different microbes including: *Escherichia coli* 25922, *Staphylococcus aureus* 25923, and *Candida albicans* 0231 were used for testing the antimicrobial activity of the sample. The cells of *E.coli*, *S.aureus* and *C.albicans* were grown on nutrient agar and incubated at 37 °C for 48 h. The antimicrobial activity was tested using the modified agar diffusion assay (Well diffusion method). The plates were examined for possible inhibition zone after 48 h incubation. The presence of any clear zone around the samples on the plates was recorded as an inhibition against the microbial species. Finally, the microbial activities of each sample were repeated three times.

Animals

Eighteen male Sprague-Dawley rats (200-220 g) were individually housed in stainless steel cages under standard conditions and were given food (commercial rat pellet) and water ad libitum. In this period, the rats were adapted to handling for surgery. The experimental procedure and animal care were approved by the Ethics Committee of University of Tabriz.

Wound creation

The animals were fasted the night before surgery. Then, they were anesthetized with an intramuscular injection of 80 mg/kg of Ketamin 5% (Alfasan, Woerden, Netherlands) and 10 mg/kg Xylazine 2% (Alfasan, Woerden, Netherlands). The dorsal skin of the animals was shaved, antiseptic was provided with povidone iodine and one full thickness wound measuring 1.5×1.5 cm was created on each rat. After recovery from anesthesia, they were housed individually in properly disinfected cages. The animals were equally and randomly divided into three groups with 6 rats in each group i.e. group I (0.9% sodium chloride), group II (gelatin –treated) and group III (nanocomposite –treated). The solutions and the formulation were applied topically on the wound once daily for 14 days.

Planimetric evaluation

The photographs of each wound were taken on days 0,3,6,9,12 and 14 by a digital camera while a ruler was placed near the wounds edges. The wound area was measured using the image analyzing software (Image J, NIH, USA) and the wound contraction percentage was calculated using the following formula:

$$\text{Percentage of wound contraction} = (A_0 - A_t) / A_0 \times 100$$

Where A_0 is the original wound area and A_t is the wound area at the time of imaging.

Histomorphometric analysis

On the 14th day of the study, all of the animals were euthanized by anesthetic overdose and their skin samples were taken for histopathological analysis. The skin samples fixed in 10% neutral buffer formalin were embedded in paraffin and 5 μ m thick tissue sections were obtained and stained with H&E as per standard method. The stained sections were visualized under a light microscope (Olympus-CH30, Tokyo, Japan) at magnification $\times 100$ and $\times 400$. The histomorphometrical properties of the healing tissue

pathologist unknown to the experimental groups. Ten random fields from different sections in each group were examined. The wound healing process was assessed by the numeric scale developed by Breuing *et al.* for angiogenesis, collagen synthesis, and secondary infection as follows: score 1, no/minimal; score 2, low; score 3, moderate; score 4, extensive. Re-epithelialization was assessed as present or absent and the results were expressed as re-epithelialization percent.¹¹

Statistical analysis

Statistical analysis was undertaken by using Graph Pad Prism, Version 5.05 (Graph pad software, San Diego, USA). The analyses of the parametric data were performed by one-way ANOVA, repeated measure, followed by the Tukey post -test, and Kruskal-Wallis multivariate analysis, followed by Dunn's post-test for non-parametric data analysis. The results were expressed as mean \pm SD. In all of the analyses, $P < 0.05$ was considered as a significant differential level.

Results

MTT assay finding

Fig.3 shows the relative cell viability ([Cr/Co]) vs. different concentration of Ag+-zeolite/gelatin nanocomposite, determined by MTT assay. Here, Co refers to the viable cell numbers in the control samples, and Cr refers to the viable cell numbers treated with the nanocomposite. The error bars are calculated by the standard deviation. The relative viability of cells treated with 0.1 mg/ml of Ag+-zeolite/gelatin nanocomposite is about $95 \pm 4.5\%$. The relative viabilities (%) of cells treated with higher concentrations of Ag+-zeolite/gelatin nanocomposite (0.5 and 1 mg/ml) are 80 and 73% respectively after 24h incubation. The results indicate that nanocomposite is safe up to 0.1 mg/ml of Ag+-zeolite/gelatin nanocomposite.

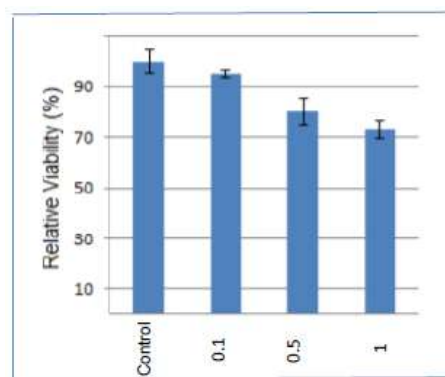


Figure 3. Relative viabilities of MCF-7 cells after being incubated with various concentrations of Ag+-zeolite/gelatin nanocomposite

sections were blindly scored by an experienced *Antimicrobial testing*

Table 1, shows a typical antimicrobial test result of Ag+-zeolite/gelatin nanocomposite. The bacteriostatic activity of zeolite was very low. After Ag-exchanging of samples, the antibacterial activity was increased and Ag+-zeolite showed a strong antimicrobial effect.

Because gelatin does not have an antimicrobial property, the Ag+-zeolite/gelatin nanocomposite exhibited lower bacteriostatic activity compared to Ag+-zeolite.

Table 1. Antimicrobial Activity of Gelatin, zeolite, Ag+-zeolite, Ag+-zeolite/gelatin against E.coli, S.aureus, C.albicans

Test Organism	E.coli	S.aureus	C.albicans
Sample			
Gelatin	-	-	-
Zeolite	+	-	-
Ag ⁺ -Zeolite	++	++	++
Ag ⁺ -zeolite/gelatin	+	+	+

Planimetric results

The representative photographs of the wound area of all of the three rats on days 0,3,6,9,12 and 14 are given in Fig. 4. The percent of the wound contraction was found to increase in a time-dependent manner in all of the groups (Fig. 5). Wound contraction was markedly higher in Ag+-zeolite/gelatin nanocomposite and gelatin treated rats, as compared to different days of post-wounding. Amongst the three groups, the nanocomposite treated wounds showed the fast contraction throughout the study period. Also nanocomposite treated groups indicated significant wound contraction on days 3,6,9,12 and 14 compared to gelatin and control treated groups (P<0.05). On day 14, group III rats demonstrated 97.00±58% wound reduction, group II rats showed 76.20±6.38% wound contraction, whereas group I rats showed only 43/60±4.72% wound reduction.

Histomorphometric findings

The histomorphometric results are presented in Table 2 and Fig. 6A-F. Nanocomposite treated wounds showed a superior healing process than those of the other groups. Almost complete re-epithelialization was observed in the case of group 3 rats with well-developed epidermal and dermal layers. Moreover, in

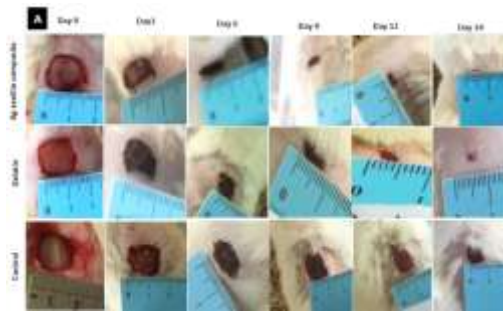


Figure 4. Macroscopic pictures of wounds of nanocomposite, gelatin and control rats

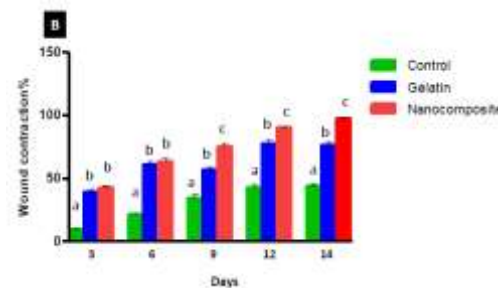


Figure 5. Assessment of wound area closure. All data reported as mean ± SD, *P < 0.05.

of the rete peg were seen (P=0.0001). However, complete re-epithelialization did not take place in the control group and scab tissue was found beneath which the epidermal layers were growing (Fig. 6 A vs. C and E). In addition, nanocomposite treated groups revealed a higher rate of collagen synthesis at the repaired area, compared to those of the control and gelatin groups (P=0.001). Furthermore, the nanocomposite treated rats revealed greater neovascularization amongst the groups. However, this difference was not statistically significant between the study groups; (P=0.074) (Fig 6 B vs. 6 D and F). Finally, in the evaluation of secondary infection score, the control group revealed the highest level, while, it was significantly low in the nanocomposite treated rats (P=0.003).

Discussion

In this study, we demonstrated Ag+-zeolite/gelatin nanocomposite's antimicrobial and healing efficacy on excisional wound healing using a unique sol-gel based formulation. Wound healing process begins with an inflammatory response which is followed by the proliferation and migration of dermal and epidermal cells and matrix synthesis, in order to fill the wounded area and re-establish the skin barrier. Finally, tissue remodeling

these rats, the absence of scab tissue and the presence

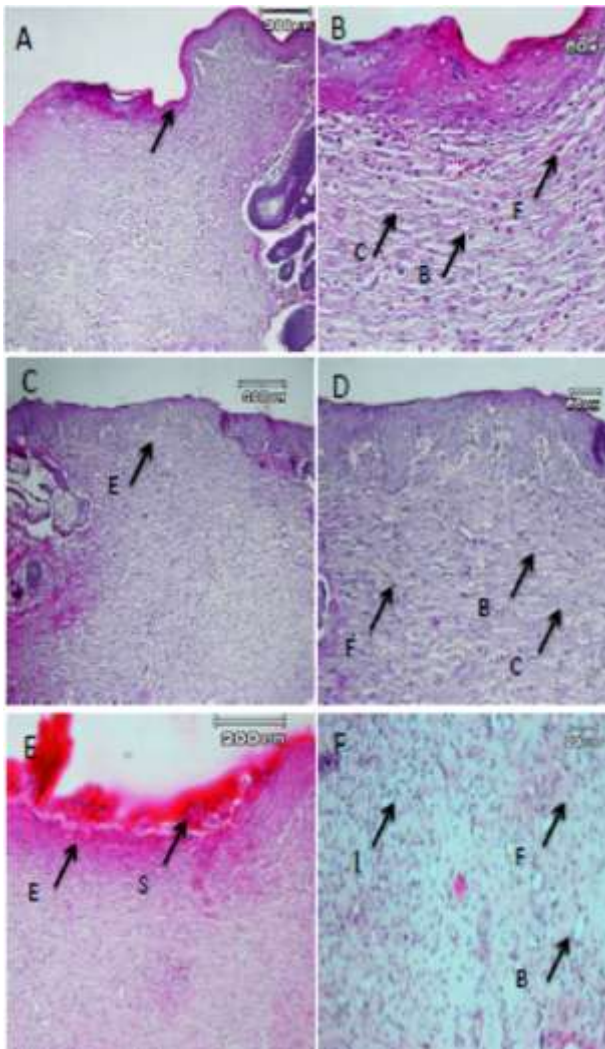


Figure 6. Histological characteristics of rat skin on day 14 after wound creation in excisional wound model. a -b:nanocomposite , c-d: Gelatin, e-f: control.. Wounds with surrounding skin were prepared for histological microscopic evaluation by H&E staining.

B: Blood vessel, C: collaen, E: Epithelium, F: Fibroblast, I: Inflammatory cells, S: scab.

and differentiation enable almost full recovery of skin tissue and restoration of skin aesthetics. An ideal healing agent should possess specific properties: it should check the infection, accelerate the healing, be favorable for cell proliferation and matrix deposition, cause better re-epithelialization, result in less or no scar formation.^{12,13} The integration of nanotechnology into biology has brought metals like Ag in the form of nanoparticle potential topical antimicrobial agents.¹⁴ Zeolite can be incorporated to wound healing formulations due to its ion-exchange property, apparent satisfactory biocompatibility, and ability to faster wound re-epithelialization and wound size reduction.³ Wound contraction is a dynamic

where cells organize their surrounding tissue matrix to reduce normal healing time by shrinking the amount of extracellular matrix which has to be produced.¹⁵ In many respects, wound contraction is beneficial as it can significantly reduce healing time because less granulation tissue needs to produce to replace tissue loss. In view of above, the measurement of wound contraction is an important tool to ascertain the progress of cutaneous wound healing.¹⁶ In the present study, the wounds treated with nanocomposite were healed almost completely (97%). These data are in agreement with the results of other studies.^{3,17,18}

Zeolite has been found to be effective in decreasing the healing times of wounds and surgical incisions. A method for decreasing wound healing time includes: applying hemostatic agents to the wound, inflaming tissue surrounding the wound to facilitate the deposition of fibroblast, thereby accelerating the subsequent contraction of the wound and the onset of the proliferative healing stage, and causing the re-epithelialization of the tissue at a faster rate than a condition in which no hemostatic agent is applied to the wound. Reportedly, zeolite has efficient hemostatic activity and wound healing property.¹⁹ Wet or moist treatment of wounds has been shown to promote re-epithelialization. Clinical studies suggest that wound fluid from wounds healing under moist conditions stimulates keratinocyte proliferation and fibroblast growth with subsequent preservation of growth factors for wound repair.¹ Gelatin possesses strong hydrophilic activity and prevents fluid loss in the wound area, ultimately leading to the preservation of wound moisture and the creation of a positive effect on re-epithelialization and matrix deposition. Re-epithelialization is an important factor in wound healing, and occurs due to the migration and division of epidermal cells.^{20,21} Complete re-epithelialization of nanocomposite treated rats may be due to zeolite hemostatic, healing property, and the hydrophilic activity of gelatin. Therefore, the higher rate of re-epithelialization in the gelatin treated rats in comparison with those of the control group may be due to its hydrophilic activity.²² On the other hand, complete re-epithelialization of nanocomposite treated rats, with well-developed epidermal and dermal layers and the absence of scab tissue and the presence of rete peg formation in these rats confirmed that they were in the remodeling phase. Fibroblast is a type of cell that synthesizes the extracellular matrix and collagen, the structural framework for tissue, and plays a critical role in wound healing²³. Dermis of the healed area showed abundant collagen fibers that were thicker and more organized. Furthermore, there were abundant fibroblasts in the dermis and good keratinocyte maturation in the epidermis with nanocomposite treated group. The abundant presence of fibroblasts and collagen in

process

Table 2. Results of histomorphometric analysis (mean \pm SD) of Re-epithelialization% and Angiogenesis, collagen, secondary infection scores in the study groups at 14 days post-wounding.

Groups	Re-epithelialization%	Angiogenesis	Collagen	Secondary infection
Nanocomposite	99.33 \pm 1.03 ^a	2.33 \pm 0.51 ^a	3.5 \pm 0.547 ^a	1.67 \pm 0.408 ^a
Gelatin	88.33 \pm 7.12 ^b	2 \pm 0.632 ^b	1.66 \pm 0.51 ^b	2.66 \pm 0.816 ^b
Control	50.33 \pm 6.86 ^c	1.5 \pm 0.54 ^c	1.5 \pm 0.547 ^c	3.00 \pm 0.632 ^b

nanocomposite treated group suggest that Ag might stimulate the migration and proliferation of the fibroblasts^{24,25}. Moreover, collagen synthesis and deposition might have been indirectly enhanced due to an efficient neovascularization in nanocomposite treated rats. Angiogenesis is necessary in wound healing. Furthermore, it is an important factor in the regeneration of skin²⁶. Angiogenic factors can stimulate and accelerate wound healing. Research has shown that angiogenesis is increased in rats on day 7, but after that, apoptosis of unessential blood vessels occurs. This event signals the onset of the remodeling stage of wound healing. Thus, both accelerated and reduced blood vessel growth play important roles in wound healing²⁷. Nanocomposite treated rats showed the highest angiogenesis, and the best overall results. However, insignificant difference in neovascularization between the groups could be due to the onset of remodeling stage of wound healing which is concurrent with blood vessel reduction. All microscopic studies confirmed these results. In conclusion, in the present study, the significant higher wound healing in the nanocomposite treated rats can be attributed to increased neovascularization, fibroblast proliferation, collagen synthesis and better re-epithelialization.

In this study, we successfully prepared Ag⁺-zeolite/gelatin nanocomposite. The prepared nanocomposite showed antibacterial property due to Ag ion-exchanging. It demonstrated high viability on MCF-7 cell lines and marked improvement of wound healing process. Thus, Ag⁺-zeolite/gelatin nanocomposite is an ideal agent for wound healing.

Acknowledgments

We appreciate the staff of the Center of Excellence in Ruminant Abortion and Neonatal Mortality, School of Veterinary Medicine, Ferdowsi University of Mashhad for their technical help

Conflicts of interest

None.

References

1. Heather L.O, David K, Louise F, Marie F. Basic principles of wound healing. *Journal of Wound Care Canada*, 2004;9:1-12.
2. Tocco I, Zavan B, Bassetto F, Vindigni V. Nanotechnology-based therapies for skin wound regeneration. *Journal of Nanomaterials*, 2012;4:7-11
3. Neethu N, Muthunayanan M, Nur A, In-Kyu P, Anne E, Tin W, Sabu T, Yves G. Antibacterial and wound healing analysis of gelatin/zeolite scaffolds. *Journal of Colloids and Surface B: Biointerface*, 2014;115:224-252.
4. grancaric A.M, Tarbuk A, Kovacek I. Nanoparticle of activated natural zeolite on textile for protection and therapy. *Journal of Chemical Engineering Quarterly*, 2009;15:203-210.
5. Ninan N, Muthian m, Park IK, Elain A, Thomas S, Grohens Y. Pectin/carboxymethyl cellulose/microfibrillated cellulose composite scaffolds for tissue engineering. *Journal of Carbohydrate polymer*, 2013;98:877-885.
6. Jayakumar R, Prabakaran M, Kumar P, Nair SV, Tamura H. Biomaterials based on chitin and chitosan in wound dressing applications. *Journal of Biotechnology advances*, 2010;29:322-337.
7. Tianhong D, masamitu T, Huang Y, Hambin M. Chitosan preparation for wounds and burns: antimicrobial and wound-healing effects. *Journal of Expert Review of Anti-infective Therapy*, 2011;9:857-879.
8. Steven I, Sara M. silver and alginates: Role in wound healing and biofilm control. *Journal of Advances in Wound Care (New Rochelle)*, 2015;4(7):407-414.
9. Tanaka A, Nagate T, Matsuda H. Acceleration of wound healing by gelatin film dressings with epidermal growth factor. *Journal of Veterinary Medicine Science*, 2005;67:909-13.
10. wang j, Wang Z, Zhang S, Song Y, Dong X, Wang J. Antibacterial and anti-adhesion zeolite coatings on titanium alloy surface. *Journal of Microporous Mesoporous Materials*, 2011;146:216-222.
11. Breuing K, Andree G, Helo J, Slama P.Y, Liu E. Growth factors in the repair of partial thickness porcine skin wounds. *Journal of Plastic Reconstructive & aesthetic Surgery*, 1997;100:657-664.
12. Joshua S, Matthews KH, Howard N.E, Gillian M. Wound healing dressings and delivery systems: A review. *Journal of pharmaceutical Sciences*, 2008;97:2892-2923.

13. Gong CY, Wu Q, Wang Y, Zhang D, Luo F, Zhao X, wei Y, Qian Z. A biodegradable hydrogel system containing curcumin encapsulated in micelles for cutaneous wound healing. *Journal of Biomaterials*,2013;34:6377-6387.
14. Abbasalipour M, Mirjalili M, Khajavi R, Majidi M. Coated cotton gauze with Ag/ZnO/chitosan nanocomposite as a modern wound dressing. *Journal of Engineered Fibers and Fabrics*, 2014;9:124-130.
15. El-refaie W, Elnarggar Y, El-Massik M, Abdallah O. Novel curcumin-loaded gel-core hyalurosomes with promising burn-wound healing potential:Development, in-vitro appraisal and in-vivo studies. *International Journal of pharmaceutids*, 2015;486:88-98.
16. Young A, Mcnaught C. The physiology of wound healing. *Journal of Surgery*,2011;29:475-79.
17. Gopal A, Kant V, Gopalakrishnan A, Tandan S, Kumar D. Chitosan-based copper nanocomposite accelerates healing in excision wound model in rats. *European Journal of Pharmacology*, 2104;731:8-19 .
18. Archana D, Sigh b, Dutta J, Dutta P.K. Chitosan-PVP-nanosilver oxide wound dressing: In vitro and in vivo evaluation. *International Journal of Biological macromolecules* ,2015;73:49-57.
19. Jiang L, Yan W, Xueyong L, Yuejun L, Wangzhon L, Shoozong C. Addition of an alginate to a modified zeolite improves hemostatic performance in a swine model of lethal groin injury. *Journal of Trauma Injury, Infection and Critical Care*, 2009;66:612-620.
20. Cutting K, Rogers AA, Rippon M. The importance of hydration in wound healing : re invigorating the clinical perspective. *Journal of wound care*, 2016; 25:122-124
21. Kang B, Cheon Y, Jin Y. Comparision of the wound healing effect of cellulose and gelatin: An in vivo study. *Journal of Archives of Plastic Surgery*, 2012;39:317-322.
22. Bum Sik Kang, Young Cheon Na, Young Wan Jin.Comparision of the wound healing effect of cellulose and gelatin:An in vivo study. *Journal of Archives of Plastic Surgery*, 2012;39: 317-22.
23. Bainbrifge P. Wound healing and the role of fibroblasts. *Journal of wound care*, 2013;22:407-412.
24. Naraginti S, Kumari P, Das R, Sivakumar A, Patil S, Andhalkar V. Amelioration of excision wounds by topical application of green synthesized, formation silver and gold nanoparticles in albino wistar rats. *Journal of Materials Science and Engineering*,2016;c62:293-300.
25. Archana D, Singh B, Dutta J, Dutta P.K. Chitosan-PVP-Nano silver oxide wound dressing: In vitro and in vivo evaluation. *International Journal of Biological Macromolecules*, 2015;73:49-57.
26. Krauza A, Alder B, Cabral V, Navati M, Doerner J, Charafeddine R, Chandra D, Liang H, Gunther L, Clendaniel A, Harper S, Friedman J, Nosanchuk J, Friedman A. Curcumin-encapsulated nanoparticles as innovative antimicrobial and wound healing agent. *Journal of Nanomedicine:Nanotechnology, Biology and Medicine*, 2015; 11:195-206.
27. Sabine A Eming , bent Brachvogel , Tresa Odorisio, Manuel Koch. Regulation of angiogenesis: Wound healijng as a model. *Journal of Progress in histochemistry and cytochemistry*, 2007;42:115-170

چکیده

ارزیابی اثرات نانوکامپوزیت زئولیت-نقره/ژلاتین برالتیام زخم اکسیژنال رت

سارا جوانمردی^{۱*}، بهارک دیوبند^۲

^۱گروه علوم درمانگاهی، دانشکده دامپزشکی، دانشگاه تبریز، تبریز، ایران
^۲گروه شیمی غیر آلی، دانشکده شیمی، دانشگاه تبریز، تبریز، ایران

هدف- مطالعه ارزیابی اثرات التیامی نانوکامپوزیت زئولیت-نقره/ژلاتین برالتیام زخم برداشتی پوست در مدل حیوانی رت بود.

طرح- مطالعه تجربی

حیوانات- ۱۸ سر رت نژاد اسپاراگو با وزن ۲۲۰-۲۰۰ گرم

روش کار- نانوکامپوزیت زئولیت-نقره/ژلاتین با روش سل-ژل تهیه شده با استفاده از روشهای XRD و SEM شناسایی شد. تست سمیت سلولی (MTT assay) و انتی باکتریایی نانوکامپوزیت تهیه شده انجام گرفت. تحت بیپوشی عمومی زخم تمام ضخامت به ابعاد ۱.۵×۱.۵ cm در ناحیه پشتی رتها ایجاد شد. حیوانات بصورت تصادفی و مساوی به سه گروه ۶ تایی: گروه ۱ (کنترل، نرمال سالین) گروه ۲ (ژلاتین) و گروه ۳ (نانوکامپوزیت زئولیت-نقره/ژلاتین) تقسیم شدند. درمانهای هر گروه بصورت موضعی روزانه یکبار تا ۱۴ روز روی زخم قرار می گرفتند. در روزهای صفر، ۳، ۴، ۶، ۹، ۱۲ و ۱۴ از محل زخم ها عکس برداری شده و انقباض زخم آنها محاسبه می شد. در روز ۱۴ حیوانات به روش انسانی قربانی شده و نمونه های پوستی جهت ارزیابی هیستوپاتولوژیک (رنگ آمیزی هماتوکسیلین-ائوزین) برداشته شدند.

نتایج- در این مطالعه نانوکامپوزیت زئولیت-نقره/ژلاتین با موفقیت تهیه شد. نانوکامپوزیت تهیه شده به دلیل معاوضه یون نقره خصوصت انتی باکتریال نشان داد. بررسی سمیت نانوکامپوزیت نشان داد که تا غلظت ۱ mL/mg سمیت ندارد. در گروه درمان شده با نانوکامپوزیت انقباض چشمگیر زخم و تسریع زمان التیام مشهود بود. ($p < 0.05$) علاوه گروه درمان شده با نانوکامپوزیت در مقایسه با بقیه گروههای مطالعه سنتر بیشتر کلاژن، رگ زایی بیشتر، تسریع اپیتلیزاسیون در محل التیام را نشان داد.

نتیجه گیری و کاربرد بالینی - نانوکامپوزیت زئولیت-نقره/ژلاتین زیست سازگار میتواند بصورت گسترده در التیام زخم های باز و تمام ضخامت کاربرد داشته باشد.

کلمات کلیدی - نانوکامپوزیت، زئولیت-نقره/ژلاتین، زخم برداشتی، رت