

Three Dimensional Ultrasonography of the Eye and Measurement of Optical Nerve Sheet Diameter in Dog

Dariush Vosough¹ DVM
Majid Masoudifard^{*2} DVSc
Abbas Veshkini² PhD
Ali Reza Vajhi² DVSc
Sarang Sorouri² DVSc

*¹Department of Clinical Sciences, Faculty of Veterinary Medicine,
Shahid Bahonar University of Kerman, Kerman, Iran.*

*²Department of Clinical Sciences, Faculty of Veterinary Medicine,
Tehran University, Tehran, Iran.*

Abstract

Objective- To determine the possibility of three-dimensional ultrasonography (3DUS) and measurement of optical nerve sheet by this method.

Design- Descriptive study.

Animals- 10 mixed normal dogs (5males, 5 females), age 1-1.5 year, and weighting 15±5 kg

Procedure- 3D ultrasounds of the eyes were evaluated and the normal optical nerves in 3DUS images were measured using Volouson 730 pro.

Results- In the obtained 3D images vitreous body, anterior chamber, and lens cortex and nucleus showed a distinct anechogenic to hypoechogenic. Details of the eyes compartments were better observed by rotating the images in all possible angles and planes using 3D facilities. Anterior and posterior lens capsule and the optic disk were hyperechogenic. The mean optical nerve in males was: 3.85 mm and in females it was 3.86mm. There weren't a significant difference between ocular nerve measurements of male and female dogs and left and right eyes.

Conclusion and Clinical Relevance- The 3DUS gives useful images for teaching and diagnostic purpose and Lesions of the caudal portion of the orbit (e.g. optic nerve atrophy) are better visualized by this technique. The results of the eye 3DU in dogs showed marked advantages in image acquisition for interpretation of all aspects of the ocular structures. Measurement of the optic nerve by 3D ultrasonography and other methods such as CT scan and direct measurement did not have any significant difference.

Key words- Three-Dimensional Ultrasonography, dog, Eye, Optical nerve

*** Corresponding author:**

Majid Masoudifard DVSc

Department of clinical Sciences, Faculty of Veterinary Medicine, Tehran University, Tehran, Iran

E-mail address: mfard@ut.ac.ir

Introduction

In veterinary ophthalmology, B-scan ultrasound provides a two-dimensional real-time image and is the most common mode of ultrasound in a clinical setting. In the last 10 years three-dimensional ultrasonography (3DU) has been increasingly used as a diagnostic tool in human medicine 1, 2 but not common in veterinary practice yet. Ultrasonography seems to have many applications for diagnosing of ocular diseases according to anatomical structure of the eye which is a small superficial and available organ, also because of the special echo texture of aqueous humor and vitreous humor, and anatomical location of the canine eye which is easy to put the transducer on 2.

There are some studies about usefulness of 3DU for clinical diagnosis in human 3,4. Presence of small disorders, hypema, foreign bodies, and tumors are plain to investigate by 3D ultrasonography. This is probably due to possibility of different angle scanning which provide favorite images for the clinician 4. In two-dimensional ultrasound (2DU), the caudal ocular disorders may not be visible because of the wrong probe positioning and angle. The size and distribution of the tumors are better visible in 3DU especially in the caudal region of the orbit 5. If a local retinal detachment has not been seen in 2D examination it is much easier to be found by 3DU. Also 3DU of the eye can make better determination of choosing surgical treatment for the tumors which are placed in the caudal orbit region.

The purpose of this study was to evaluate the possibility of taking 3D ultrasound images for better visualization of canine eye and also measurement of the optical nerve by using this technique.

Materials and Methods

A total of 10 (5 males and 5 females) healthy dogs Aged 1.5-2 years old with no evidence of ocular disease were selected. GE Voluson 730-Pro ultrasound equipment with "3D small parts" option of a 5-12 MHz, linear trapezoid of 3D - 4D transducer was applied for all the examinations. All of the cases were sedated and Tetracain HCl 0.05% drop was used for relatively prevention of the eye movement. Transpalpebral method and liberal amounts of acoustic gel directly to the eyelid were applied for scanning of the eye 6,7. At the first, 2D images of the eye were obtained and after exact tracing of the ocular structures, 3DU image acquisition was performed as a volume of data with nearly immediate reconstruction and simultaneous display of sectional anatomy in three orthogonal planes (longitude plane, transverse or horizontal plane) or any arbitrary oblique plane and also finally a 360 degree rotating 3D plane. Multi-planar image analysis, freely adjustable planes within the volume, three-dimensional reconstruction and rotating 3D animation were all saved for farther essay. Finally the ultrasonography measurements of the optic nerve sheet were carried out a constant position located 5mm behind the optic disk in males and females, left and right eyes. All the obtained data were analyzed by paired sample T-test statistically.

Results

The 3D ultrasonography method was found to be a valuable technique for canine ophthalmic evaluations. All of the ocular structure at different planes could be finely displayed and analyzed. In the obtained 3D images, vitreous body, anterior chamber and lens cortex and nucleus showed distinct anecho to hypoechogenicity. Details of the different eye compartments were better observed by acquisition of the images in all possible planes (fig.1).

By using different probe angle, it was easily possible to detect different scans of complete lens, cornea, and iris and ciliary body and optic disc. However, it was easier to see all, longitudinal, Horezontal and Transverse planes by changing the position of the cursor presents on the monitor into the favorite plane (fig.1). The 3DU image acquisition required less than 10 seconds using this advanced ultrasound machine. Finally a 3D rotating animation of the ocular structures at desired angle could be reconstructed for better visualization and recognition of different parts of the eye (fig.2). The values of the optical nerve in obtained 3D images, which were measured (fig.3) and shown (table 1). There wasn't any significant difference ($p<0.05$) between ocular nerve measurements of male and female dogs and between left and right eye.

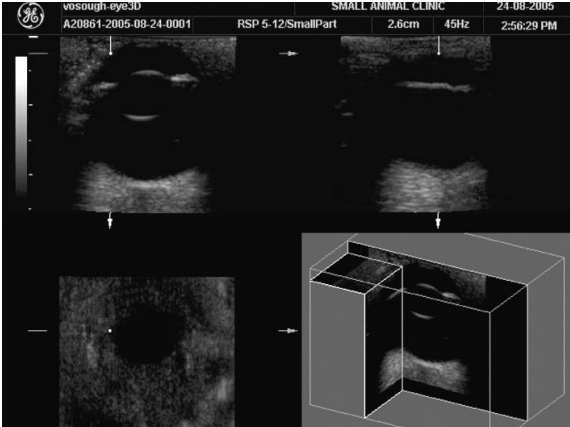


Fig.1: 3D image of the eye which has the potential of demonstrating all the plans by changing the cursor on the voluntary point.

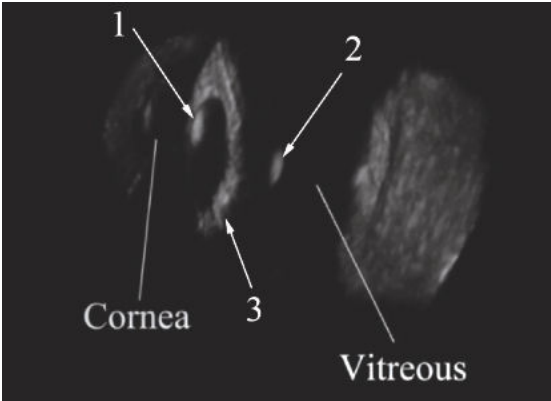


Fig.2: The reconstructed 3D, final, rotating image of the eye; 1: anterior capsule, 2: posterior capsule, 3: ciliary body.

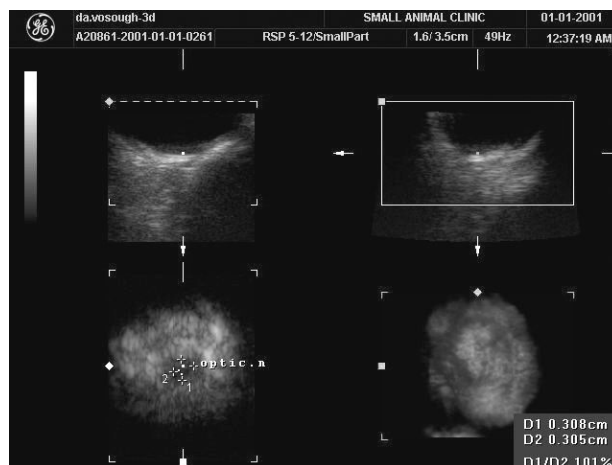


Fig.3: 3DUS images of the optic nerve sheet measurement using eyelid technique in Horizontal plan.

Table1: Measurements of right and left eye optic nerve in female and male dogs

Case No.	Sex	Right eye	Left eye
		Optic nerve (mm)	Optic nerve (mm)
1	M	3.88	3.87
2	M	3.94	3.92
3	M	3.92	4.00
4	M	3.74	3.78
5	M	3.78	3.77
6	F	3.85	4.08
7	F	3.79	3.77
8	F	4.06	3.85
9	F	3.85	4.08
10	F	3.90	3.89

Discussion

Different scanning methods could be applied for 3D data acquisition however, the length of the scanning time is very important, because the movements of the eyeball, the probe, or the animal body during scanning will cause distortion of the final image. So motionless patients and unmoved hand of the clinician are essential to take clear images. In our cases, the 3D data acquisition time required 5-10 seconds depending on the selected 3D box size of the interested region and also the desired image quality. It was so fast that a real-time 4D reconstruction could be performed too. In general, advanced ultrasound machine is necessary for this purpose. We also reduced the eyeball movements by using Tetracain HCl drop. Some medical researches have found out the usefulness of 3D ultrasonography in investigation of different disorders. Choroids melanomas have been diagnosed described and measured by this technique. Finger detected a retinoblastoma and its distribution in the eye in all 3D views. Gabor showed extension of retinal detachment, foreign body, on 18 eyes. 3DUS measurement of the optical nerve by eyelid technique were carried out at a constant position located 5mm behind the optic disc to improve ultrasound sensevity, resolution and reproducibility . Measurement of the optic nerve by 3D ultrasonography and other methods such as CT scan and direct measurement did not have any significant difference. 8, 9 Julian have measured the

size of the optic nerve and compared the obtained data with CT scan which showed the more accuracy of 3D ultrasonography 10.

References

1. Downey DB, Nicolle DA, Levin MF. Three dimensional ultrasound imaging of the eye. *Eye*. 1996; 10:75-81.
2. Janos N. Three dimensional ultrasonography of the eyeball and orbit. *Ophthalmology*. 1997; 34:84-88.
3. Finger PT. Three dimensional ultrasonography of retinoblastoma: initial experience. *Ophthalmology* 2002; 86:1136-1138.
4. Finger PT, Romero JM. Three dimensional ultrasonography of choroidal melanoma. *Arch Ophthalmol* 1998; 116:305-312.
5. Romero JM, Finger PT. Three dimensional ultrasonography of measurement of choroidal melanoma. *Am J Ophthalmol* 1998; 126:842-846.
6. Nyland TG, Matton JS. *Small animal diagnostic ultrasound*. 2nd ed. Philadelphia: W.B.Saunders Co., 2002; 306-322.
7. Kealy JK, Mcallister H. *Diagnostic Radiology and Ultrasound of the dog and cat*. 3rd ed. W.B.Saunders Co., 2000; 377-378.
8. Schiffer SP, Rantanen NW, Leary GA. Biometric study of the canine eye, using A-mode ultrasonography. *J Vet Res* 1982;43:826-83.
9. Jung H, Lee H. Ultrasonography measurement of optic nerve sheet diameter in normal dog by 2DU. *J Vet Sci* 2003;4:265-268
10. Julian PS, Garcia Jr. Optic nerve measurement by 3D ultrasonography. *Arch Ophthalmol* 2001;24:102-105.

بررسی اولتراسونوگرافی سه بعدی و اندازه گیری غلاف عصب بینایی در چشم سگ

دکتر داریوش وثوق^۱، دکتر مجید مسعودی فرد^۲، دکتر عباس وشگینی^۲، دکتر علیرضا وجهی^۲، دکتر سارنگ سروری^۲

۱ گروه علوم درمانگاهی دانشکده دامپزشکی، دانشگاه شهید باهنر کرمان، کرمان، ایران.
۲ گروه آموزشی علوم درمانگاهی، دانشکده دامپزشکی دانشگاه تهران، تهران، ایران.

هدف: برای تهیه مدل سه بعدی از چشم سگ توسط التراسونوگرافی سه بعدی برای استفاده در تشخیص بیماری های چشم و همچنین بدست آوردن قطر عصب بینایی در سگ در این تکنیک.

طرح: مطالعه توصیفی

حیوانات: ده سگ نژاد مخلوط (۵ نر و ۵ ماده) و سن ۱/۵-۱ سال و وزن متوسط ۲۰-۱۵ کیلوگرم

روش کار: چشم سگ ها تحت بررسی التراسونوگرافی سه بعدی توسط دستگاه التراسونوگرافی ولوسان ۷۳۰ پرو قرار گرفت و اندازه قطر غلاف عصب بینایی اندازه گیری شد.

نتایج: در این تکنیک مشخص شد که تمامی قسمتهای چشم قابل ارزیابی است. اطرافک قدامی و جسم زجاجیه و کورتکس عدسی به شکل هیپو اکو و ان اکو و دیسک بینایی و کپسول قدامی و خلفی عدسی به شکل هیپراکو خود را نشان میدهد. با توجه به اینکه تصاویر سه بعدی چشم در پلنهای مختلف تهیه می گردد میتواند تمامی قسمتهای چشم را مشخص نماید. همچنین در این تحقیق قطر عصب بینایی به طور متوسط چهار میلیمتر اندازه گیری شد و تفاوت معنی داری در جنس نر و ماده وجود نداشت.

نتیجه گیری: التراسونوگرافی سه بعدی برای استفاده در تشخیص تومورها در چشم و دیگر موارد تشخیصی و درمانی می تواند استفاده شود و همچنین توسط این تکنیک قسمتهای خلفی و پشت کره چشم و به خصوص عصب بینایی قابل بررسی و تشخیص می باشد. در اولترا سونوگرافی سه بعدی اندازه قطر عصب بینایی با دیگر متدها همانند سی تی اسکن و اندازه گیری مستقیم برابری می کند.

کلید واژگان: اولتراسونوگرافی سه بعدی، سگ، چشم، عصب بینایی