

Topical Application of Natural Urmia Honey on Experimental Burn Wounds in the Dog: Clinical and Microbiological Studies

Farnood Shokouhi Sabet Jalali ^{*1} DVSc
Hossein Tajik² DVSc
Siamak Saifzadeh¹ DVSc
Bakhtiar Fartash³ DVM

¹Departments of Clinical Sciences and ²Department of Food Hygiene,
Faculty of Veterinary Medicine, Urmia University, Urmia, Iran.

³Graduated from the Faculty of Veterinary Medicine, Urmia University, Urmia, Iran.

Abstract

Objective- Numerous reports documented the efficacy of honey in wounds healing, and several studies indicated that honey appears to be better than some modern methods of treatment. Medical and therapeutic properties of honey have been showed to be related to physicochemical and nature of component of it. The exact composition of natural honey depends on the region, mainly the botanicals; from where, they are derived. This study was designed to evaluate the effects of natural Urmia honey on burn wound healing.

Design- Prospective descriptive trial.

Animals- Ten adult mongrel dogs, 4 to 5 years old, with mean weight of 20 ± 4.25 Kg.

Procedures- Burn wounds were created in dorso-lateral region of each dog, according to Hoekstra model. In treatment group (n=5), wounds were covered with a thin layer (10 ml) of natural honey. In control group (n=5); wounds were only washed with the same amount of normal saline. Wound healing was assessed clinically and microbiologically on 1, 7, 14 and 21 days of the experiment.

Results- Wounds treated with honey had more improved healing appearance in comparison with the control wounds. Results showed that wounds of honey group healed faster than the other group ($P < 0.05$). Also total bacterial count were lower in former group than the later one ($P < 0.05$).

Conclusions and Clinical Relevance: According to the results of this study, topical application of natural honey has beneficial effect on experimental burn wound from clinical and microbiological points of view. Honey can be considered as a low cost, easily available and potent topical agent in treatment of burn wounds.

Key words: Topical, honey, burn, wound, microbiology, dog

*Corresponding Author:

Farnood Shokouhi Sabet Jalali

Departments of Clinical Sciences, Faculty of Veterinary Medicine, Urmia University, Urmia, Iran.

e-mail: f.shokouhi@mail.urmia.ac.ir

Introduction

Annually, thousands of people suffer from different kinds of burn wounds, throughout the world. Modern life and technology expose people more to the burn accidents¹.

Researches show that the most frequent reason (over 50%) of death resulting from burn is infection². Burns become infected because the wound area is an ideal medium for the multiplication of the infecting organisms. There is a plentiful supply of moisture, nutrients and ideal physical environment (temperature, gaseous requirements, etc.); for growth of microorganisms.

Burn wounds are often protected against infection with temporary covering with xenografts or preserved homografts. These are not easily available and too costly to be used in developing countries. In these countries, most burn units perform early debridement of the wound to encourage healing and covering the burn wound with a routine dressing³. During the past years, the prevalence of certain pathogens causing wound infection has decreased due to improvements in wound management techniques^{4,5}. In spite of it, a small number of burn units still use prophylactic antibiotics to prevent wound infection because of concerns regarding the high incidence of antibiotic resistance, high cost and the risk of adverse drug effects⁶.

Increasingly, bacteria are becoming multi-antibiotic resistant, for example methicillin resistant *Staphylococcus aureus* (MRSA) is now the major cause of infections in burn wounds in Europe⁷. Although, new antibiotics are still being produced, we need some new strategies for treatment of burn wounds infections.

The current progress made in the analytical studies and in the field of biotechnology has led to a renewed interest in pharmacotherapy based on biogenic components. More attention has been given to apipharmacotherapy which utilizes the antibacterial properties of active fractions of bee products.

Honey has been used as a wound treatment agent for more than 2000 years⁸. Honey inhibits the growth of gram-positive and gram-negative organisms⁹ and promotes epithelialization and helps the healing of the burn wounds^{10,11,12}.

Antimicrobial activity of honey is thought to be the result of its physicochemical properties and phytochemical agents. The exact composition of natural honey depends on the region, mainly the botanicals, from where they are derived.

Because of a continuing need to a topical agent for wound treatment which is less expensive, easily available and effective in preventing infection, decreasing fluid loss and enhancing re-epithelialization, we designed this experimental study in order to assess the clinical and antimicrobial effects of topically applied natural Urmia honey on burn wounds.

Materials and Methods

Honey samples used in this study were harvested during spring 2005, from Targavar Bee Keeping Corporations, Urmia. Each sample was first filtered with a sterile mesh to remove debris and stored at 2-8 °C until used. The average composition of the honey is given in table 1.

Ten apparently healthy adult mongrel dogs of both sexes, 4.5 ± 0.5 years old and with mean weight of 20 ± 4.25 Kg, were used in this study. Dogs were considered to be healthy on the basis of physical and laboratory examination including CBC and serum biochemistry results. The animals were kept in individual cages and had access to water and food *ad libitum*. The experimental protocol was approved by the Veterinary Clinical Sciences Committee at Urmia

University. The animals were randomly assigned to two experimental (n = 5) or control (n = 5) groups. Dogs were premedicated with atropine (Darou Pakhsh, Tehran, Iran) (0.04 mg/kg, intramuscularly [IM]) and acepromazine (Darou Pakhsh, Tehran, Iran) (0.1 mg/kg, IM). Anesthesia was induced with sodium thiopental (Biochemie GmbH, Vienna, Austria) (10 mg/kg, 2.5% intravenously) and maintained with halothane after endotracheal intubation. Dogs were positioned in ventral recumbency and the dorso-lateral back area was shaved just behind the shoulders, followed by skin preparation for aseptic surgery.

Table 1: Average composition of Targevar honey

Average (%)	Component
70.38	Reductant sugars
2.12	Sucrose
0.93	Fructose/Glucose
+	Diastase
-	Commercial glucose
0.05	Mineral components
15.08	Moisture
82.92	Concentration
12.5	Total acid
3.96	pH

The rectangular-shaped wounds ($2 \times 3 \text{ cm}^2$) were created with hot (180C°) brass brick (College of Engineering, Urmia University, Urmia, Iran) weighting 500 g and applied for 10 seconds. The model of the burn wound was prepared according to Hoekstra standard¹³.

In the experimental group, 10 ml pure, unprocessed, and undiluted honey was applied once daily to the surface of the burn. In the control group, the wounds were treated with normal saline, applied once daily. All the wounds were bandaged with a non-adhesive dressing, held in place with an elastic wrap.

The wounds were observed for evidence of infection, excessive exudates or leakage until the wound healed. Time elapsed for wound healing was considered in both groups. Clinical and microbiological [quantitative (total plate count) and qualitative (using specialized microbial medias)] examinations of the burn wounds were done on 0, 7, 14 and 21 days of the experiment.

Neither prophylactic nor postoperative antibiotic therapy was done. Tramadol (KRKA, d. d., Novomesto, Slovenia) (0.2 mg/kg, IM) was administered every 3 hours after surgery for 24 hours and as needed thereafter to control pain and discomfort.

The wounds were photographed on days 0, 7, 14, and 21. All the photographs were scanned and wound areas were measured using digital scanning software (Sigma Scans Pro 5.0, SPSS Science, Chicago, IL).

The analyzed variable included the rates of wound contraction (percent decrease of wound area) (wound area on day 0 minus wound area on day n, divided by the wound area on day 0 expressed as a percentage).

The results of total bacterial count and time taken for healing were analyzed with an unpaired Student's *t* test. Differences were considered significant if $p < 0.05$ (SigmaStat for Windows, version 2.03, Jandel Corporation, San Rafael, CA).

Results

During the days after the experiment, the animals showed a normal reaction to the environment and revealed no symptoms of suffering due to burn wounds. Wound healing was uneventful during the experimental period. The rates of wound contraction (percent decrease of wound area) in experiment and control wounds are shown in Table 2.

In both groups clinical signs were similar in first and second days and no difference in appearance of wound was noted between the treatment and control wounds. Surrounding skin showed inflammation and large quantity of exudation. Necrotic changes and scald were noted in central part of the wounds.

On day seven, crust covered the surfaces of wounds in treatment group. Under the crust, scar could be seen and re-epithelialization was developed at wound edges. At the same time, the surrounding skin of the control wounds was cracked, reddened and swollen. Some wounds were dried and coated with crusts. On day 14, wounds of treatment group were covered with scar and considerably reduced in size. The appearances of the wounds showed progression of healing. In other group, though the crusts came off from edges of wound, they were still adhered to the surface of the wounds and the surfaces of the wounds were not decreased. On day 21, the wounds of treatment group were approximately closed but in control group, crusts came off from the surface of the wounds. The wound area of was still not diminished.

In the microbiological examination of the skin before commencement of the study, *Escherichia coli*, *Staphylococcus aureus*, *Streptococcus pyogenes* and *Candida albicans* strains were isolated. At the end of the study, the number of all the strains on the skin was $9 \pm 0.5 \times 10^5 / \text{cm}^2$ in the treatment and $2 \pm 0.6 \times 10^4 / \text{cm}^2$ in control group. In honey-treated group, the growth of *Staphylococcus aureus* and *Escherichia coli* were observed in the first day. Also, on days 3, 7 and 14, these microorganisms were isolated, but on day 21 just *S. aureus* was isolated.

In the control group, after the first 24 h of the experiment, *Escherichia coli*, *Staphylococcus aureus*, *Streptococcus pyogenes* and *Candida albicans* were isolated. These species were also isolated on days 3 and 7 of the experiment. On day 14, *Streptococcus pyogenes* and *Candida albicans* were not observed. On day 21, only *Staph aureus* was isolated.

At the same time quantitative examinations of the bacterial flora were conducted in the burn wounds. In the control group, the number of microorganisms existing on 1 cm^2 of the wound in the first day, were $3 \pm 0.8 \times 10^4 / \text{cm}^2$ and gradually increased during the following days to the value of $7 \pm 0.6 \times 10^5$ on day 7. In the 14th day the number of microbes imperceptibly decreased until day 21, when reached to $3 \pm 0.5 \times 10^5 / \text{cm}^2$.

In the honey group, the number of microbes were $5 \pm 0.6 \times 10^5 / \text{cm}^2$ in the first 24 h of the experiment. On the 7th day of the experiment this number was unchanged; however, on day 14 it decreased significantly to the value of $2 \pm 0.5 \times 10^5 / \text{cm}^2$. This value decreased significantly on the 21st day, and reached to the $3 \pm 0.5 \times 10^4 / \text{cm}^2$.

Results of microbiological examinations are shown in Fig. 1.

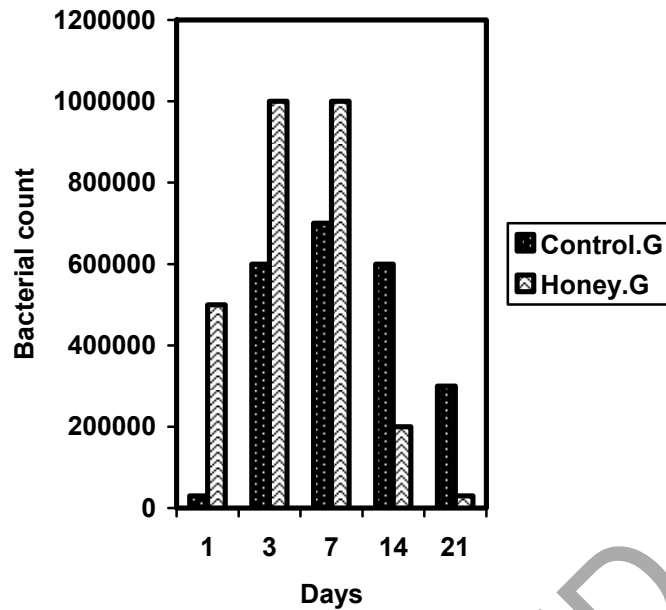


Fig. 1: Results of quantitative microbiological examinations.

Table 2: Comparison of wound area (mm²)(mean±SD) and percent decrease in the experiment and control wounds (n=5dogs)

Day	0	7	14	21
Experiment	688.6±42.22	364.4±16.26* (47.08%)	62.24±24.44* (90.97%)	10.64±8.64* (98.46%)
Control	644.8±64.86	486.6±44.82 (24.54%)	206.86±48.26 (67.92%)	89.58±12.84 (86.11%)

*Significant difference (P<0.05)

Discussion

The purpose of this study was to highlight the beneficial effects of honey in treatment of the burn wounds. Some researchers found that honey possesses antibacterial activity where current antibacterial substances were ineffective^{14, 15, 16}. The therapeutic efficiency of apitherapeutics, that pharmacological activity of which, results from physicochemical properties of honey or propolis, have been confirmed in clinical research by Molan¹⁷. In 1998 Efem used honey in the treatment of wounds and ulcerations in 59 patients where conventional methods of therapy did not bring awaited effects. When honey was applied, wounds, formerly infected, became sterile after about a week¹⁸. In another study the possible therapeutic effect of topical crude undiluted honey in the treatment of severe acute postoperative wound infection (50 patients having caesarean sections or total abdominal hysterectomies) was studied. Complete wound healing was evident after 10.73±2.5 days in honey treated group and after 22.04±7.33 days in control group (p<0.05)¹⁹.

The results in Table 2 show that the decrease in wound area was significantly greater from day 7 on, in the experiment wounds compared with the control (P<0.05). Furthermore, though the contraction was steadily in progress in both groups, the rate of contraction (percent decrease of wound area) was obviously greater in the experiment wounds.

In our study, the wounds treated with honey were approximately completely closed (98.46%) on day 21st, compared with the control group (86.11%).

There have been seven randomized trials on application of honey in treatment of burn wound. From these studies six were performed in India by the same researcher and one in United Arab Emirates^{20, 16, 12, 21, 22}. Two of the studies involved superficial burns¹⁶, three partial thickness burns^{16, 12, 21}, one moderate to severe burns that included full thickness injury²² and one infected postoperative wounds¹⁶. The results of these studies revealed the promising effect of honey on wound healing and diminishing the infection rate²³.

According to the results of our experiment, on the 21st day the total number of isolated microorganisms in treatment group was less ($3 \pm 0.5 \times 10^4$) than control wounds ($3 \pm 0.5 \times 10^5$) ($P < 0.05$).

In an experimental report, the common pathogens isolated from burn wounds were *Staphylococcus aureus*, *Pseudomonas aeruginosa*, *Streptococcus pyogenes*, various coliform bacilli, streptococci and anaerobic organisms⁴. Similar organisms were isolated from burn wounds of our experiment, with exception of *Pseudomonas aeruginosa*.

Antimicrobial activity of honey is thought to be due to physicochemical properties (high content of reducing sugars, high viscosity, high osmotic pressure, low pH, low water activity (a_w), low protein content) and hydrogen peroxide^{24, 25, 26, 27, 28, 29}.

These properties are thought to be due to non-specific mechanisms (physicochemical and peroxidial properties), which is more similar to the disinfectants rather than the antibiotics. Thus it can be assumed that honey should possess broad-spectrum antimicrobial potency and may provoke slight microbial resistance.

Researches working on honey, show that pure honey is bactericidal for many pathogenic organisms, including various gram-negative and gram-positive bacteria^{30, 31, 32, 33}.

This experimental study shows that the use of topical honey in treatment of burn not only accelerates the healing procedure but has valuable antimicrobial effect in promoting the recovery of this kind of wounds. Honey can be considered as a low price, easily available and potent topical agent in preventing wounds infection.

It is supposed that further researches on pharmacological activity of honey will reveal their antimicrobial mechanisms and its pro healing activities.

References

- 1- Subrahmanyam M. A prospective randomized clinical and histological study of superficial burn wound healing with honey and silver sulfadiazine. *Burn* 1998;24:157-161
- 2- Artz CP, Reiss ER. *The treatment of burns*. Philadelphia:WB Saunders Co,1975;128-9.
- 3- Herndon DN, Barrow RE, Rutan RL, Desai MH, et al. A comparison
- 4- of conservative versus early excision; therapies in severely burned patients. *Ann Surg* 1989;209:547-53.
- 5- Lawrence JC. Burn bacteriology during the last 50 years. *Burns* 1994;18(Suppl 2): 23-9.
- 6- Monafó WM, West MA. Current treatment recommendations for topical burn therapy. *Drugs* 1990;40:364-73.
- 7- Edwards-Jones V, Dawson MM, Childs CA. Survey into TSS in UK Burns Units. *Burns* 2000;26:323-33.

- 8- Voss A, Milatovic D, Wallrauch-Schwarz C, et al. Methicillin-resistant *Staphylococcus aureus* in Europe. *Eur J Clin Microbiol Infect Dis* 1994;13:50-5.
- 9- Mathews KA, Binning AG. wound management using honey. *Compend Con Edu* 2002; 24:53-59
- 10- White JW, Subers MH, Schepartz AI. The identification of inhibine , the antibacterial factor in honey ,as hydrogen peroxide and its origin in a honey glucose-oxidase system. *Biochem Biophys Acta* 1963;73:57-70
- 11- Postmes T, van den Bogaard AE, Hazen M. Honey for wounds, ulcers, and skin graft. preservation. *Lancet* 1993;341:756-757.
- 12- Subrahmanyam M. Honey impregnated gauze versus polyurethane film (OpSite®) in the treatment of burns - a prospective randomised study. *British J Plastic Surg* 1993;46:322-323.
- 13- Subrahmanyam M. Honey-impregnated gauze versus amniotic membrane in the treatment of burns. *Burns* 1994;20:331-333.
- 14- Brans A, Dutrieux D, Hoekstra MJ. Histopathological evaluation of scalds and contact burns in the pig model. *Burns* 1994;20:548-551.
- 15- Al-Somal N, Coley KE, Molan PC, et al. Susceptibility of helicobacter pylori to the antibacterial activity of manuka honey. *J Royal Soc Med* 1994;87:9-12.
- 16- Efem SEE. Recent advances in the management of Fournier's gangrene: Preliminary observations. *Surg* 1993;113: 200-204.
- 17- Subrahmanyam M. Topical application of honey in treatment of burns. *Br J Surg* 1991;78:497-498.
- 18- Molan PC. Potential of honey in the treatment of wound and burns. *Am J Clin Dermatol* 2001;2:13-19.
- 19- Efem SEE. Clinical observations on the wound healing properties of honey. *Burns* 1998;75:679-681.
- 20- Al-Waili NS, Saloom KY. Effects of topical honey on postoperative wound infection due to gram positive and gram negative bacteria following ceasarean sections and hysterectomies. *Eur J Med Res* 1999;4:126-30.
- 21- Adesunkanmi K, Oyelami OA. The pattern and outcome of burn injuries at Wesley Guild Hospital, Ilesha, Nigeria: a review of 156 cases. *J Trop Med Hyg* 1994; 97:108-112.
- 22- Subrahmanyam M. Honey dressing versus boiled potato peel in the treatment of burns: a prospective randomized study. *Burns* 1996;22:491-3.
- 23- Subrahmanyam M. Early tangential excision and skin grafting of moderate burns is superior to honey dressing:a prospective randomized trial. *Burns* 1999;25:729-31.
- 24- Moore OA, Smith LA, Campbell F, et al. Systematic review of the use of honey as a wound dressing. *BMC Compl Altern Med* 2001;1-2.
- 25- Bergman A, Yanai J, Weiss J, et al. Acceleration of wound healing by topical application of honey. An animal model. *Am J Surg* 1983;145:374-376.
- 26- Hyslop PA, Hinshaw DE , Scraufstatter IU. Hydrogen peroxide as a potent bacteriostatic antibiotic :Implications for host defense. *Free Radic Biol Med* 1995; 19(11) : 31-37
- 27- Molan PC, Cooper RA. Honey and suger as a dressing for wounds and ulcers. *Trop Doct* 2000;30:249-251.
- 28- Oka H, Ihai Y, Kawamura N, et al. Improvement of chemical analysis of antibiotics: Simultaneous analysis of seven tetracyclines in honey. *J Chromatogr* 1987;400:253-61

- 29- Radwan SS, El-Essawy AA, Sarhan MM. Experimental evidence for the occurrence in honey of specific substances active against micro-organisms. *Zentr Mikrobiol* 1984;139:249-255.
- 30- Snowden JA, Cliver DO. Microorganisms in honey. *Int J Food Microbiol* 1996;31:1-26.
- 31- Al-Jabri AA, Nzeako B, Al Mahrooqi Z, et al. In vitro antibacterial activity of Omani and African honey. *Br J Biomed Sci* 2003; 60:1-4.
- 32- Ceyhan N, Ugur A. Investigation of in vitro Antimicrobial Activity of Honey. *Riv Biol Forum* 2001;94:363-371.
- 33- Haffejee IE, Moosa A. Honey in the treatment of infantile gastroenteritis, in *British Med J* 1985;290:1866-1867.
- 34- Obi L, Ugoji EO, Edun SA, et al. The antibacterial effect of honey on diarrhea causing bacterial agent isolated in Lagos, Nigeria. *Afr J Med Sci* 1994;36:283-284

RETRACTED

مطالعه بالینی و میکروبیولوژیک نقش عسل طبیعی ارومیه در التیام سوختگی تجربی در سگ

دکتر فرنود شکوهی^۱، دکتر حسین تاجیک^۲، دکتر سیامک سیف زاده^۱، دکتر بختیار فرتاش^۳

^۱ گروه علوم درمانگاهی و ^۲ گروه بهداشت مواد غذایی دانشکده دامپزشکی، دانشگاه ارومیه، ارومیه، ایران.
^۳ دانش آموخته دانشکده دامپزشکی، دانشگاه ارومیه، ارومیه، ایران.

هدف: این پژوهش با هدف ارزیابی خواص التیامی عسل های طبیعی تولید شده در شهرستان ارومیه صورت گرفته است.
طرح: مطالعه تجربی.

حیوانات: ۱۰ قلاده سگ نژاد مخلوط.

روش کار: زخمهای سوختگی بر اساس مدل استاندارد Hoekstra بر روی ناحیه جانبی پشتی در سگها ایجاد شدند. در گروه درمان (شامل ۵ قلاده) زخمها پس از شستشوی روزانه توسط یک لایه نازک از عسل طبیعی (۱۰ میلی لیتر) پوشانیده میشدند. در گروه شاهد (شامل ۵ قلاده) زخمها تنها توسط محلول سرم نمکی نرمال شستشو میگردیدند. زخمها بصورت کلینیکی و میکروبیولوژیک در روزهای ۱، ۷، ۱۴ و ۲۱ پس از عمل مورد ارزیابی قرار گرفتند.

نتایج: نتایج، ظاهر التیامی بهتر و روند ترمیمی سریعتری را در گروه درمان نسبت به گروه شاهد نشان دادند ($P < 0.05$). همچنین شمارش کامل باکتریایی بیانگر تعداد اجرام میکروبی کمتر در گروه درمان در مقایسه با گروه شاهد است ($P < 0.05$).

نتیجه گیری: بر مبنای یافته های حاصل از این مطالعه کاربرد موضعی عسل طبیعی تولید شده در شهرستان ارومیه دارای اثرات مفید و موثری در تسریع روند التیام در زخمهای سوختگی تجربی از منظر درمانگاهی و میکروبیولوژیک بوده است. عسل بدلیل ارزانی قیمت و سهولت دسترسی میتواند بعنوان یک داروی موضعی موثر در درمان زخمهای سوختگی مورد توجه قرار گیرد.
کلید واژگان: درمان موضعی، عسل، سوختگی، زخم، میکروبیولوژی، سگ.