


CLINICAL REPORT

Metabolic Bone Disease in a Leopard Gecko: A Case Report

Reza Azargoun ¹, Seyed Mohammad Hashemi-Asl², Bita Khosravi-Mahtaj¹, Negar Mehrizi¹

¹ Department of Internal Medicine and Clinical Pathology, Faculty of Veterinary Medicine, Urmia University, Urmia, Iran. ² Department of Surgery and Diagnostic Imaging, Faculty of Veterinary Medicine, Urmia University, Urmia, Iran.

ARTICLE INFO

ABSTRACT

Article History:

Received: 8 December 2024

Revised: 3 February 2025

Accepted: 3 February 2025

Keywords:

Exotic

Eublepharis macularius

Lizard

Nutritional secondary hyperparathyroidism

Metabolic bone disease (MBD) is a common disease in reptiles, however in leopard geckos it is not well described, and most studies have addressed other aspects of the disease, so the importance of husbandry principles has been somewhat obscured. A leopard gecko was referred with the owner's complaint of dysphagia, hyporexia, and reluctance to move. Clinical examinations revealed lethargy, hypothermia, and jaw deformity. The lizard suffered from a lack of UV light source, an inappropriate temperature range, and dietary calcium deficiency. A Total-body radiograph showed a generalized decrease in the contrast between bone and soft tissue resulting from MBD. Sadly, despite supportive treatments, the gecko did not survive. According to this clinical report, it seems that leopard geckos unlike some other reptiles, rely more on UV-B light and optimum temperature than dietary sources for their vitamin D needs. As geckos are increasingly kept as pets, veterinarians and owners need to have up-to-date knowledge about the husbandry principles of this reptile.

Introduction

Metabolic bone disease (MBD) is a group of conditions, with nutritional secondary hyperparathyroidism (NSHP) and renal secondary hyperparathyroidism (RSHP) being the most common in captive reptiles.¹ RSHP is a condition that usually occurs in older animals, where a gradual decrease in renal function ultimately results in the inability to selectively conserve calcium and excrete excess phosphorus.² The most frequent nutritional disease in captive reptiles, especially juvenile lizards, is NSHP, resulting from insufficient exposure to UV-B radiation or dietary calcium and/or vitamin D deficiency.³ Vitamin D, as an endocrine hormone, regulates the balance of calcium and phosphorus through the selective absorption and excretion of these minerals; therefore, a vitamin D deficiency can contribute to MBD.⁴

Eublepharis macularius, often known as the leopard gecko, is one of the most common reptiles as an exotic pet, because of its small size, ease of reproduction, docile temperament, high longevity, and various coloration.⁵ The leopard gecko is primarily an insectivore (although the tendency to hunt smaller reptiles and newborn rodents increases with age), and as a nocturnal species, remains hidden in burrows and damp crevices during the daylight hours.^{5,6}

Leopard geckos may present to veterinary clinics with numerous conditions, frequently due to poor husbandry conditions, so accurate knowledge of species-specific husbandry principles is essential in exotic pet practice.⁷ In this report, we describe MBD in a leopard gecko and highlight the husbandry mistakes caused by owner misconceptions.

 Corresponding author. Email: r.azargoun@urmia.ac.ir

© Iranian Veterinary Surgery Association, 2025

<https://doi.org/10.30500/ivsa.2025.492912.1428>

This work is licensed under the Creative Commons Attribution-NonCommercial 4.0 International License. To view a copy of this license, visit <http://creativecommons.org/licenses/by-nc/4.0/>

Case Description

The owner consented to the use of his pet's data in scientific papers. A 2-year-old female leopard gecko was referred to our teaching hospital with the owner's complaint of dysphagia, reduced appetite, and reluctance to move. In clinical examinations, the animal was lethargic, hypothermic (skin temperature of 19 °C based on infrared thermometer), and had jaw deformity and softening (Figure 1A). The lizard was housed individually in a plastic box (30 × 20 × 20 cm), lined with kitchen paper, and containing a water dish, food supplement powder dish, and hiding box as shown in Figure 1B. The owner admitted that in the past the animal ate four mealworms dusted with calcium-D₃ powder daily. Unfortunately, in the assessment of the pet's husbandry condition, fundamental mistakes were detected. A heat source was not included in the enclosure, so there was no thermal gradient. The enclosure did not have an ideal humidifier and therefore lacked a humidity gradient. Furthermore, the leopard gecko was not exposed to natural sunlight, and the enclosure was not equipped with a UV lamp. There was only one 15-watt incandescent lamp at a distance of about 1 meter from the vivarium floor, which provided 12 hours of light per day.

Radiology is often used as an initial diagnostic method for MBD.² Nonetheless, up to 50% of bones' mineralization should be depleted prior to radiographic alterations.³ A whole-body radiograph of the leopard gecko showed generalized bone demineralization. Also, due to the significant calcium loss from the skeleton, it was difficult to distinguish the bone from soft tissue, which could indicate the severity of MBD (Figure 2).

Treatment and Outcome

Based on the patient's history, and clinical and imaging findings, MBD was considered a possible diagnosis. Therefore, it was recommended to correct husbandry factors, including providing UV-B lamps, maintaining suitable temperature and humidity conditions as well as monitoring them through a thermometer and hygrometer, and the possibility of

exposing the lizard to sunlight. Also, supportive treatments such as an analgesic (Meloxicam: 0.5 mg/kg, PO, q 24 hours) and calcium supplementation (Calcium gluconate: 50 mg/kg, PO, q 24 hours) were prescribed.^{3,7} Sadly, in the phone follow-up, the owner mentioned that the leopard gecko died three days later.

Clinical Relevance

The three most common causes of MBD detected in reptile medicine include inadequate UV light provision, dietary calcium deficiency, and inappropriate temperature range.⁹ Unfortunately, our patient also suffered from these three fundamental factors in the occurrence of MBD, which were caused by poor husbandry conditions.

When 7-dehydrocholesterol (provitamin D₃) in the skin is exposed to radiation with a wavelength between 280 and 315 nm (UV-B rays), it is converted into pre-vitamin D₃.⁵ Pre-vitamin D₃ is, in turn, converted to cholecalciferol (vitamin D₃) via temperature-sensitive isomerization.¹ Vitamin D₃ is then transported to the liver and converted to 25-hydroxycholecalciferol (calcidiol). Further hydroxylation occurs in the kidneys, where calcidiol is converted to the active hormonal form of vitamin D₃, calcitriol (1,25-dihydroxycholecalciferol), which is needed to absorb dietary calcium.^{5,1} The owner mistakenly believed that because the leopard gecko is nocturnal, there is no need for UV light. However, it has been documented that predominantly nocturnal lizards may also require UV-B radiation, but require less UV-B exposure to produce similar levels of vitamin D₃ compared to diurnal species.⁴ Indeed, evolutionary adaptations in species with less opportunity for sunlight exposure (e.g., nocturnal reptiles) develop a more sensitive and efficient mechanism to synthesize vitamin D from UV-B.^{5,6} A study conducted by Gould et al. (2018) confirmed that leopard geckos that are exposed to UV-B rays for a short period (2 hours) can significantly increase their calcidiol concentration compared to geckos that are not exposed to UV-B but are fed the same diet. Also, these authors suggested that leopard geckos maintained on a



Figure 1. (A) The arrow indicates the mandibular deformity of the leopard gecko caused by MBD. (B) The leopard gecko's vivarium with inappropriate lighting, heating, and humidity conditions.

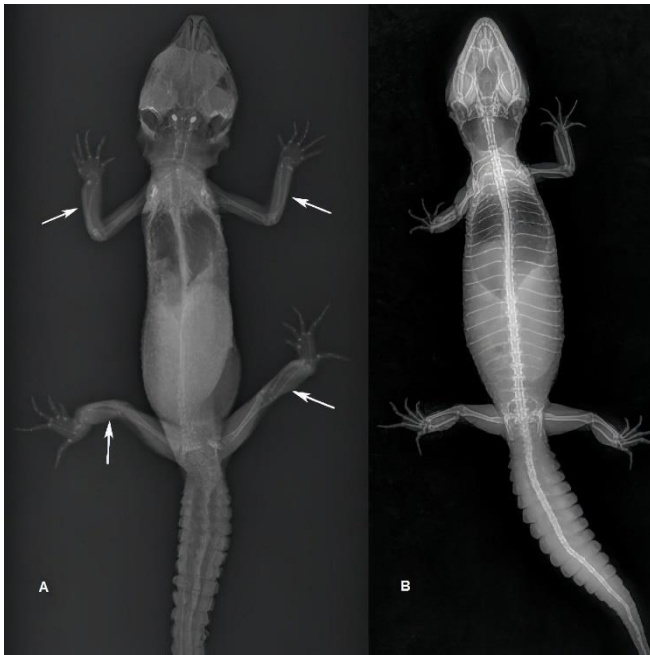


Figure 2. Dorsoventral radiographs of the leopard gecko with MBD resulted from inappropriate husbandry (A), compared to a leopard gecko with normal bone density (B).⁸ Our patient's radiograph shows a general decrease in skeletal opacity and contrast between bone and soft tissue. In the radiograph of the healthy leopard gecko, the bones of the cranium, spine, ribs, and limbs are clearly defined. On the contrary, thickness reduction of the long bones' cortex and bowing, especially in the radius, ulna, tibia, and fibula bones (arrows), can be well identified.

diet with vitamin D₃ deficiency may increase the circulating concentration of calcidiol by increasing basking behavior to more exposure to UV-B radiation.⁶

Another misconception of the owner was that the leopard gecko is sensitive to sunlight due to the color morph of the animal (Eclipse). It should be remembered that there is no surrogate for natural, unfiltered sunlight and most types of UV-B lamps used in captivity are insufficient supplements for natural sunlight.^{2,3} Although, according to the authors' knowledge, there are no studies on the effects of ultraviolet light on the color morphs of leopard geckos; it is documented that any genetic mutation with lower than normal levels of melanin is more susceptible to UV burns of the eyes and back skin.² A study found that providing an unprotected 12-hour photoperiod with high UV-B intensity leads to weekly ecdysis periods in leopard geckos.⁶ There are reports of photo-dermatitis in blue-tongued lizards and photo-dermatitis and keratoconjunctivitis in pythons caused by long-term use of excessive UV light. Also, skin cancers in captive reptiles can be associated with UV exposure, as in humans.⁵ Therefore, it is important to consider an ideal UV lamp source, suitable light distance to the basking area, provision of a UV gradient, and appropriate time for UV exposure.

Leopard geckos are insectivorous and, therefore must have a varied diet of insects such as cockroaches, crickets, locusts, and worms.⁷ However, most insect species

commercially available for feeding reptiles have a deficiency in vitamin D₃ and an inverted Ca:P ratio, thus may predispose insectivorous reptiles to NSHP unless supplemented.³ Dietary calcium supplements must be provided to all lizards. A wide variety of supplements are available, some containing only calcium, and others containing different amounts of calcium, vitamin D₃, and other minerals and vitamins. Regardless of which supplement is chosen, a common mistake is not to ensure that the reptile eats the supplement provided.¹ Dusting insects with calcium and vitamin supplements powders before offering them to a reptile has been recommended for many years to correct their nutritional imbalances.³ However, this method may provide variable results due to the amounts of powder that adhered to the insects and the alteration in palatability can affect the overall intake of the supplement.³ Furthermore, care should be taken to avoid extra supplementation. Gut loading, by providing a nutrient-dense diet to feeder insects, can be a more efficient method to enhance the nutritional balance of the insectivorous reptiles.³ The ability of leopard geckos to absorb calcium through their digestive system is excellent, but as mentioned earlier UV light must still be provided at all times.⁷ This issue can explain the cause of MBD in our patient because despite taking a calcium-D₃ supplement, there was no suitable source of UV light.

Temperature is frequently a neglected factor for reptile health and especially for MBD prevention.² As previously stated, converting the pre-vitamin D₃ to vitamin D₃ is a temperature-dependent process. Common husbandry mistakes include housing reptiles at unfavorable temperatures or placing the initial heat source in a separate location from the UV light source, in which case the reptile usually chooses heat instead of UV.¹ Leopard geckos, like all reptiles, are poikilothermic, so if a temperature gradient is provided in their enclosure, they can optimize their metabolism and maintain their health by moving within their optimal temperature range. The optimal temperature for a leopard gecko will be between 28 to 32 °C and 22 to 24 °C at the warm end and cold end of the vivarium, respectively. Unfortunately, many owners do not pay attention to the fact that if the temperature range of the enclosure is inappropriate, any treatment will be less effective.⁷

In conclusion, numerous factors contribute to MBD in reptiles as a preventable condition; however, improper husbandry can be the most important. So, point-by-point owner education by veterinarians with up-to-date knowledge regarding the unique husbandry needs of each exotic species is important. Nevertheless, detailed studies in leopard geckos are necessary to establish a reference range for calcidiol and to ascertain the duration of exposure to UV light as well as dietary vitamin D₃ required to achieve this value.

Conflict of Interest

None to declare.

References

1. Hedley J. Metabolic bone disease in reptiles: Part 1. *UK Vet Companion Animal*. 2012; 17(6): 52-54. doi: 10.1111/j.2044-3862.2012.00210.x
2. Klaphake E. A fresh look at metabolic bone diseases in reptiles and amphibians. *Veterinary Clinics: Exotic Animal Practice*. 2010; 13(3): 375. doi: 10.1016/j.cvex.2010.05.007
3. Mans C, Braun J. Update on common nutritional disorders of captive reptiles. *Veterinary Clinics: Exotic Animal Practice*. 2014; 17(3): 369-395. doi: 10.1016/j.cvex.2014.05.002
4. Oonincx DG, Diehl JJ, Kik M, Baines FM, Heijboer AC, Hendriks WH, Bosch G. The nocturnal leopard gecko (*Eublepharis macularius*) uses UVb radiation for vitamin D₃ synthesis. *Comparative Biochemistry and Physiology Part B: Biochemistry and Molecular Biology*. 2020; 250: 110506. doi: 10.1016/j.cbpb.2020.110506
5. Franco FL, Oliveira PA, Patrício R, Faustino-Rocha AI. The lifestyle of the leopard gecko and the importance of ultraviolet radiation, vitamin D and calcium. *Veterinarska Stanica*. 2024; 55(4): 441-456. doi: 10.46419/vs.55.4.6
6. Gould A, Molitor L, Rockwell K, Watson M, Mitchell MA. Evaluating the physiologic effects of short duration ultraviolet B radiation exposure in leopard geckos (*Eublepharis macularius*). *Journal of Herpetological Medicine and Surgery*. 2018; 28(1-2): 34-39. doi: 10.5818/17-11-136.1
7. Miles S. Common conditions in leopard geckos (*Eublepharis macularius*). *Companion Animal*. 2017; 22(9): 546-551.
8. Sciencephotogallery. X-ray of a gecko lizard. Available at: <https://fremontmarine.com/x-ray-of-a-gecko-lizard-by-roberts-science-ww-9038166>. 2021. Accessed Dec 8, 2024.
9. Hedley J. Metabolic bone disease in reptiles: Part 2. *UK Vet Companion Animal*. 2012; 17(7): 38-41. doi: 10.1111/j.2044-3862.2012.00227.x