



## Surgery of the Bovine Claw

Roberto Acuña\*, DVM,

---

The most frequent types of claw surgery in cattle are:

- **Claw amputation.**
- **Amputation through the coronary band**
- **Removal of interdigital hyperplasia**
- **Surgical arthrodesis of the distal interphalangeal joint.**
- **Dew claw amputation.**

Without a doubt, claw amputation is the most widely used of these surgical interventions, as it is a practical, easy and cheap technique.

The author would like to mention that, in his experience, the result of this operation is different under grazing conditions. The international literature generally mentions that animals do not last more than one lactation after amputation. He has treated cows that

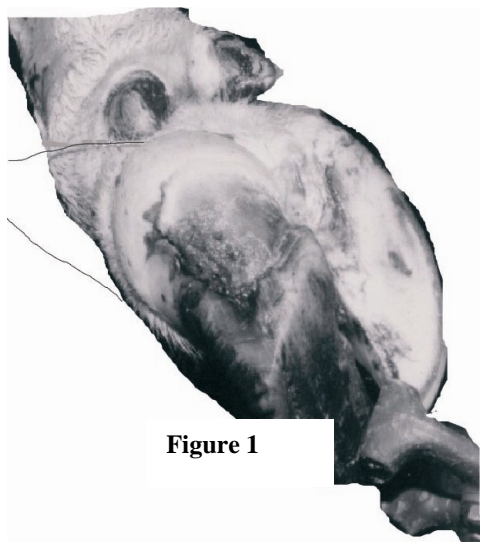


Figure 1

have lasted four more lactations after amputation.. The results on beef bulls on pasture are also excellent: some are still serving cows over four years after amputation.

It is likely that the pressure of an intensive management system is responsible for this difference.

### 1) Claw amputation:

This operation is recommended to treat *irreversible lesions of the deep tissues* of the claw, such as:

- Septic arthritis of the distal joint.
- Necrosis of the insertion of the deep

---

\* **Roberto Acuña**

Professor (H) of Ruminant Clinics Udelar, Uruguay. E-mail: robacu@adinet.com.uy

- flexor tendon to distal phalanx.
- Abscessation and necrosis of the digital cushion.
- Osteitis and osteolysis of the pedal bone
- Pedal bone open fractures

All these lesions are very painful and the intervention provides immediate pain relief. The animal can remain standing, with the leg lifted up in the crush or in the milking parlour. The operation can also be done on the animal lying down, after sedation with xylazine. After applying a tourniquet to the metatarsus or metacarpus, local intravenous anesthesia can be given. Often it is difficult to find the vein because of severe inflammation in the area. In this case, it is better to use a ring block anesthesia.

The operation area should be washed, shaved and disinfected. With a scalpel, a cut is made, starting in the interdigital space and ending in the middle of the second phalanx. An embryotomy wire is used to cut through the bone (fig. 1) inserting it in the interdigital space and following the skin cut.

Usually, it is not necessary to ligate the blood vessels, although the tourniquet should be loosened a little to check that there are no major hemorrhages. In case there are, we leave the tourniquet in place and administer coagulants to accelerate the coagulation process.

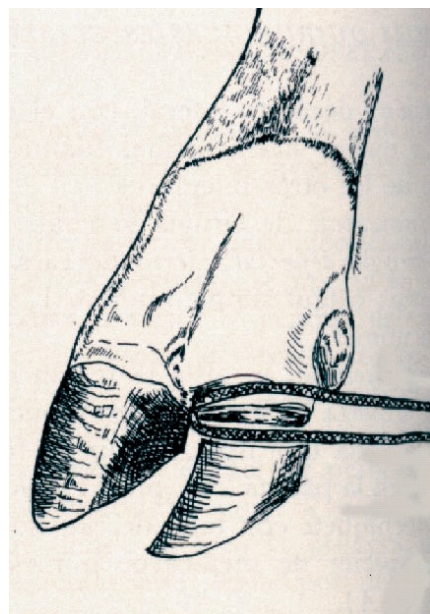


Figure 2

To finish the operation, we sprinkle some antibiotic powder on the wound (oxytetracycline) and bandage the stump with a wad of cotton wool drenched in peroxide, held in place by elastic bandages (Vet-Flex). We use systemic antibiotics, usually a combination of penicillin and streptomycin.

Post-operative care is important: the animal should be kept in a clean dry place for at least two weeks<sup>1</sup>.

The bandage should be taken off after 96 hours, although, whenever this is feasible, the best treatment is to change it after 48 hours.

Another surgical technique is to leave a skin flap that is drawn over the stump to form a protective cover. In this author's experience, there is no difference between the two techniques. A slight disadvantage of this technique is that the stitches tend to get infected.

## 2) Amputation through coronary band.

This technique is indicated when the infection only affects the internal structures of the claw, without having reached the coronary band or higher. The coronary band is left intact (Fig. 2), so that a new protective horn capsule will be formed in time. Preparation for the operation is the same as for amputation. We can either use an embryotomy wire or a saw to make a cut just below and parallel to the coronary band.

We disarticulate and remove the second phalanx and the distal sesamoid bone through the incision and take care to remove all necrotic tissue. The operation site is thoroughly rinsed with saline solution and sprinkled with antibiotic powder<sup>2</sup>.

We finish with an elastic bandage (Vet-Flex) and cover the bandage with waterproof tape. Post-operative care again consists of providing a clean dry place. This intervention is very useful in the treatment of complicated toe ulcers<sup>3</sup>.

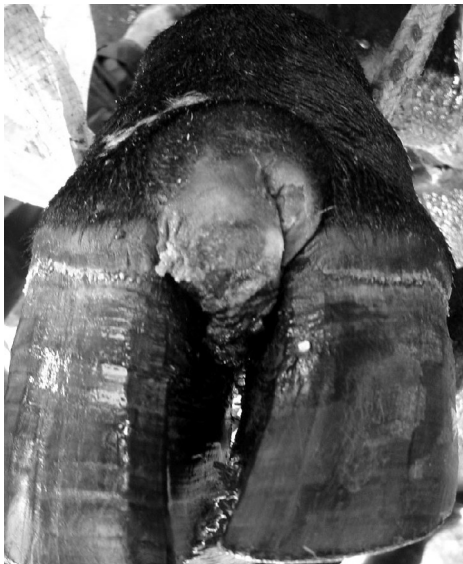### **3) Removal of interdigital hyperplasia.**

This is a common problem in beef cattle and older animals in general. The severity of the lameness depends on the size of the lesion and whether it is accompanied by blow fly strike.

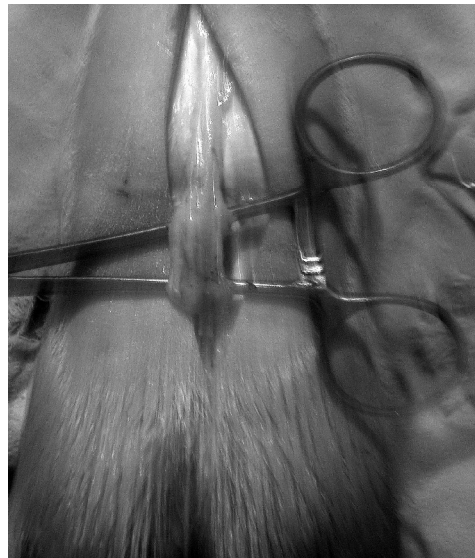#### **Technique**

The animal is prepared in the same way as for amputation, including anesthesia. We drill holes in the tips of both digits, through which we thread a wire. An assistant separates the digits by pulling on the wire. We make a wedge shaped incision through the skin around the growth, pulling on the growth with a towel clip or forceps. It is important to remove all protruding fat tissue, avoiding the distal cruciate ligaments.

The two wires are tied together to keep the digits close to each other. A pressure bandage of cotton wool drenched in peroxide is applied. It is not necessary to administer systemic antibiotics.



**Figures 3 & 4**



Very large hyperplasias also require the removal of the blood supply and the dorsal digital nerve (Fig. 3 &4). A 5-6 cms incision is made on the dorsal side of the metacarpus or -tarsus and, after ligating the blood vessels in two places, the section between the ligatures is removed, together with the nerve. This prevents re-growth of the hyperplasia.

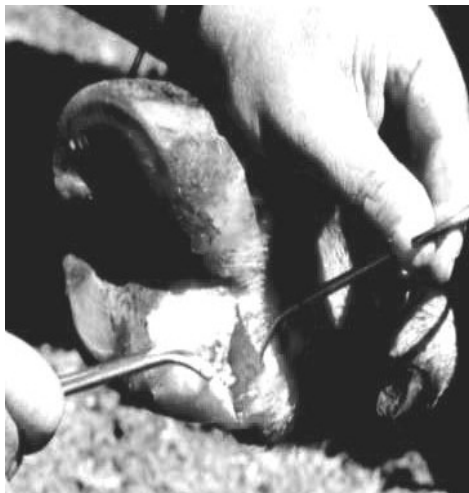#### **4) Surgical arthrodesis of the distal interphalangeal joint.**

Arthrodesis of the distal claw joint is an alternative to amputation and should be recommended in genetically valuable animals, e.g. show animals.

This digit sparing intervention controls the infection by removing necrotic tissue and getting the affected bones to fuse<sup>4</sup>. After a successful intervention, the arthrodesis between the bones is painless. With good post-operative care, the prognosis is good.

In the author's experience, it is important to make sure that the owner understands the amount of post-operative care required (up to 45 days). This is a useful technique in beef bulls whose owners prefer it for aesthetic reasons.

#### **Technique**



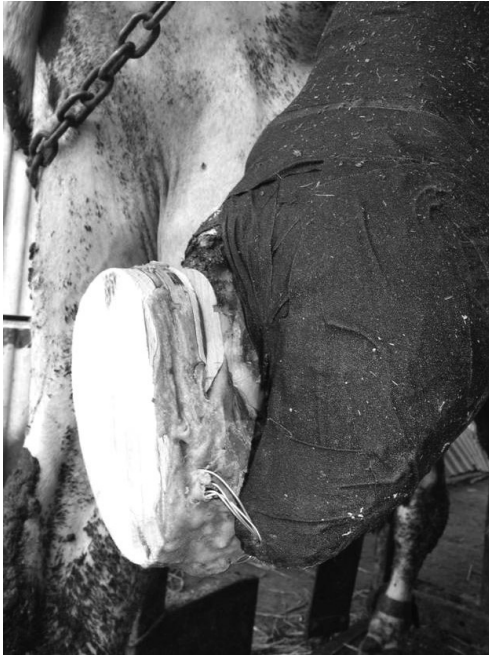**Figures  
5 & 6**



Systemic antibiotic therapy should be started before the operation. The animal is prepared in the same way as for amputation. The anesthesia has to be excellent, as this is a very painful intervention. We use regional intravenous anesthesia, applying a tourniquet just above the carpus or tarsus. We shave the area of the digital vein and, using a 18 g 4cm long needle, we remove the accumulated blood and inject 20-30 cc of 2% lidocaine without adrenaline in the vein. If the leg is too swollen to find the digital vein, it is recommended that the procedure is carried out in a hoof trimming box. The sling that lifts up the leg acts as a tourniquet and raises the saphenous vein, which can be used to inject the anesthetic<sup>1</sup>.

We prepare an aseptical surgical site and cut through the hoof cushion at the site where the skin ends and the heel horn begins, from the inside to the outside (Fig. 5). We cut through the tissue until we get to the joint. The tissues that are removed in this operation are the deep flexor tendon, the sesamoid bone and all the fibrous tissue that we find along the way. Once we have opened the joint and drained it, we should do a thorough curettage (Fig. 6) of all the cartilage and the bone underneath the cartilage until we find healthy bone, which we detect by palpation. Often the curettage is aided by the use of a drill and a 10 mm drill bit. The incision is closed with absorbable material in separate sutures.

The affected claw should remain flexed so as to aid the fusion of the bones (ankylosis) and all of the animal's weight should be transferred to the healthy claw.



These two objectives are met when we use a wooden block with two holes drilled at about 4 cms of the tip (Fig. 7). We also drill two holes in the tip of the diseased claw and tie the claw to the block with a flexible wire. The block is then glued to the healthy claw in the usual way using resin , to keep the diseased claw off the ground and flexed.

Post-operative care should be given for a long time<sup>5,6</sup>. The animal is very lame after the operation and it often loses a lot of weight. Slowly, it starts to recover, is less lame and starts to put on some weight. In our experience, this usually takes about 30-40 days.

**Figure 7**

##### **5) Amputation of the dewclaw**

The dewclaws are sometimes affected by environmental infections, most often digital dermatitis. We have found proliferative dermatitis of the dewclaws for which surgical intervention has been indicated (fig. 5).

It is an easy uncomplicated technique in which a circle is cut around the affected dewclaw, taking it out and putting in a few interrupted sutures.

##### **References:**

1. Weaver AD, StJean G, Steiner A. *Bovine Surgery and Lameness*. 2<sup>nd</sup> ed. Oxford: Blackwell, 2005.
2. Sosa Prieto JC. Lesiones traumáticas y cirugía del pie Bovino. Enfermedades Podales de los Rumiantes. ED Hemisferio Sur 1994.
3. Acuña R, Rivas LG. La artrodiesis quirúrgica de la articulación interfalangeana distal. Revista de ANEMBE (Asociación Nacional de especialistas en Medicina Bovina de España). No.24; Noviembre-Diciembre de 1999.
4. Ferguson JG. Alternatives to amputation in the Bovine Digit. VIII Symposium on disorders of the ruminant digit. Banff Canada 1994. p. 96.
5. Greenough P, Weaver AD. *Lameness in cattle*. 3<sup>rd</sup> ed. 1997.
6. Greenough P, Acuña R. X Congreso Latinoamericano de Buiatría. Paysandú Uruguay junio del 2002;54-67.