

## Clinical and Histological Evaluation of Low Level Laser on Regeneration of Hip Joint Cartilage in Rabbit

Davood Sharifi<sup>1\*</sup> DVM, PhD  
Gholamreza Abedi<sup>2</sup>, DVM, DVSc  
Hossein Jodari<sup>3</sup>, DVM  
Iraj Sohrabi Haghdoost<sup>2</sup>, DVM, PhD  
Pejman Mortazavi<sup>2</sup>, DVM

<sup>1</sup>Faculty of Veterinary Medicine, University of Tehran, Tehran, Iran.

<sup>2</sup>Faculty of Specialized Veterinary Sciences, Islamic Azad University, Science and Research Branch, Tehran, Iran.

<sup>3</sup>Faculty of Veterinary Medicine, Islamic Azad University, Tabriz Branch, Tabriz, Iran.

---

### Abstract

Treating articular cartilage in dogs is a challenge in the contemporary orthopedics of small animals. Currently application of Low Level Laser being advocated for various orthopedics disorders that is why its effect being evaluated in experimentally induced defect in hip joint. The experiment was conducted on 24 adult male rabbits which were divided into two groups of (control & experimental) with 12 rabbits each. Effective anesthesia was induced using combination of acepromazine, ketamine and xylazine. After exposure and subluxation of right femoral head, the maximum accessible cartilage was denuded up to subchondral bone using dental bit in each rabbit. No treatment was given to control group, whereas experimental one was subjected to Low Level Laser Therapy daily for 1 minutes diode laser 630 nm and 2 minutes of infrared with 890 nm for 14 days daily, then further they were subdivided into 3 subgroup of 4 rabbits each with duration of 1, 2 and 3 months. There was no trace of fibrocartilage or cartilage formation in control group samples even up to end of observation period. There was remarkable connective tissue with trace of chondrocytes beneath that which were located in the large lacunae having different type of isogenic during one month period in experimental group. Scattered collagen fibers between chondrocyte cells was seen which was not enough to fill the defect in one month period, whereas drastic changes was noticed in two and three months duration with full coverage of defect area with newly formed cartilage

---

#### \* Davood Sharifi

Department of Clinical Sciences, Faculty of Veterinary Medicine, University of Tehran, Tehran-Iran  
e-mail: sharifid@yahoo.com

having well located chondrocytes in a very large lacuna with huge compact collagen fibers.

## Introduction

Treatment of cartilage and osteochondral defects has always posed problems for orthopedic surgeons. Determination of the most suitable treatment method depends on evaluating the size, depth, location of the lesion, associated injuries, and the mechanical alignment of the limb<sup>1, 2</sup>. Small and medium size defects are best treated with micro fracture, as demonstrated by Steadman<sup>3,4</sup>. The goal of the repair process is to provide a hyaline or fibro cartilage cover over the damaged chondral surface<sup>5, 6</sup>. Collagen matrices to optimise healing in autologous chondrocyte implantation and marrow stimulation techniques as well as bone graft to facilitate the treatment of osteochondral lesions. The use of mobilization after cartilage repair or stimulation techniques has been studied in both human and animal models<sup>5</sup>. In normal articular cartilage, movement and compression of the joint provide nutrition and removal of wastes. If the joint is immobilized or movement is restricted, properties of the articular cartilage may become altered. Likewise, if movement is limited after a surgical procedure, a decrease in collagen formation can occur as cyclical loading is applied to cartilage during activities of daily living or exercise, it is believed that this stimulation may help with joint repair<sup>5,7</sup>. In the rehabilitation process, therapeutic activities such, gradual progression of weight bearing and stationary cycling can contribute to improved range of motion (ROM) and return to function after a surgical procedure. However the type, frequency, and intensity of the therapeutic exercise that is required to stimulate the nutrition of the cartilage and the overall joint are not clearly defined. Although research has provided good clinical insights into the type and frequency of the exercises, greater investigation into the intensity needed for proper cartilage healing would be beneficial. In 1917, Albert Einstein established the physical paving the way for the development of the laser. Infact the Low Level Laser Therapy (LLLT) is a natural and biological therapy, because even from early ages, man has considered the light of the sun to be responsible for his health and do believe "Laser light restores health to just such an ailing cell". On the basis of experience, one can presume an optimal effect on surface structures for laser output of 50-100 mw (continuous beam) or 50-100 W peak pulse power( pulse laser) over an irradiation time of approx.20-40 sec. for deeper structures, articular cartilage, ligaments, fistulae, Sinusitis<sup>8,9,10</sup>. The treatment duration must be increased to approx.2-3 min. per point. Definitely it will have the following tissues effects like, wound healing, anti-inflammation, analgesia and immunoregulation too. There are good reports about physiological repair effects of low level laser such as a reduction of pain by the body's production of endorphins, the diminishing of inflammation from suppression of tissue excitation, the stopping of a tissue's influx of fluids and disappearance of swelling, redness, and heat beside elimination of pain<sup>(11)</sup>. The elevation of lymphatic drainage, the increase of blood circulation and flow of healing enzymes into a traumatized area, the measurable showing of up to 75 percent increase in enzymes. The spasm release of light muscles (both smooth and striated which had been creating chronic pain, joint stiffness and decreased motility). The speeding up of bone repair from the stimulation offered by fibroblast and osteoblastic proliferation. Mechanism of delivery and duration of exposure, biostimulation, or low-energy photon therapy, is defined as non-thermal interaction of

monochromatic radiation with a target site, although the physiologic interaction for this type of energy application on tissue is still not understood. Recommended veterinary application include first aid treatment for traumatic and surgical wounds, strains, musculoskeletal pain and dysfunction, rheumatoid arthritis, Osteoarthritis, neurological applications such as neuralgia and other nerve injuries and sport injuries ranging from contusions to muscle tears<sup>12,13,14</sup>. It has been highly advocated to take care of nerve injuries and speeding up nerve impulses besides having good effect on nervous tissue regeneration.<sup>15,16,17,18</sup> Low level laser also increases the mitochondria's energy output within the cell by more than 150 percent As far as therapeutic lasers are concerned .It utilizes a wave-length of monochromatic light in the 630 to 905 nanometer (nm) range, known as the "Therapeutic Window). A wave-length of 905 nm has the least absorption in this window due to the primary influence of melanin of skin and hence provides the greatest penetration of photons of energy harmlessly into tissue,"energizing "or biostimulating" this tissue into accelerated rate of healing<sup>19</sup>.The tissue effect of lasers can best be characterized by understanding the absorption of light in tissue<sup>20</sup>.Tissues are heterogeneous substances that contain a variety of components that vary between tissue types and even vary within the structure of the tissue. The effect of Low Level Laser therapy (LLLT) is documented by a lot of scientific investigations. In this paper the results of application of Low Level laser for regeneration and re-growth of full thickness of hyaline cartilage after experimentally denuding surface articular hip joint cartilage will be discussed in details.

## Materials and Methods

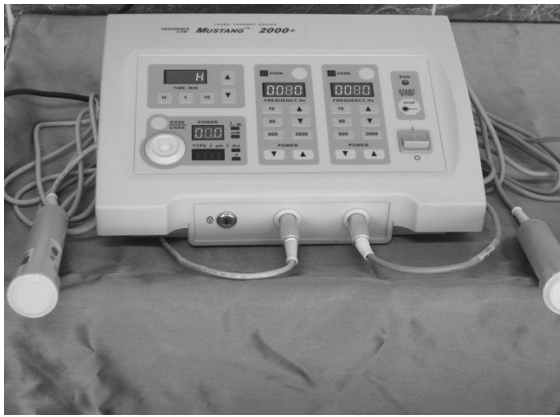### Study design

This study was performed in accordance with the Islamic Azad University, Research and Sciences Center's Law on animal experimentation and this research project was approved by the Faculty of Specialized Veterinary Sciences Research Councils. The experiment was conducted on 24 New Zealand white male rabbits; 6 month old (weighing  $3.5 \pm 0.450$  kg) were used and kept under standard managerial condition with free access to food and water. These rabbits were subsequently divided into two groups of (control & experiment) with 12 rabbits each.

### Surgical procedures

The surgery were performed under general combined anesthesia. The rabbits were anesthetized with intramuscular injection of mixture of Acepromazine 1mg/kg intramuscularly as premedication ( 2% ,Karon Co. Iran) and anesthesia was induced intramuscularly using 35 mg/Kg ketamine (10%, Alfasan Woerden-Holland) with combination of xylazine hydrochloride 5 mg/Kg( 2%,Alfasan.Woerden-Holland). After exposure of right hip joint and subluxation of femoral head, the maximum accessible cartilage was removed and surface was denuded completely up to subchondral bone using dental bit in all rabbits. No treatment was given to control group, whereas experimental one was subjected to Low Level Laser Therapy diode laser daily for 1 minutes with 630 nm wave length followed by 2 minutes infrared 890 nm for 2 minute (Mustang 2000+ Laser Therapeutic Device) for 14 days daily, then further they were subdivided into 3 subgroup of 4 rabbits each with duration of 1, 2 and 3 months. (Figs. 1, 2). For

histopathological evaluation of repaired lesions at the end of observation period ,the rabbits were sacrificed using saturated thiopental sodium and harvested femoral head was kept in 10% buffered formalin .The sample were stained using H& E and Masson's Trichrome stains. Clinical observation was recorded till end of defined period.



**Figure 1:** Mustang 2000 + Laser Therapeutic Device RPLC"TECHNIKA" Moscow (www.mustangmed.ru)



**Figure 2:** Correct application of laser probe

### Post Operative Care

Extensive care of daily wound dressing till removal of sutures on 12<sup>th</sup> day was employed. Antibiotics (penicillin G procaine 40000 IU/kg IM every 12 hours) dexamethasone (0.6 mg/Kg i.m.) Vitamin B.Complex (0.2 mg/Kg i.m.) and analgesic such as tramadol hydrochloride (5 mg/Kg i.m. bid) were administered for 3 post-operative days.

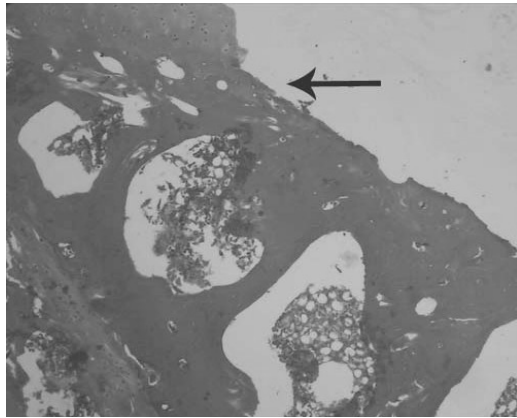
### Histopathologic analysis

Segment of femoral head that had been previously fixed in 10% neutral buffered formaldehyde solution were decalcified, embedded in paraffin and sectioned at 6 microns. The sections were obtained parallel (serial sections) and transverse to the long axis of the section of each bone segments were stained with Hematoxylin and Eosin (H&E) and Masson's Trichrome methods for histopathology <sup>21</sup>

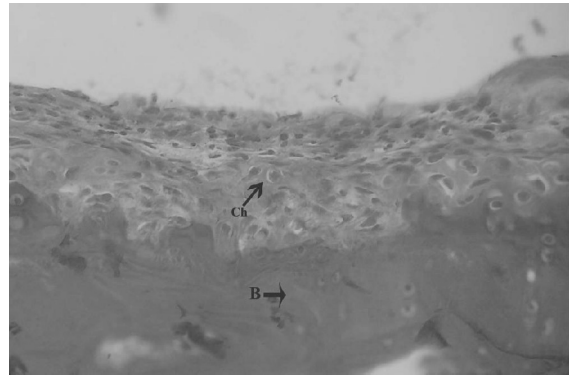
### Results

No operative or postoperative complications were encountered. All of the rabbits tolerated operation well and survived until the final experimental time. No wound opening or infections were observed. After sacrifice, the macroscopic evaluation revealed maintenance of correct position of femoral head and intact of hip joint at the sit of operation. .Histomorphological evaluation of different samples indicated there was no trace of fibrocartilage or cartilage formation in control group during observation period (Fig. 3) .There was remarkable connective tissue with trace of chondrocytes beneath that located the large lacunae having different type of isogenic. Scattered collagen fibers between chondrocyte cells was seen which was not enough to fill the defect in one month duration (Figs .4) There was drastic changes was observed in two and three

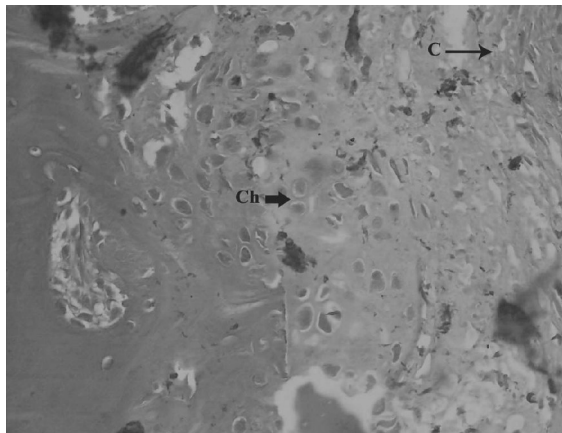
months duration. Full coverage of defect area with newly formed cartilage having well located chondrocytes in a very large lacuna with collagen fibers (Figs.5, 6, 7).



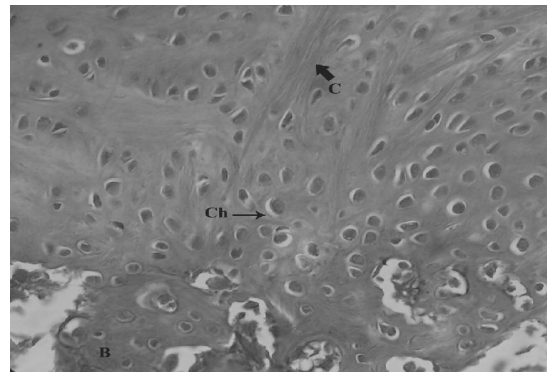
**Figure 3:** Section of femoral head with osteochondral bone with no sign of surface cartilage showing (H&E X 160)



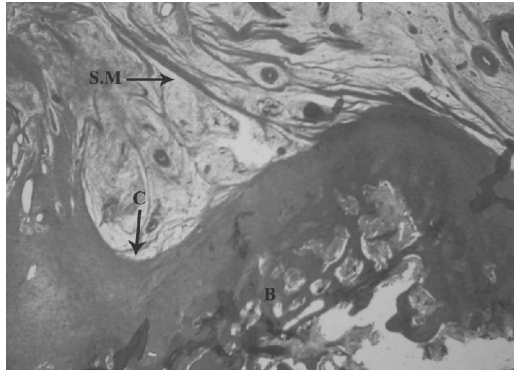
**Figure 4:** Section of femoral head with osteochondral bone (B) with connective tissue, chondrocyte with lacunae (ch) in one month duration (H&E X 640)



**Figure 5:** Section of femoral head with osteochondral bone showing collagen fibers(C) .Shaping cartilage tissue with chondrocyte with lacunae (ch) in two month duration (H&E X 640)



**Figure 6:** Section of femoral head with osteochondral bone showing the presence of rows of chondrocytes (ch) between collagen fibers(C) leading to cartilage formation in three months duration. (H&E X 640)



**Figure 7:** Section of femoral head with osteochondral bone (B) showing the newly formed hyaline cartilage (C) with chondrocyte (ch) between Collagen fibers (C) in three months duration (H&E X 160)

## Discussion

Articular cartilage of higher animals, including man, has very limited potential for repair<sup>13,22</sup>. Following injuries to articular cartilage, the cartilage generally does not repair itself because of its very limited capacity for regeneration. Repair is dependent on the extent and the depth of injury and the surviving chondrocytes and normal articular cartilage matrix<sup>23,24</sup>. In injuries involving subchondral bone, there is no regeneration of the cartilage, but there is typically enlargement and progression of the lesion with associated pain. The ultimate goal of treatment of these lesions is restoration of the cartilage, but in most cases this is not achieved. Adult articular cartilage is not vascularized and, as stated above, lacks the capacity to regenerate itself after sustaining damage. When cartilage is cut, without involvement of subchondral bone, the defect often will persist for the duration of the individual's life<sup>6</sup>. Treatment of articular cartilage defects may be either surgical or non-surgical. Several operative procedures are currently used to repair or remove damaged cartilage in order to prevent further destruction of the bone, joint, decrease pain, and restore function<sup>25</sup>. These include arthroscopic debridement and lavage, subchondral bone stimulating procedures, transplantation of chondrocytes or cartilage autografts and allografts and total even knee arthroplasty<sup>3</sup>. However, none of these produce regeneration of the native articular cartilage<sup>26,27</sup>. Drilling of subchondral bone or micro fracture of the same has been used to provide blood supply to fibro cartilage covering of subchondral bone. However, this does not result in regeneration of articular hyaline cartilage<sup>4</sup>. Tissue and cartilage cell transplantation has the potential to produce cartilage repair at the expense of transplanted cells or intact cartilage<sup>28</sup>. To achieve cartilage repair, transplanted cells and tissues must participate in the development of a permanent three-dimensional matrix. In addition, the cells and tissue must incorporate them within the host cartilage. At best, partial healing of full-thickness articular cartilage defects have been reported in a dog and most other studies of articular cartilage regeneration have been performed on rodents, and none of these has produced complete articular cartilage regeneration<sup>12,23,29</sup>.

The results of this study that application of low level laser provides particulate cartilage compositions by stimulating chondrogenesis and producing cartilage regeneration comprising non-demineralized particulate articular cartilage. As a number of disease processes interfere with the structure and function of joints and many do this by

destroying the cartilage and synovial membrane. Such "arthritis" merely means inflammation of a joint, it may be primary, in which case the cause is not immediately obvious; an example of this would be osteoarthritis or "wear and tear" arthritis which is usually a reflection of old age and in addition, rheumatoid arthritis is an immune disease which leads to the auto-destruction of the synovium thereby exposing bone which rubs against its opposite number leading to secondary due which there will be partial or complete destruction of hyaline cartilage<sup>30</sup>. Due to limitation being reported in using other methods for regeneration, using diode low level laser being non-invasive technique showed its positive effect for chondrogenesis within one month by formation of collagen fiber with chondrocytes located in lacunae which could not be traceable in control samples. Metabolism, healing, and biochemical properties of repaired tissue and subchondral bone healing in a weight bearing lesion model in recent research studies which utilizes laser energies have shown promising results in providing an appropriate stimulus for cartilage repair processes with chondral proliferation and reduction of tissue reaction. Objectives of this research study are histological comparing, lesional repair tissue, subchondral bone healing in control and treated groups following treatment of full-thickness cartilage with a selected level flow level laser energy for two weeks and three months of continuous active weight bearing; . This study could determine the integrity and biochemical properties of repaired cartilage tissue provided if cartilage metabolism can be up regulated and reparative tissue stimulated.

## Conclusions

Experiences gained from this experiment proved that there are a lot of advantages in using diode laser therapy irradiation for the treatment of full thickness cartilage injuries, to shorten post-treatment period, reducing discomfort, cost of treatment and time for hospitalization.

## Acknowledgements

I would like to extend my sincere thanks to the Faculty of Specialized Veterinary Sciences Research Councils, the Islamic Azad University, Research and Sciences Center for approval and financial support for this extensive experimental trial

## References

1. Bae DK, Yoon KH, Song SJ. Cartilage healing after microfracture in osteoarthritic knees. *Arthroscopy* 2006; 22:367-3744.
2. Rodrigo JJ, Steadman JR, Silliman JF, et al. Improvement of fullthickness chondral defect healing in the human knee after debridement and microfracture using continuous passive motion. *Am J Knee Surg* 1994; 7:109-116.
3. Steadman JR, Briggs KK, Rodrigo JJ, et al. Outcomes of microfracture for traumatic chondral defects of the knee: average 11-year follow-up. *Arthroscopy* 2003; 19:477-484.

4. Steadman JR, Rodkey WG, Briggs KK, et al. The microfracture technique in the management of complete cartilage defects in the knee joint. *Orthopade* 1999; 28:26-32.
5. Behrens F, Kraft EL, Oegema TR Jr. Biochemical changes in articular cartilage after joint immobilization by casting or external fixation. *J Orthop Res* 1989; 7:335-343.
6. Brucker B, Bulaeva NV. Biofeedback effect on electromyography responses in patients with spinal cord injury. *Arch Phys Med Rehab* 1996;77:133-137.
7. Dowdy PA, Miniaci A, Arnoczky SP, et al. The effect of cast immobilization on meniscal healing. An experimental study in the dog. *Am J Sports Med* 1995; 23:721-728.
8. Gable B, Jan Tuner P. Bone Stimulation by Low Level Laser-A Theoretical Model for the Effects. *Laser Partner. Clinixperience* 2003; 1-4.
9. Herrington L. Patients with hamstring muscle strains returning to sport in less than 14 days. A case report of treatment used. *Phys Therap Sport* 2000;1:137-138.
10. Oezdemir F, Birtane M, Kokino S. The clinical efficacy of low –power laser therapy on pain and function in cervical osteoarthritis. *Clin Rheumatol* 2001; 20:181-184.
11. Lubart, Friedmann H, Faraggi et al. Towards a mechanism of Low energy Phototherapy. *Lower Therapy* 1991; 3:11-13.
12. Kenneth E (:). Lasers in veterinary medicine-where have we been, and where are we going? *Vet Clin Small Anim* 2002; 32:495-515.
13. Petermann U. Laser Therapy in Veterinary Medicine. *Laser Partner-Clinixperience* 2002; 1-7.
14. Reddy A, Reddy M, Seaber A. Restriction of injury response following acute muscle strain. *Med Sci Sport Exer* 1992; 2:321-327.
15. Aners JJ, Borke RC, Woolery SK, et al. Low level Laser irradiation alters the rate of regeneration of the rat facial nerve. *Lasers Surg Med* 1993; 13:72-82.
16. Brucker B, Bulaeva NV. Biofeedback effect on electromyography responses in patients with spinal cord injury . *Arch Phys Med Rehab* 1996;77: 133-137.
17. Moreland JD, Thomson MA, Euoco AR. (1998). Electromyography biofeedback to improve lower extremity function after stroke: A meta analysis. *Arch Phys Med Rehab* 79:2, 134-140.
18. Rochkind S, Nissan M, Alen M, et al. Effects of laser irradiation on the spinal cord for the regeneration of crushed peripheral nerve in rats. *Lasers Surg Med* 2001; 28: 216-219.
19. Peterswn SL, Botes C, Olivier A, et al. The effect of low Level Laser Therapy ( LLLT) on wound healing in horses. *Equine Vet J* 1999; 31:228-231.
20. Smith C. The photo biological basis of low level laser radiation therapy. *Laser Therapy* 19-24.
21. Luna LG. *Manual of histologic staining method of the Armed Forces Institute of Pathology*. 3<sup>rd</sup> ed. New York: Mc Graw- Hill, 1968;32-46, 94-95.
22. Ceccherelli F, Altafini Lo Castro G, Avila A, et al. (2004). Diode Laser in Cervical Myofascial Pain: A Double-Blind Study versus Placebo. *Clin J Pain* 1989; 5:301-4.

23. Athanasiou KA, Fischer R, Niederauer GG, et al. Effects of excimer laser on healing of articular cartilage in rabbits. *J Orthop Res* 2005;13:483-494.
24. Borovoy M, Zirkin RM, Elson LM, et al. Healing of laser-induced defects of articular cartilage: preliminary studies. *J Food Surg* 1989; 28:95-99.
25. Sousa GR, Ribeiro MS, Groth EB. Bone repair of the periapical lesions treated or not with low intensity laser (wavelength=904nm). *Laser Surg Med* 2002 Abstract Issue.
26. O'Driscoll SW. The Healing and Regeneration of Articular Cartilage; Current Concepts Review. *J Bone Joint Surg* 1998; Incorporated,80A;12:1795-1812.
27. Oshiro T.) An introduction to Low Level Laser progress in laser therapy. In: *Proceedings*. Selected papers from the First Meeting of the International Laser therapy Association.1990; 36-47.
28. Chen CH, Hung HS, Hsu SH. Low-energy laser irradiation increases endothelial cell proliferation, migration, and eNOS gene expression possibly via PI3K signal pathway, *Lasers Surg Med* 2008;40:46-54.
29. Crane SW. Lasers in Medicine and Surgery. *Vet Clin Small Anim* 2002; 32: Xi-Xii.
30. Wolbarsht ML, Sliney DH. Progress in laser therapy. In: *Proceedings*. Selected papers from the first meeting of the international laser therapy association. 1990; 31-35.