



## Introduction to Thoracic Surgery

Daniel J Brockman\* BVSc CVR CSAO Dipl. ACVS  
Dipl ECVS MRCVS

*Royal Veterinary College, University of London, London, UK.*

---

### Introduction

Thoracic surgery is performed frequently in small animals, especially at referral centres. The most common indications for thoracic surgery are: to treat routine cardiac disease such as patent ductus, vascular ring anomalies and pericardial effusion, to evaluate and treat suspected pulmonary neoplasia, diffuse and focal thoracic infections, oesophageal diseases, bronchial conditions, pleural conditions and to establish a definitive diagnosis by biopsy. In order to perform thoracic surgery the surgeon must have an intimate knowledge of thoracic anatomy, physiology and the pathophysiology associated with the condition he or she is dealing with. The aim of this lecture series is to outline an approach to the thoracic surgical patient, describe operative techniques pertinent to surgical conditions of the thorax and the post operative management of the thoracic surgery patient.

### Preoperative Evaluation of the Patient with Thoracic Disease

#### *History taking*

The acquisition of a complete history from the pet owner is essential. The historical features of a disease process along with the physical exam findings will provoke most of the subsequent investigations. Particular attention should be given to:

- Exercise tolerance
- Episodes of collapse
- Coughing
- Nature of any sputum expectorated (blood = haemoptysis)
- Increased noise during breathing
- Change in effort required for breathing
- Change in attitude (lethargy)
- Change in appetite

---

#### \* Daniel J Brockman

The Royal Veterinary College, University of London, Hawkshead Lane, North Mymms, Hatfield, Hertfordshire AL9 7TA, United Kingdom, e-mail: djbrock@rvc.ac.uk

- Vomiting/Regurgitation
- Weight loss

### ***Physical Examination***

Whenever possible the surgeon should perform a complete physical examination of the patient prior to surgery. Aspects of the examination that should be emphasized include:

- Mucous membrane colour and capillary refill time (cranial and caudal body)
- Arterial pulse rate and quality
- Jugular venous distention or pulsation
- Auscultation of the thoracic cavity
- Thoracic palpation and percussion
- Tracheal irritation

### ***Further Diagnostic Tests***

The type of additional diagnostic tests performed will be influenced by the history and physical exam findings but should include:

- Complete blood count
- Serum biochemistry panel
- Thoracic radiographs

Additional information can be obtained by:

- Thoracic ultrasound (echocardiography)
- Electrocardiography
- Arterial blood gas analysis
- Pulse oximetry
- Contrast radiography (barium swallow, angiography etc)
- Thoracocentesis: cytology and culture

### ***Pre-Operative Stabilization***

The surgeon is also responsible for preparing the patient for surgery. It is essential that careful attention is given to the animals medical stability in order to optimize the chance of successful surgical outcome.

- Should medical therapy be instituted prior to surgery, eg diuretics for the PDA patient in congestive heart failure, antimicrobial therapy, anticancer therapy.
- Correct all fluid and electrolyte imbalances
- Nutritional support
- Therapeutic thoracocentesis (pneumothorax, free pleural fluid)
- Therapeutic pericardiocentesis
- Oxygen supplementation (monitor success using blood gas analysis)

### ***Immediate Perioperative Considerations***

- Perioperative antimicrobial prophylaxis: Many thoracic surgical procedures are considered clean and do not require perioperative antibiotics. Opening the airway (trachea, bronchus) is considered clean-contaminated and does justify the use of perioperative antibiotics, however, the author only uses perioperative antibiotics if: surgery time in excess of three hours is anticipated or if there is significant risk of

contamination (Pyothorax, Pneumonia, abscess) or if the animal is going on cardiopulmonary bypass.

- Blood. Because of the proximity of many large vessels, thoracic surgery can be associated with acute blood loss. A source of supplementary blood should be available. If multiple transfusions are anticipated, cross match and/or typed blood is preferable.
- Are the owners sufficiently aware of the risks and potential cost?
- Are the anaesthesia and operating room staff fully informed of their roles in the planned procedure?

## **Surgical Approaches to the Thoracic Cavity in Dogs and Cats**

### ***Surgical Anatomy***

The thoracic cavity is a cage formed by the thirteen pairs of ribs laterally, the thoracic vertebrae dorsally and the sternum and costal cartilages ventrally. The ribs which articulate with the sternum, via a costal cartilage, are called the sternal ribs and are typically 1-9, Ribs 10-12 are called the costal ribs and form the costal arch. The thirteenth rib is a floating rib. The superficial thoracic wall consists of combined muscles: the latissimus dorsi, the serratus, the scalene, and the external abdominal oblique. The deep thoracic wall consists of the ribs and the external and internal intercostal muscles. The intercostal muscles receive segmental innervation and blood supply from the spinal cord and aorta respectively. These nerves and vessels run down the caudal aspect of each rib. The thoracic cavity is separated from the abdomen by a musculotendinous sheet, the diaphragm. The diaphragm receives its innervation from the phrenic nerve which leaves the spinal cord at C<sub>5</sub> and travels through the chest closely associated with the pericardium.

### ***Physiology of the Thoracic Wall.***

The thoracic wall has a combination of active muscular and passive elastic structures. The elastic nature of the thoracic wall can cause an increase or a decrease in the intrathoracic volume depending on the position of the ribs at the time of relaxation. The action of the intercostal muscles is to draw the ribs in a cranial direction, which, because of the “bucket handle” effect results in an increase in thoracic volume. In addition, contraction of the muscular diaphragm, flattens it causing a further increase in thoracic volume. The net effect of the increase in thoracic volume is a reduction in the intrathoracic pressure which creates a pressure gradient down which air flows, via the airway, to fill the lungs and equalize the pressure. The act of expiration, unlike inspiration, is passive. The thoracic wall (and lung tissue) has elastic properties, once the active muscular contractions subside they cause the thoracic volume to return to its resting level.

### ***Effects of Thoracotomy***

Opening the chest allows air to enter the pleural space, preventing the pressure changes required for pulmonary ventilation. Positive pressure ventilation restores pulmonary function but may diminish pulmonary circulation. Intraoperative mechanical restrictions to pulmonary function include atelectasis (collapse) of the lung that is lowermost (lateral

thoracotomy) and packing off of the lungs to increase the surgical exposure. The resultant hypoventilation may cause hypoxemia and hypotension. Stimulation of the vagus nerve during surgery may also induce a bradycardia further contributing to the respiratory and cardiovascular compromise.

### ***Surgical Instruments***

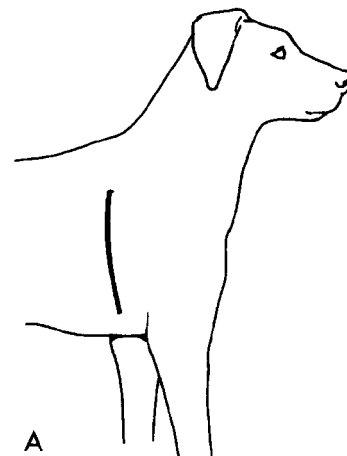
For thoracotomy a routine set of instruments and a selection of different size Finochetto and Burford rib retractors are required. In addition, long handled metzenbaum scissors, Potts scissors, DeBakey needle holders, long handle Mayo-Hegar needle holders, a selection of Satinsky vascular clamps, a selection of angled dissection forceps (Rummel, Mixer, Lahey gall bladder etc), ductus clamps and bronchus clamps are helpful.

### **Surgical Approaches to the Thorax**

#### ***Lateral Intercostal Thoracotomy***

Most frequently used to access intrathoracic structures on one side of the chest. This approach affords only a limited view of the contralateral chest. The opposite side of the thorax, therefore, is not available for surgical manipulations.

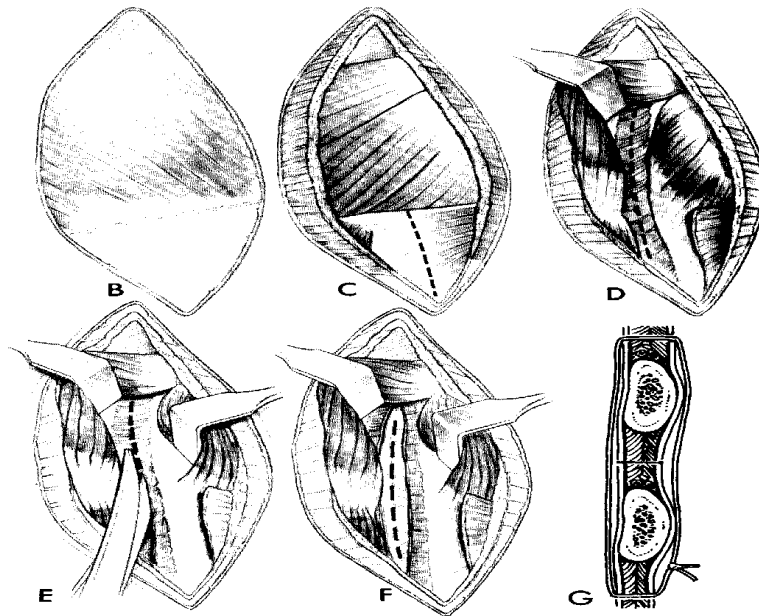
A cranial lateral thoracotomy requires a skin incision just caudal to the scapula and the line of the triceps muscle mass. The incision is continued through the latissimus dorsi to expose the serratus ventralis, scalenus and external abdominal oblique muscles. These muscles are separated to expose the intercostal (external and internal) muscles which are incised to expose the parietal pleura. After the pleura is incised a rib retractor is placed to expose the organs. Closure is accomplished by pre-placing heavy, single interrupted sutures around the ribs immediately cranial and caudal to the incision. After tying the circumcostal sutures, the separated or incised muscle bellies are approximated. Subcutaneous tissue and skin closure are routine.



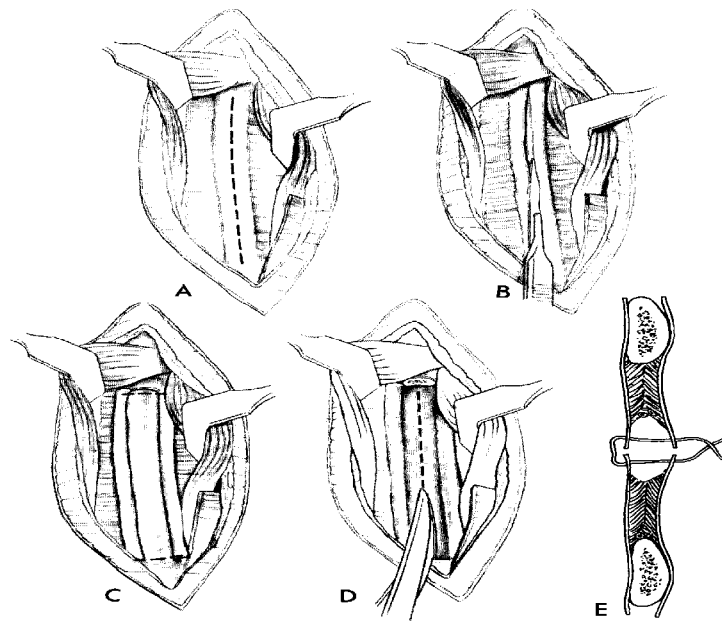
**Figure 1:** Site of skin incision for lateral thoracotomy

#### ***Lateral Rib Resection Thoracotomy***

A subperiosteal resection of a rib permits a wider exposure of the chest and facilitates removal of large masses. Closure is accomplished, in this situation, by placing sutures in the medial and lateral periosteal surfaces between the cranial and caudal edges of the incision



**Figure 2:** Lateral intercostal thoracotomy

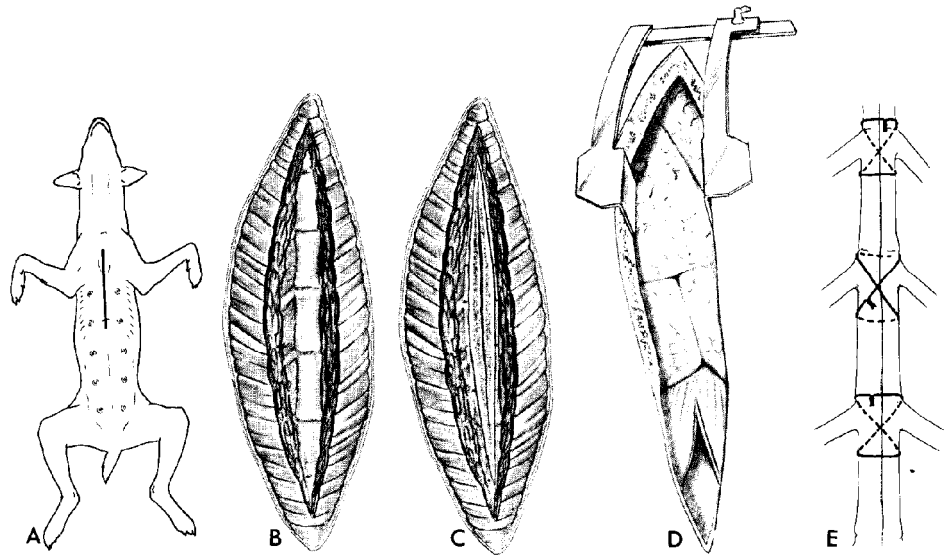


**Figure 3:** Lateral thoracotomy with rib resection.

***Median Sternotomy***

Provides access to both sides of the chest cavity. It may also be combined with a mid-ventral celiotomy incision or a mid-ventral cervical incision. The pectoral muscles are separated from the midline of the sternebrae and the sternum is incised with an osteotome, sternal knife, or oscillating bone saw. Avoid or ligate the internal thoracic arteries. Secure

closure minimizes postoperative discomfort. Stainless steel wire circumsternal sutures in a simple or cruciate pattern are used. A cranial medial sternotomy may be carried laterally as a cranial thoracic wall flap for surgery of the entire trachea, the cranial great vessels, and the cranial thoracic esophagus.



**Figure 4:** Median sternotomy

### ***Trans-Diaphragmatic***

This is a less commonly used surgical approach. It may be used intentionally for the placement of epicardial pacemakers or as a consequence of diaphragmatic rupture. The diaphragm is reconstructed, as required and the laparotomy incision is closed routinely. This approach is not recommended for surgical manipulations inside the thorax, unless it is combined with a median sternotomy incision

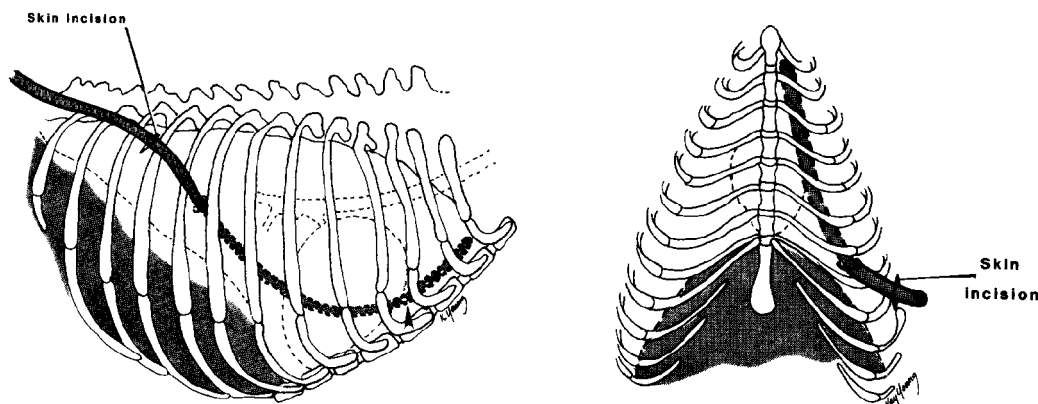
### **Immediate Post-Operative Care**

Prior to closure of any thoracotomy, a thoracostomy tube is placed. The tube is aspirated to remove any air or fluid, thereby reestablishing normal interpleural pressure. The tube is secured with multiple sutures and protected by a light bandage. Care must be taken when placing around the thorax because tight bandages around the thorax can restrict thoracic wall excursions and, therefore, be deleterious to alveolar ventilation.

**Table 1:** Location of intrathoracic structures relative to position of intercostal thoracotomy.

<b>Thoracic Structure</b>	<b>Left</b>	<b>Right</b>
<b>Heart and pericardium</b>	4, 5	4, 5
<b>PDA, PRAA</b>	4 (5)	
<b>Pulmonic valve</b>	4	
<b>Trachea</b>		3
<b>Lungs</b>		
• Cranial lobe	4 - 6	4 - 6
• Caudal lobe	5 (6)	5 (6)
• Intermediate lobe		5
<b>Oesophagus</b>		
• Cranial		3, 4
• Caudal	7 - 10	
<b>Caudal vena cava</b>		7 - 10
<b>Thoracic duct caudal, dog</b>		8 - 10
<b>Thoracic duct caudal, cat</b>	8 - 10	
<b>Diaphragm</b>	7 - 10	7 - 10

Postoperative monitoring should include frequent assessment of the animal's cardiovascular function, respiratory function, and hydration status (see later).



**Figure 5:** Correct position for thoracostomy tube placement.

Animals with thoracostomy tube(s) in place require continuous monitoring. Removal of the end of such a tube by the patient could result in a rapidly fatal pneumothorax. The tube should have a three way tap on the end which is wrapped in antiseptic soaked swab when not in use. It should also be clamped separately using an artery forceps for added security. The whole tube can then be incorporated in a lightly applied chest bandage. If a continuous drainage system is used (pleurovac, water seal collection system or Heimlich valve) all the connections should be kept clean by wrapping them in antiseptic soaked swabs. The entry incision can also be kept clean in a similar manner. Frequency of aspiration of the chest tubes will depend to a certain degree on the disease process for which they are being used. Usually every two hours is sufficient for moderate fluid or gas accumulations. If more frequent drainage is required, a continuous system

may be more advisable. When the amount of fluid or gas aspirated has dropped to around 10ml (for a medium sized dog) each time and if the dog is stable, the tube(s) may be removed.

NB. Placement of drains following thoracotomy is a little easier as long as a few principles are followed. The tube **should not** enter the chest through the thoracotomy incision but caudal to it. A two to three rib space subcutaneous tunnel is ideal. Ensure the drain does not have holes in it which are within the subcutaneous tunnel and remember to place it while the chest is still open so the lung tissue can be protected.

Illustrations and tables adapted from: Orton C Thoracic Wall. In Slatter DH, ed, Textbook of Small Animal Surgery, Philadelphia; W B Saunders 1985,

### Postoperative Patient Care

Thoracotomy patients need postoperative fluid therapy to replace insensible losses as well as losses into the pleural space. A balanced electrolyte solution at a rate of 10 ml/kg/hr is appropriate initially, providing the animal is not in heart failure. The rate should be and composition of fluid should be adjusted according to the nature of the underlying disease(s) and the results of the post-operative patient evaluations. In addition, careful attention should be given to: respiratory function, cardiac function, analgesia and interpleural accumulations of air or fluid. These can all be assessed by the frequent collection of a combination of subjective and objective data.

- 1) Respiratory function.
  - Respiratory rate and effort
  - Mucous membrane colour
  - Thoracic auscultation
  - Arterial blood gas
  - Pulse oximetry
  - Pulmonary artery wedge pressure
  - Thoracic radiographs
  
- 2) Cardiovascular function:
  - Heart rate & rhythm
  - Mucous membrane colour & capillary refill time
  - Pulse rate & quality
  - Direct or indirect arterial blood pressure
  - Central venous pressure
  - Pulmonary artery wedge pressure
  - Cardiac output & SVO<sub>2</sub>
  - ECG
  - PCV/TS/azo/dex
  
- 3) Pleural disease (fluid/air)
  - Auscultation
  - Amount of fluid/air removed via thoracostomy tube(s)

- Thoracic radiography
- Thoracic ultrasound

The intensity of post-operative care required varies for each patient and depends, again, on the age of the animal, nature of the underlying disease, presence of concurrent disease, and the surgical procedure performed. In general any animal with a thoracostomy tube needs constant supervision until such a time that the tube can be removed. The parameters mentioned above should be monitored as frequently as is necessary to make well informed decisions about therapeutic alterations. As parameters stabilize the intensity of observations and acquisition of data should be gradually reduced.