



## CLINICAL REPORT

## Reconstruction of a Severe Mandibular Lip and Chin Avulsion in a Kitten Using Intraosseous-Subcutaneous Suture Technique

Mehdi Behfar ✉, Narges Sufian

Department of Surgery and Diagnostic Imaging, Faculty of Veterinary Medicine, Urmia University, Urmia, Iran.

## ARTICLE INFO

## ABSTRACT

## Article History:

Received: 28 May 2023  
 Revised: 26 June 2023  
 Accepted: 22 July 2023

## Keywords:

Cat  
 Chin  
 Degloving injury  
 Reconstruction

Lip and chin avulsion often results from orofacial trauma that occurs primarily in dogs and cats. Suture placement passing through the skin and around the incisor or canine teeth is the most common reconstructive method in animals. However, the reconstruction would be challenging in young puppies and kittens due to the limited growth of the teeth. A two-month-old kitten was presented for avulsion of a bilateral mandibular lip avulsion following a high-rise syndrome. Oral examination and skull radiographs demonstrated no mandibular fracture. Dental fracture was not observed. After aseptic preparations and under general anesthesia, four intraosseous-subcutaneous sutures using 3-0 nylon were placed to adhere the degloved lip and chin to the mandibular bone. The sutures passed through the both mandibles and the subcutaneous tissue. Then, the labial mucosa and gingiva were opposed by simple continuous sutures using 4-0 Dexon. Post-operative antibiotic and anti-inflammatory were administered. Chlorhexidine mouthwash was recommended for the first five days after surgery. Sutures were removed two weeks later. Infection, abscess formation, necrosis, and dehiscence are the commonly reported complications after lip and chin reconstruction. Using this technique, no complications were observed during a six months period.

## Introduction

Lip avulsion is one of the orofacial traumas in small animals resulting from direct trauma during fighting, and vehicular accidents and falls from a height. The latter cause is known as high rise syndrome which is defined as when a cat falls from a height of two or more stories, resulting in a series of mild to severe injuries.<sup>1</sup>

Avulsions may vary from a slight unilateral tissue detachment to a severe bilateral avulsion extending to the oral commissures. The degree of avulsion and condition of the remaining soft tissues will influence the appropriate repair technique.<sup>2</sup> In minor lower lip avulsion cases, the soft tissue flap can be sutured immediately after irrigation and debridement if needed.

The detached soft tissues can be kept in contact with the mandibular bone using a horizontal mattress suture passing through the skin and around the canine teeth. Alternatively, the sutures can be placed through the labial mucosa, looping around the intact incisor teeth. In case of missing incisor teeth, small holes should be drilled into the alveolar margin and then interrupted sutures are passed through these holes.<sup>3</sup> For severe avulsions, intraosseous sutures from the labial/buccal to lingual aspect of the mandible are recruited. However, there is a risk of damage to tooth roots or permanent tooth buds in immature patients while drilling the mandibular bone in this technique.<sup>2</sup>

This case report describes an alternative technique

✉ Corresponding author. Email: [m.behfar@urmia.ac.ir](mailto:m.behfar@urmia.ac.ir)

© Iranian Veterinary Surgery Association, 2024

<https://doi.org/10.30500/IVSA.2023.399470.1352>



This work is licensed under the Creative Commons Attribution-NonCommercial 4.0 International License. To view a copy of this license, visit <http://creativecommons.org/licenses/by-nc/4.0/>

for lower lip and chin reconstruction using intraosseous-subcutaneous sutures in a Persian kitten.

## Case Description

A two-month-old female Persian kitten (weighing 800 g) was referred to the Veterinary Teaching Hospital of Urmia University (Urmia, Iran) suffering from facial trauma after high-rise syndrome. Upon admission, a complete physical examination was performed. The kitten was alert and responsive. Normal pupil size and symmetry were observed. Also, pupillary light reflexes were bilaterally normal. Nystagmus, ataxia, or other abnormality were not noted during the physical examination. Temperature, pulse and respiratory rates were within the normal ranges. Traumatic palatal defect was not observed. On radiography, no fracture was detected on mandibular and maxillary bones. The kitten was sedated using intramuscular injection of 5 mg/kg ketamine (Alfasan, Woerden, Netherlands) and 0.01 mg/kg acepromazine (Alfasan, Woerden, Netherlands). Physical examination revealed complete rupture of lower lip frenulum. The lower lip and chin detachment was extended to the oral commissures resulting in bilateral mandibular bone exposure. There was no devitalized tissue or gross contamination. No dental damage was detected.

## Treatment and Outcome

The kitten was induced and maintained using intravenous injection of 10 mg/kg ketamine (Alfasan) and 0.5 mg/kg diazepam (Caspian Tamin, Rasht, Iran) and positioned in right lateral recumbency. Then, 20 mg/kg intravenous cefazolin (Exir, Tehran, Iran) and 1 mg/kg intramuscular flunixin meglumine (Erfan Pharmaceutical Co., Tehran, Iran) were injected. The resulting chin pouch was flushed by diluted chlorhexidine solution (Najo, Tehran, Iran). Since no soft tissues were available to hold the sutures on the lower jaw, four transverse canals were drilled thorough both mandibular bodies by manual rotation of 23 gauge hypodermic needles beneath the incisors toward the first premolars leaving sufficient distance to the mental foramina. The needle hubs stood on the left mandibular body. Before suture placement, mandibular periosteum was scraped using a no. 10 scalpel blade to induce adhesion formation between the bone and subcutaneous tissue.

Starting from the most caudal canal, the free end of 3-0 nylon suture (Supa, Tehran, Iran) was first passed through the needle point from right to the left side of mandible in retrograde fashion. Then the hypodermic needle was removed. Using the suture needle, subcutaneous bites were taken from the avulsed chin in right to left direction. The parallel intraosseous-

subcutaneous sutures were pre-placed and tied over the chin skin on the left side.

Then, the labial mucosa and gingiva were opposed by simple continuous pattern using 4-0 Dexon (Supa). Post-operatively, oral administration of 22 mg/kg amoxicillin/clavulanic acid (Afachemi, Tehran, Iran) and 0.1 mg/kg meloxicam (Zahravi, Tehran, Iran) and chlorhexidine irrigation solution were recommended for five days. Sutures were removed 14 days later. No wound dehiscence or sign of infection was noted during a 6-months follow-up period (Figure 1).

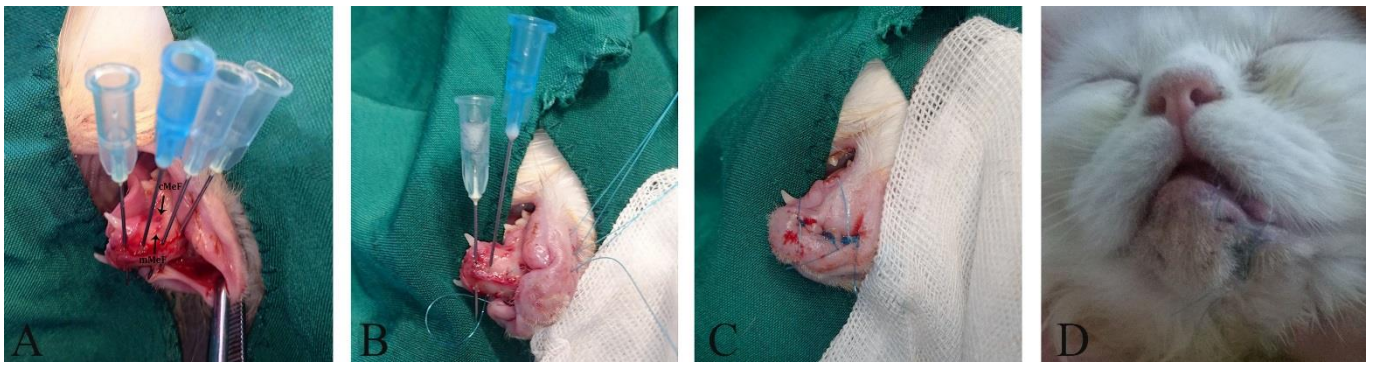
## Clinical Relevance

Lower lip avulsions usually are a result of caudally or laterally directed forces on the lower lip and chin. Avulsions tend to separate at the mucogingival junction or gingiva.<sup>4</sup> The chin usually separates at the junction between the gingiva and the teeth thus, there is usually insufficient tissue remaining on the mandible to ensure a secure repair and in this regard, sutures must be anchored to teeth.<sup>5</sup> Surgical repair of lip avulsion is subjected to failure if the contractive and avulsive forces that tend to pull the chin off the mandible are not taken into consideration. The gingiva is not strong enough to provide sufficient holding power for sutures as the sutures have a tendency to cheese-wire through. To avoid this complication, the sutures need to be anchored around structures like the canine teeth or pass through small holes in the mandible.<sup>5</sup>

Healing through second intention has been recommended as the therapy of choice for younger patients, however, a surgical revision of contracted scar tissue should be scheduled.<sup>6</sup> The use of tissue adhesive in combination with suture placement for the reconstruction of mandibular lip avulsion was also recruited effectively in a cat. Shorter anesthesia time and lower number of sutures needed for reconstruction were reported as the advantages of the technique.<sup>7</sup>

In the present case, due to inadequate dental growth, the procedure was modified as described without any post-operative complications. Although sufficient skin was available for tension free apposition of the lip tissue, incomplete growth of the deciduous incisors of the patient was the limiting factor for the conventional suture repair. Therefore, the intraosseous-subcutaneous suture technique was applied to reconstruct the avulsion. The technique could also be applied in cases with missing incisor/canine teeth due to rostral mandibular fractures.

Reportedly, infection, abscess formation, necrosis, and dehiscence are the common complications of lip and chin avulsion.<sup>8-10</sup> It is believed that healthy feline oral cavity contains aerobic and facultative anaerobic bacteria mainly Gram-positive and non-motile aerobic cocci. Using the described technique, the dead space was



**Figure 1.** (A) Four intraosseous canals were created using 23-G hypodermic needles. mMeF: middle mental foramen, and cMeF: caudal mental foramen. (B) Subcutaneous-intraosseous sutures were pre-placed. (C) All the sutures were knotted. (D) Clinical appearance of the patient after 14 days.

appropriately eliminated. Therefore, the risk of abscess formation was inhibited.

In conclusion, the intraosseous-subcutaneous suture technique was successfully used to reconstruct a severe lip and chin avulsion in the present patient with incomplete growth of deciduous incisors. This technique can be used in cases with missing incisor/canine teeth due to rostromandibular fractures in adults. The technique eliminates the dead space and reduces the risk of abscess formation, which is a common complication following lip and chin avulsion.

### Conflict of Interest

The authors declare no conflict of interest.

### References

1. Vnuk D, Pirkić B, Maticić D, Radisić B, Stejskal M, Babić T, Kreszinger M, Lemo N. Feline high-rise syndrome: 119 cases (1998-2001). *Journal of Feline Medicine and Surgery*. 2004; 6(5): 305-312.
2. Swaim SF. Facial soft tissue injuries. In: Verstraete FJ, Lommer ML, eds. *Oral and Maxillofacial Surgery in Dogs and Cats*. 1st edn. Saunders/Elsevier, Edinburgh, UK, 2012; 243-257.
3. Stanley BJ, Campbell BG, Swaim SF. Facial soft tissue injuries. In: Verstraete FJM, Lommer MJ, Arzi B, eds. *Oral and Maxillofacial Surgery in Dogs and Cats*. 2nd edn. Elsevier, St. Louis, US, 2020; 262-280.
4. Jang K, Chae Y, Yang E, Jo HM, Shim KM, Bae C, Kang SS, Kim SE. Successful surgical treatment of severe lower lip avulsion in two cats. *Journal of Veterinary Clinics*. 2022; 39: 264-271.
5. Langley-Hobbs S, Demetriou J, Ladlow J. *Feline Soft Tissue and General Surgery*. Saunders Elsevier, UK, 2013: 571-586.
6. Rhee S, Colville C, Buchman S. Conservative management of large avulsions of the lip and local landmarks. *Pediatric Emergency Care*. 2004; 20: 40-42.
7. Rathnayake S, Rathnayake RAMK, de Silva DDN. Reconstruction of mandibular lip avulsion in a cat using tissue adhesive and standard wound closure – A case report. *Sri Lanka Veterinary Journal*. 2019; 66(1): 31-33.
8. Saverino KM, Reiter AM. Clinical presentation, causes, treatment, and outcome of lip avulsion injuries in dogs and cats: 24 cases (2001-2017). *Frontiers in Veterinary Science*. 2018; 5: 144.
9. White T. Lip avulsion and mandibular symphyseal separation repair in an immature cat. *Journal of Veterinary Dentistry*. 2010; 27: 228-233.
10. Vicari E, Stepaniuk K. Mandibular lip avulsion repair in the dog and cat. *Journal of Veterinary Dentistry*. 2014; 31 (3): 212-217.