



Iranian Veterinary Surgery Association

Iranian Journal of Veterinary Surgery

Journal homepage: www.ivsajournals.com

Original Article

Evaluation of the Healing Properties of the Crude Extract of *Ocimum gratissimum* Leaves on Excision Wound in Rabbit Bucks

Umeh Ozoemena Ifedioramma¹, Samuel Adeola Babalola^{2*}, Edoga Joseohat Onu³, Chidi Daniel Ifenkwe⁴

¹ Department of Veterinary Surgery and Radiology, College of Veterinary Medicine, Michael Okpara University of Agriculture, Umudike, Abia State, Nigeria. ² Department of Veterinary Medicine, Surgery and Radiology, Faculty of Veterinary Medicine, University of Jos, Plateau State, Nigeria. ³ Department of Veterinary Anatomy, College of Veterinary Medicine, Michael Okpara University of Agriculture, Umudike, Abia State, Nigeria. ⁴ Department of Veterinary Physiology and Pharmacology, College of Veterinary Medicine, Michael Okpara University of Agriculture, Umudike, Abia State, Nigeria.

ARTICLE INFO

ABSTRACT

Article History:

Received 21 December 2021

Revised 6 March 2022

Accepted 4 April 2022

Online 4 April 2022

Keywords:

Ocimum gratissimum

Crude extract

Rabbit bucks

Excision wound

Wound healing

Cicatrín powder

The wound-healing efficacy of the crude extract of *Ocimum gratissimum* leaf was evaluated in excision wound models. The parameters studied included; rate of wound contraction, period of complete epithelialisation in days, dermal toxicity and tensile strength of the excision wound. The means of wound area measurements among treatment animals at different time intervals were compared using one way ANOVA and post hoc test. The level of significance among the means was placed at $p < 0.05$. A significant wound healing efficacy was observed at 100% concentration, better than the Cicatrín wound healing effect. At the reconstituted concentrations of 25% and 50%, their efficacies were comparable to the reference drug used. The *Ocimum gratissimum* leaf crude extract at different reconstitutions was found to be very safe as no dermal toxicity or rash was recorded. The result showed that *O. gratissimum* possesses significant wound-healing activity which was evidenced by decrease in the period of epithelialisation, increase in the rate of wound contraction and skin-breaking tensile strength. It has been established that *O. gratissimum* contains alkaloids (anti-inflammatory and analgesic properties) as well as antimicrobial properties. These may be the lead to their wound healing effects. In conclusion, the use of *O. gratissimum* leaf crude extract at 100%, as a potent wound healing herb which reduces wound healing time and prevents the activities of micro-organism associated wound contamination with no dermal toxicity is hereby recommended. However, further studies need to be carried out to further expound the mechanism of action of *O. gratissimum* in wound healing as well as its systemic effect on animals.

Introduction

Veterinarians who practice emergency medicine are often confronted with wounds that have just occurred.

What Veterinarians do to initially manage these wounds will ultimately determine the overall success or definitive treatment of the wound.¹ Early management of acutely inflicted wounds greatly influences healing

*Correspondence to: Samuel Adeola Babalola, Department of Veterinary Medicine, Surgery and Radiology, Faculty of Veterinary Medicine, University of Jos, Plateau State, Nigeria. Email: adetoyinbabs@gmail.com

www.ivsajournals.com© Iranian Journal of Veterinary Surgery, 2022

<https://doi.org/10.30500/IVSA.2022.320962.1286>



This work is licensed under the Creative Commons Attribution-NonCommercial 4.0 International License. To view a copy of this license, visit <http://creativecommons.org/licenses/by-nc/4.0/>.

and the ultimate outcome.² A wound can be defined as the loss of the continuity of the body structure resulting from an injury. Wound healing therefore, connotes all the physiological and biochemical activities involved in the re-establishment of the continuity of the structure of the body. There seems to be an innate tendency for Veterinarians to apply medicaments to wounds. Whenever a topical agent is applied to a wound, a justifiable reason such as antimicrobial effect, enzymatic debridement, keloid prevention/removal and direct enhancement of healing should be evident.³ Substances possessing both antimicrobial and antibacterial properties which can be conveniently called antibiotics are being used in surgery and in cases of wound management to help prevent and treat infections that may delay wound healing. However, lack of the basic understanding of antibiotic usage may lead to misuse, overuse, improper application and creation of super infection, all to the patient's detriment.⁴ With the development of methicillin-resistant *Staphylococcus species* and other multi-drug resistant bacteria³, it becomes imperative that more research work should be directed towards the unexplored and unexploited domain of herbal remedies. Herbal medicines have been popular for the prevention and treatment of diseases from the ancient times.

In recent years, herbal remedies are used in primary health care with minimum side effects around the world.⁵ Since the earliest times in the history of human kind, the traditional unscientific and unproven clinical trials of different herbs have been very successful. This suggests the development of a trust in the healing power of Nature. This was the basis for this research work aimed at determining the wound healing properties of the aqueous extract of the leaf of the plant, *Ocimum gratissimum*, particularly as it affects the healing time of wound, dermal toxicity, wound tensile strength and scar tissue formation. The plant, *Ocimum gratissimum* (Scent leaf or Basil) which belongs to the family *Lamiaceae* has purportedly been used locally in the management of wounds. It is called Nchuanwu in Igbo language. *Ocimum gratissimum* is rich in alkaloids, tannis, phytates, flavonoids, oligosaccharides and has tolerable cyanogenic content.⁶ The plant contains terpenoids, eugenol, thymol, saponins and alkaloids.⁷ The plant has both economic and medicinal uses. The antimicrobial properties of *Ocimum gratissimum* are mainly against pathogenic strains of Gram positive bacteria (*S. aureus* and *Bacillus spp.*), Gram negative bacteria (*E. coli*, *P. aeruginosa*, *S. typhi*, *K. pneumonia*,

and *P. mirabillis*) and pathogenic fungus (*C. albicans*).⁸ These antimicrobial and antibacterial properties of the Scent leaf are considered very pertinent in its ability to enhance the healing rate of wounds. This claim may be questionable as its validity will depend much on the scientific proof of the effectiveness of the Scent leaf in wound management. In a bid to clear this doubt, a comparative scientific investigation was conducted using the Scent leaf on one hand and the commercially available Cicatrin powder on the other hand,⁹ conducted a study to evaluate the methanolic extract of *Ocimum gratissimum* for its wound healing properties; wound healing property of *Ocimum gratissimum* was determined using the excision wound model. More than 90% wound healing was recorded in the *Ocimum gratissimum* oil extract and Cicatrin powder treated wounds by 14 days post-surgery, whereas 72% healing was observed in the distilled water treated wound. By day 14 post-surgery, the wound areas in the wounds treated with *Ocimum gratissimum* oil extract and Cicatrin powder were 3.75 mm squared and 3.63 mm squared respectively. Throughout the experiment, the percentage healing in the distilled water-treated wound was significantly lower ($p < 0.001$) than those of extract-treated wounds designed a study to access the level of bioactive materials present in *Ocimum gratissimum* with a view to providing preliminary information on their effective doses.⁶ Extract of this plant material showed very high bioactivity at low doses. Aqueous and ethanolic extracts of *Ocimum gratissimum* had ED₅₀ values of 23.98 µg/ml and 26.30 µg/ml, respectively.

Materials and Methods

Research Study Site and design

The study was carried out at the Department of Veterinary Surgery and Radiology, College of Veterinary Medicine, Michael Okpara University of Agriculture, Umudike, Abia State, Nigeria.

Collection and Identification of the Plant

Fresh plants of *Ocimum gratissimum* were collected from Umuokennunu village of Nnentu Ngwa, in Aba South L.G.A of Abia State. The plant leaves were taken to the Department of Forestry, College of Natural and Environmental Management, Michael Okpara University of Agriculture, Umudike for identification and authentication by a herbarium technologist and given the reference No.MOUAU/CNREM/Code: 001518.

*Crude Extraction Method from *Ocimum gratissimum* Leaves*

The leaves of *Ocimum gratissimum* were separated from their stalks after collection. They were washed under running tap water and rinsed with sterile laboratory distilled water. The leaves were allowed to drop the excess water and then weighed to get a total of 1000 g, using an electronic scale with high sensitivity of balance, manufactured by SHREECHEM, PVT. Ltd. India. An electric blender (Hjb-33c made by Home Boss Industrial Group Limited, Guangdong, China) was used to blend the leaves to get the poultice which was then filtered in a commercial sieve by stirring and squeezing to obtain the dark greenish liquid crude extract which amounted to 200 ml.

Experimental Animals

Ethical approval number MOUAU/CVM/REC/2020001 from College of Veterinary medicine, Michael Okpara University of Agriculture, Umudike, Research Ethics Committee for use of experimental animals was granted. Six adult rabbit bucks were used for the experiment. The rabbits were purchased from the Laboratory Animal House, Department of Veterinary Physiology, Michael Okpara University of Agriculture Umudike. The rabbits were kept in hutches in an intensive system of husbandry and left for one week to acclimatize at the laboratory house of the Veterinary College. They were fed with grass and concentrates, with water being provided *ad libitum*.

Acute Dermal Toxicity - Fixed Dose

The dorsal aspect of each rabbit buck was aseptically prepared with Chlorhexidine and the furs of the desired location were clipped and shaving machine. The acute dermal toxicity study was carried out on four adult rabbit bucks by "fixed dose" method of OECD (Organization for Economic Co-operation and Development) Guideline No.434.¹⁰ The acute dermal toxicity was carried out using porous gauze soaked in 5ml of the 100% crude extract and placed on the shaved dorsum of three different rabbits (on the same spot) daily for fourteen days, while the same procedure was carried out using distilled water on the shaved dorsum of a fourth rabbit as control. The shaved areas on the dorsum of the rabbits were observed for any changes in skin colour (rashes, dermatitis or death of the animals).

Method of Wound Induction (Excision Wound Model)

The rabbit bucks used for the Acute Dermal Toxicity Test were left for 14 days to allow for physiological re-adaptation. The total number of rabbit bucks used were six (n = 6).

The rabbits were held and restrained gently, preventing the adrenal gland stimulation due to stress. The furs of the desired location were clipped and shaved with a shaving machine and aseptically prepared as earlier described. Each rabbit buck was then anesthetized using 20 mg/kg of ketamine in conjunction with xylazine at 5mg/kg given intramuscularly.¹¹ About 120 seconds were allowed for anaesthesia to set in. Each animal was restrained at the standard crouching position. The animal skin was kept simply stretched between the fingers and an impression was made on the dorsal thoracic region 1 cm away from the vertebral column and 5 cm away from the ear, to determine the sites for the excision wounds according to the model described.¹¹ With the help of a template having four pairs of circles (12.40 mm in diameter each), eight circular subcutaneous excision wounds (4 excision wounds on either side of the rabbit's dorsum) were made on those marked areas of the anaesthetized rabbit bucks, using a #10 scalpel blade and Allis tissue forceps. Skin of the impressed area was excised to the full thickness to obtain a wound area of about 120 mm². Haemostasis was achieved by blotting the wound with gauze swab soaked in normal saline. A total of forty excision wounds were created on five rabbits that will receive the treatment agents whereas only two excision wounds (one on either side of the dorsum) were created on the sixth rabbit that will serve as the negative control.

Application of Treatment Agents

Five of the six rabbit bucks received 0.5ml of the 25% (1 part of extract into 3 parts of distilled water), 0.5ml of the 50% (1 part of extract into 1 part of distilled water) and 0.5ml of the 100% (raw) crude extract of *Ocimum gratissimum* and 0.5ml of the reference drug (Cicatrion suspension (positive control); 10mg reconstituted in 1ml of sterile water) topically on each of the rabbit excised wounds in an alternate manner daily for 15 days. Each treatment agent was used on ten excision wounds on the five rabbits while distilled water was applied on the wounds on the sixth animal that served as the negative control.

Method of Percentage Wound Area Calculation

Each rabbit buck was restrained in the standard crouching position. The shape of the wound was drawn on a transparent paper, which was then placed on a graph paper and the area on the graph paper calculated as mm squared per unit. The percentage of wound healing was also calculated.

The progressive changes in wound area and contraction, which were indicative of wound healing were planimetrically evaluated on days 5, 10 and 15 post treatment by tracing the wound margin on a millimetre scale graph paper every day¹². The change in healing of wound, i.e. the measurement of wound area on graph paper was expressed as mm² per unit. Wound contraction was expressed as percentage reduction of original wound size. Wound contraction (%) was calculated using the formula:¹²

$$\text{Wound contraction (\%)} = [(WD_0 - WD_t) / WD_0] \times 100$$

Where WD_0 = the wound diameter on day zero; WD_t = the wound diameter on day t.

Determination of Wound Tensile Strength

The wound tensile strength was measured on day 10 by using an improvised constant water flow technique developed.¹³ On the 10th day, the animals were secured to the operation table, under light ether anaesthesia. A line was drawn on the normal skin on either side of wound, 3.0 mm away from the wound line. Two Allis forceps were firmly applied on the lines facing each other. On one side, the forceps was hooked firmly to a block on the operation table, the other forceps was connected to a container attached to a rope suspended down from the table. To measure wound tensile strength, water was poured into the container at a constant velocity using a container with a tap head, as the weight gradually increased, it acted as a pulling force to disrupt the wound. The pouring of the water was stopped as soon as gapping of the wound was observed. The water in the container was emptied into a measuring cylinder and the volume recorded in grams (1 ml = 1 g). Average of six readings was taken from each of the animals.

Collection of Biopsies for Histological Studies

On days 0, 5, 10, and 15, biopsies (about the diameter of 4 mm in size) of the regenerated tissues from designated healing wounds were collected and placed in 10% buffered formalin for histological studies. After section preparation, Haematoxylin and Eosin staining method were used to stain the slides

which were later read under the microscope with 100 magnification lens to observe for changes.

Statistical Analysis

The means (expressed as Mean \pm SE) of wound area measurements among treated animals at different time intervals were compared using one way ANOVA. It was used to examine the mean difference in wound healing among the treated animals, using Graph Pad software. The level of significance among the means was placed at $p < 0.05$.

Results

Every 100 grams of the *O. gratissimum* leaves weighed out, yielded 20 ml (w/v) of crude extract. The result of the dermal acute toxicity showed no traceable skin rash, dermatitis, or even death at the 100% concentration of the crude extract

Wound Contraction/Closure

The progress of the wound closure or wound contraction by the crude extract of *Ocimum gratissimum* at various concentrations (25%, 50%, and 100% w/v), the distilled water (untreated animal) and Cicatrin suspension (standard drug) treated animals are shown in Table 1. A progressive reduction in the areas of the wounds treated with the *O. gratissimum* crude extract in a concentration dependent manner on days 5, 10 and 15.

Percentage Wound Contraction/Closure

The progress of the wound healing induced by *O. gratissimum* crude extract (25%, 50%, and 100% w/v) treated animals, distilled water untreated animal and Cicatrin suspension (standard drug) treated animals are shown in the bar graph (Figure 1).

Table 2 indicates a progressive change in the wound healing effect of *Ocimum gratissimum* crude extract in a concentration dependent manner. It was observed that the wound contracting ability or the percentage wound closure of the extract preparation in different concentrations was significantly ($p < 0.05$) greater than that of the control (untreated) animal. After 5, 10 and 15 days of treatment, 30.00%, 80.66%, and 95.00% wound closures were obtained in the 100% treated portion of the excised wounds respectively. The result obtained on the 15th day with the leaf extract preparation at different concentrations was comparable with the 92.20% wound closure in the standard drug.

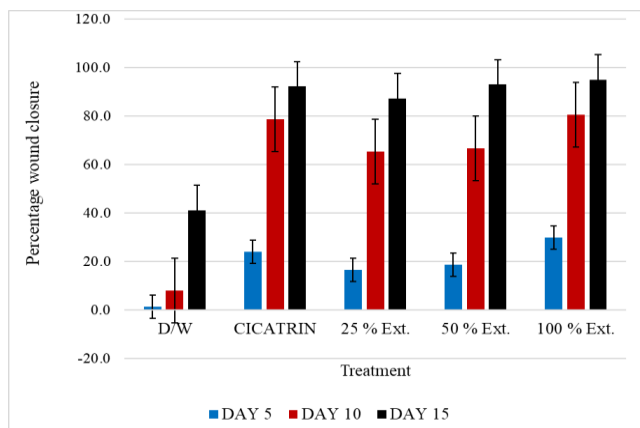


Figure 1. Percentage of wound closure. (Indicates a progressive change in the wound healing effect of *Ocimum gratissimum* crude extract in a concentration dependent manner).

Epithelialisation

Epithelialisation period was monitored by noting the number of days required for “eschar” to fall away, leaving no raw wound or scar tissue behind (Table 3) In the excision wound model, animals treated with the crude extract at the various concentrations showed a significant ($p < 0.05$) decrease in the epithelialisation period when compared with the untreated animal. Treatment with the crude extract at 100% and 50% shows mean epithelisation period of 7 and 8 days respectively compared to 9 days by the standard drug.

Wound Tensile Strength

The result of wound tensile strength of the *Ocimum gratissimum* extract treated animals showed a significant ($p < 0.05$) wound tensile strength in 10 days old wound in a concentration dependent manner compared with the control. The wound gapped when a tensile strength with an equivalent weight of 604.33 ± 15.01 g was attached to the wound treated with 100% (w/w) crude extract, whereas the wound treated with

the standard drug gapped when 399.66 ± 40.75 g weight was attached, compared with the weight of 163.33 ± 7.68 grams that caused the gapping of the distilled water (untreated) wound. The wound tensile strength of the *Ocimum gratissimum* (25%, 50%, and 100% w/w) crude extract treated animals showed a significant ($p < 0.05$) wound tensile strength higher than the control animal. While 100% (w/w) crude extract conferred a significantly better wound tensile strength (604.33 g) than 50% followed by 25%, the wound gapped at a weight of 163.33 ± 7.68 grams in the untreated animal. Both concentrations of the crude extract as well as the standard drug showed a significant increase in tensile strength in the 10 days old wound (Table 4).

Histopathology Slides

The histological studies revealed (Figures 2 to 17) that the wounds treated with distilled water showed a discontinuous epidermis, with mild vacuolization, lesser amount of collagenation and presence of inflammatory cells. The Cicatrin and crude extract-treated wounds showed hyper-granulation with indications of inflammatory cells. Restoration of adnexa, extensive fibrosis and collagen tissue within the dermis was observed. The maturation and remodelling phase of wound healing has decreased cell population, collagen deposition and an increase in granulation tissues. The 100% concentration stimulated significant wound-healing activity by decreasing the period of vacuolization and formation of granulation tissue. The synthesis of collagen by increased rate of wound contraction was compared to the control animal. Accumulation of fibroblast cells was observed in the extract treated wounds, compared to the Cicatrin treated wounds, whereas the inflammatory cells were present in the distilled water treated wound.

Table 1. Rate of Wound Contraction /Reduction of Wound Diameter.

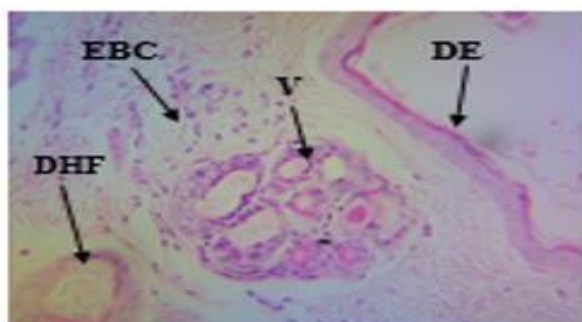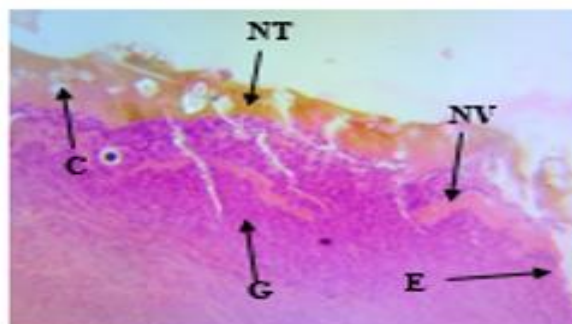
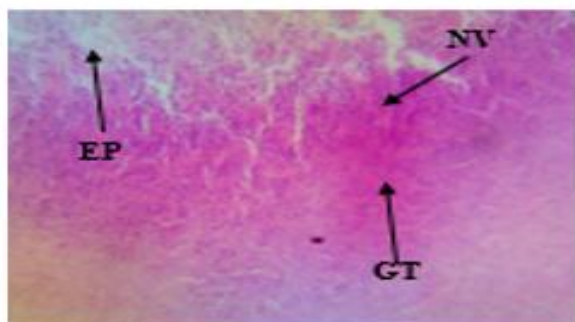
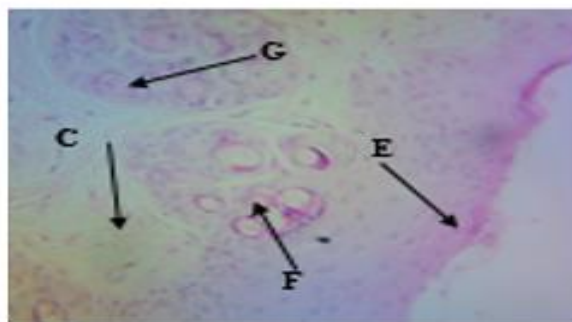
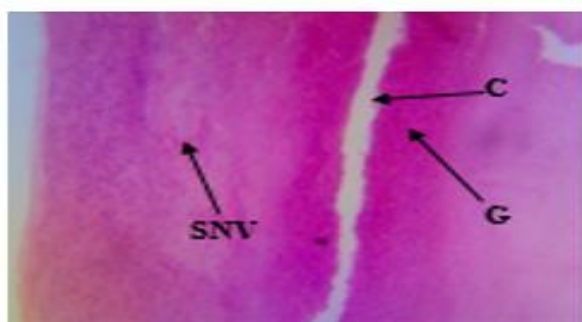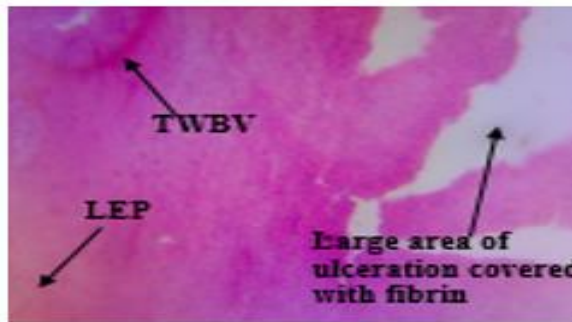
Treatment agents	Day 0	Day 5	Day 10	Day 15
D/water	120.00 ± 0.00	117.38 ± 1.62 ^a	110.60 ± 0.87 ^a	76.62 ± 10.33 ^a
Neomycin Sulphate + Bacitracin Zinc (Cicatrin)	120.00 ± 0.00	90.08 ± 2.39 ^c	23.58 ± 3.80 ^b	11.06 ± 2.47 ^b
25% <i>O. gratissimum</i>	120.00 ± 0.00	101.46 ± 3.12 ^b	43.44 ± 7.95 ^b	15.04 ± 3.76 ^b
50% <i>O. gratissimum</i>	120.00 ± 0.00	98.00 ± 1.97 ^b	41.26 ± 6.99 ^b	9.54 ± 1.92 ^b
100% <i>O. gratissimum</i>	120.00 ± 0.00	83.92 ± 0.49 ^c	21.80 ± 3.52 ^b	6.76 ± 1.36 ^b

Note: Wound area (mm²) presented in mean ± SE. Different superscripts down the columns show significant ($p < 0.05$) differences.

Table 2. Percentage Wound Contraction.

Treatment agents	Day 0	Day 5	Day 10	Day 15
D/water	0.00 ± 0.00	1.33 ± 0.81 ^d	8.00 ± 0.81 ^c	41.20 ± 8.44 ^b
Neomycin Sulphate + Bacitracin Zinc (Cicatrin)	0.00 ± 0.00	24.00 ± 1.24 ^b	78.66 ± 3.88 ^a	92.20 ± 1.88 ^a
25% <i>O. gratissimum</i>	0.00 ± 0.00	16.66 ± 1.82 ^c	65.33 ± 4.24 ^b	87.33 ± 3.47 ^a
50% <i>O. gratissimum</i>	0.00 ± 0.00	18.66 ± 1.33 ^c	66.66 ± 4.94 ^b	93.00 ± 0.97 ^a
100% <i>O. gratissimum</i>	0.00 ± 0.00	30.00 ± 1.48 ^a	80.66 ± 3.55 ^a	95.00 ± 1.17 ^a

Note: Percentage wound closure (%) presented in mean ± SE. Different superscripts down the columns show significant ($p < 0.05$) differences.

**Figure 2.** Before treatment.**Figure 3.** Day 5 (25% *O. gratissimum*)**Figure 4.** Day 5 (50% *O. gratissimum*)**Figure 5.** Day 5 (100% *O. gratissimum*)**Figure 6.** Day 5 (Cicatrin® powder).**Figure 7.** Day 5 (Distilled water)

Figures 2 to 7. The histopathologic results at Day 5 of treatment. **Key:** **Figure 2.** DHF: Damage hair follicle; V: Vacuolisation; DE: Discontinuous epidermis; EBC: Exposed blood vessel. **Figure 3.** CF: Collagen fibre; GT: Granulation tissue; E: Oedema; NV: Neovascularisation; NT: Necrotic tissue. **Figure 4.** EP: Epithelisation; GT: Granulation tissue. **Figure 5.** C, F: Collagen fibre, G: Granulation tissue; **Figure 6.** SNV: Scattered neovascularised tissue; **Figure 7.** TWBV: Thin-walled blood vessel, LEP: Less epithelisation with less collagen.

Table 3. Effect of *O. gratissimum* leaf crude extract on epithelialisation period on excision wound.

Treatment agents	Epithelialisation (days)
D/water	23.80 ± 0.37 ^a
Neomycin Sulphate + Bacitracin Zinc (Cicatrín)	9.60 ± 0.50 ^b
25% <i>O. gratissimum</i>	9.80 ± 0.58 ^b
50% <i>O. gratissimum</i>	8.40 ± 0.60 ^{bc}
100% <i>O. gratissimum</i>	7.00 ± 0.31 ^c

Note: Values are presented in mean ± SE. Different superscripts down the column show significant ($p < 0.05$) differences.

Table 4. Wound tensile strength.

Treatment agents	Wound tensile strength (gram)
D/water	163.33 ± 7.68 ^e
Neomycin Sulphate + Bacitracin Zinc (Cicatrín)	399.66 ± 40.75 ^c
25% <i>O. gratissimum</i>	277.66 ± 14.44 ^d
50% <i>O. gratissimum</i>	482.33 ± 33.39 ^b
100% <i>O. gratissimum</i>	604.33 ± 15.01 ^a

Note: Values are presented in mean ± SE. Different superscripts down the column show significant ($p < 0.05$) differences.

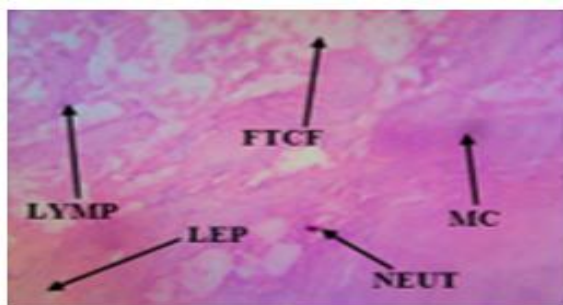
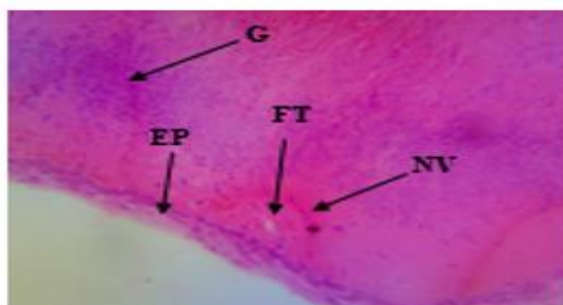
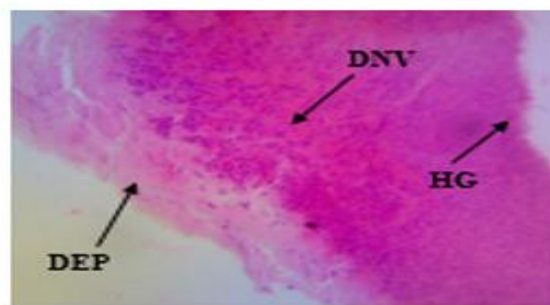
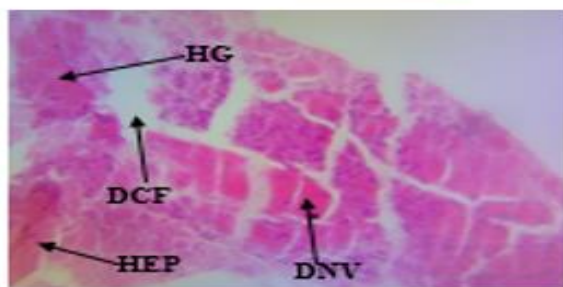
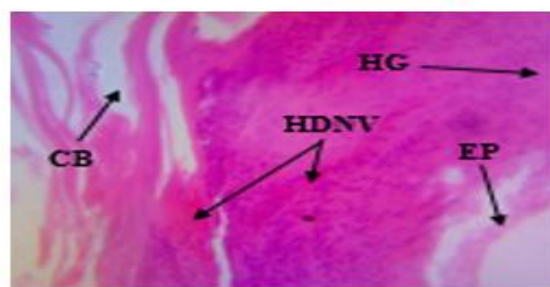
**Figure 8.** Day 10 (Distilled water)**Figure 9.** Day 10 (25% *O. gratissimum*)**Figure 10.** Day 10 (50% *O. gratissimum*)**Figure 11.** Day 10 (100% *O. gratissimum*)**Figure 12.** (Cicatrín ® powder)

Figure 8 to 12. The histopathologic results at Day 10 treatment. **Keys:** **Figure 8.** LYMP: Lymphocytes, FTFCF: Few thick collagen fibre, MC: Mast cell, NEUT: Neutrophils, LEP: Less epithelisation; **Figure 9.** G: Granulation tissue, EP: Epithelisation, FT: Fibrous tissue, NV: Neovascularisation; **Figure 10.** DEP: Dense epithelisation, DNV: Dense neovascularisation, HG: Hypergranulation; **Figure 11.** DCF: Dense collagen fibre, HEP: Higher epithelisation; **Figure 12.** CB: Collagen bands/strands, HDNV: Highly dense neovascularisation.

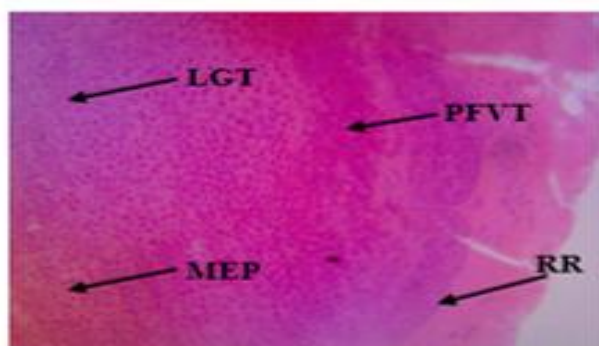


Figure 13. Day 15 (Distilled water)

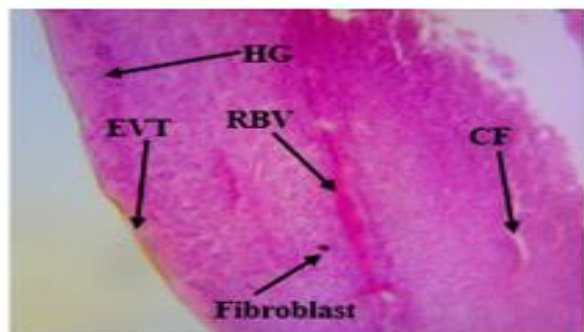


Figure 14. Day 15 (25% *O. gratissimum*)

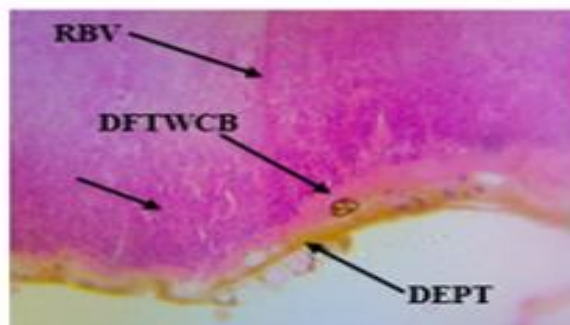


Figure 15. Day 15 (50% *O. gratissimum*)

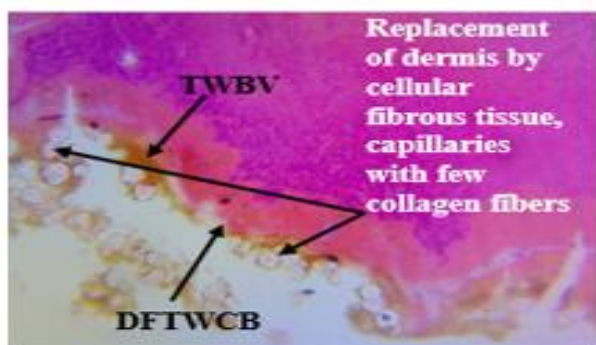


Figure 16. (100% *O. gratissimum*)

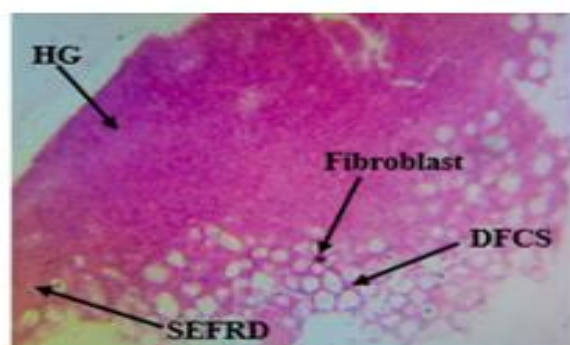

Figure 17. (Cicatrin @ powder)

Figures 13 to 17. The histopathologic results at Day 15 treatment. **Keys:** **Figure 13.** LGT: Less granulation tissue, PFVT: Proliferation of fibrous tissue, MEP: Moderate epithelisation, RR: Rete ridges; **Figure 14.** HG: Hyper-granulation, EVT: Epidermis with varying thickness, RBV: Regenerated blood vessel, CF: Collagen fibre; **Figure 15.** DFTWCB: Dermal fibrous tissue with collagen bands, DEPT: Dense epithelium tissue; **Figure 16.** TWBV: Thick-walled blood vessel present at the base; **Figure 17.** Squamous epithelium with fibrous as replacement dermis.

A significant increase in collagen content due to enhanced migration of fibroblasts and epithelial cells to the wound site was observed during the wound healing process in the treated animals. The wounds treated with the 50% and 100% crude extract preparation of *O. gratissimum* showed focal ulceration, replacement of dermis skeletal muscle by cellular fibrous tissue, capillaries and a few broad collagen fibres.

Discussion

There has been an increase in demand for therapeutic use of some medicinal herbs as an alternative to orthodox, modern health care option in alleviating pains, injury or as wound healers especially for those living in rural areas where primary health care is not easily accessible. The use of medicinal plants for treating various ailments ranging from acute to

chronic conditions has become a way of life for many indigenous people not only in rural communities but also in urban centres. This is largely dependent on the economic factors such as ease of availability, ability to afford them and the strong belief in the therapeutic potentials of plants. Based on regular usage, many indigenous people, especially the traditional herbalists and herb-sellers are very familiar with the different uses, preparations and identification of medicinal plants. This has remained the major source of distributing information (ethno-pharmacology) and prescriptions on medicinal plant remedies in rural communities.^{4,14}

Wounds are physical injuries that resulted in an opening or break of the skin. The most common symptoms of wounds are bleeding, loss of feeling or function below the wound site, heat and redness around the wound, painful or throbbing sensation, swelling of tissue in the area and pus like drainage.¹⁵ Proper healing of wound was essential for the restoration of the disrupted anatomical continuity and functionality status of the skin. It was a product of the integrated response of several cell types to injury. This process is a complex phenomenon and it mainly comprises 3 phases: inflammatory phase, proliferative phase and maturation or remodeling phase. The inflammatory phase is characterized by haemostasis and inflammation, the proliferative phase is followed by epithelialisation, angiogenesis and collagen deposition, while in the maturation phase, the wound underwent contraction resulting in a smaller amount of apparent scar tissue.¹⁶ The application of medicinal concoctions from plants to treat skin lesions and in particular wounds has a long tradition. Plants with wound healing activity have been reported and experimentally studied on various animal models to reveal the most active promising compounds.⁷

The present study evaluated the healing potential of the crude extract from the leaf of *Ocimum gratissimum*. This plant was selected for the evaluation of wound healing activity because of the folkloric claims on its availability, absence of unwanted side effects and high potency of the extract preparations. The phytochemical screening of this plant as reported,¹⁷ revealed the presence of terpenoids, phytosterols, oligosaccharides, phenols, alkaloids, flavonoids and tannins. Terpenoids are known to promote wound healing process, mainly due to their astringent and antimicrobial properties which seem to be responsible for wound contraction and increased rate of epithelialization.¹⁸ Terpenoids

may have great antifungal or antimicrobial potential due to possible effect on the non-mevalonate pathway.

About complete healing was observed on the 15th day in all treated animals while the untreated animal (control) took more than 28 days to achieve same healing state. This result showed that the crude extract of *Ocimum gratissimum* leaf at 100% concentration enhanced rate of wound contraction/ closure and drastically reduced the healing time than in the control. This might be due to enhanced epithelialisation (decreased the epithelialisation period from 24 days to 7 days) when compared with the untreated animal. A better healing pattern and reduction in the period of epithelialisation was observed in all the crude extract treated animals. The result of this study suggested that treatment of excision wounds with crude extract of *O. gratissimum* at 50% and 100% accelerated the wound healing process better than the known (Cicatrín) drug. The epithelialisation of the wound mainly occurs by proliferation and migration of the marginal basal cells lying close to the wound margin. The hematoma within the wound may be replaced by granulation tissue which consists of new capillaries and fibroblasts. The fibroblasts are responsible for the production of mucopolysaccharide ground substance. The lymphatics develop new nerve fibres. This finding is similar to the observation made by some researchers,^{17,19-22} who in their various findings reported significant decrease in epithelialisation using herbal formulations such as *Aloe vera*, *Jatropha luras leaves*, *Centella asiatica*, *Nelumbacucifera* etc. Hence, the *O. gratissimum* leaf crude extract could be described as a promoter of wound healing. It is suggestive that the leaf extract preparation of *O. gratissimum* acts as a stimulant for wound healing because it has polyphenols and flavonoids as active constituents.

Bacitracin, which is one of the active ingredients in Cicatrín powder, is bactericidal. It interferes with bacterial cell wall synthesis by preventing the phosphorylation of bactoprenol, a lipid protein that transports peptidoglycan outside the plasma membrane of most bacteria to form a mesh-like layer that constitutes the cell wall.²³ Without the active phosphorylated bactoprenol, peptidoglycan synthesis cannot be completed and the bacterial cell wall lyses. By this process, Bacitracin inhibits the growth and multiplication of bacteria on wounds, leading to enhanced wound healing rate. From the study, it was observed that the epithelialisation periods for the wounds treated with both the Cicatrín powder and the

different concentrations of the *O. gratissimum* leaf crude extracts were significantly different with that of the distilled water treated animal. It can therefore be deduced from the foregoing that the *O. gratissimum* leaf crude extract has probably similar mechanism of action and strength of action as the Cicatrin on wound healing. That is, inhibition of bacteria cell wall synthesis. After injury, revascularization of the wound bed and redevelopment of the extracellular matrix are achieved through cell proliferation and the production of granulation tissue. Wound contraction, a part of the proliferative phase of wound healing, occurs through the centripetal movement of the tissues surrounding the wound, which is mediated by myofibroblasts.²⁴ A significant increase in collagen content due to enhanced migration of fibroblasts and epithelial cells to the wound site was observed during the wound healing process in the treated animals. This result strongly agreed with other reported studies with *Aloe vera*, *Centella asiatica*, *Nelumba nucifera*, *Gingko biloba*, *Eucalyptus*.²⁵⁻³⁰

The wound tensile strength of the *O. gratissimum* (25%, 50% and 100% w/v) crude extract treated animals was significantly ($p < 0.05$) higher than the control in a concentration dependent manner. The high tensile strength observed with the 100% treated wound suggests an increased wound healing cells, hence giving high tensile strength to the Eschar tissue. A similar observation was reported using *Gingko biloba*,¹⁹ and *Xylopi aetiopica*.²¹

In the histological studies, lesser epithelialisation and lesser collagen formation indicate incomplete wound healing in the distilled water untreated animal. The wounds treated with the 50% and 100% crude extract preparations of *O. gratissimum* showed focal ulceration, replacement of dermis skeletal muscle by cellular fibrous tissue, capillaries and a few broad collagen fibres. This implies that the wound had completely healed and is covered by stratified squamous epithelium. The wound portion treated with the standard Cicatrin preparation showed dermal fibrosis with collagen strands and bands. The wound was covered with squamous epithelium with a fibrous replacement of the dermis which signified complete wound healing whereas the wound portion treated with the 25% crude extract preparation of *O. gratissimum* showed a focus of cellular fibrous tissue with capillaries and wavy collagen fibres replacing the dermis and skeletal muscle. The epidermis over this is thick with few rete ridges and focal ulceration. The

fibrous replacement in the dermis shows moderate wound healing.

In conclusion, the topical application is an efficient therapeutic method because the availability of the drug at the wound site leads to enhanced wound healing activity. The *O. gratisimum* leaf crude extract for wound healing perhaps improved circulation by stimulating blood flow for a better oxygen and nutrients delivery to the wound area as well as providing cleansing to prevent contamination, helped to reduce the risk of delayed wound healing and enhanced the healing process. The enhanced capacity of wound healing with this plant could be on the basis of anti-inflammatory and anti-microbial effects of the plant which have been reported by previous researchers. The extract at 50% and 100% topical applications showed better results than the reference drug Cicatrin treated wound portion, though both the 50% and the reference drug recorded similar epithelialisation period.

Conflict of Interest

No potential conflict of interest was reported by the author(s).

References

1. Moore M. Wound assessment. Wound Care Education Institute. 2013.
2. Baranowski S, Ayello E. Wound care essentials. 3rd edition. Lippincott, Williams & Wilkins. 2011; 15-25.
3. Ishiwu CN, Umenwanne CP, Obiegbuna JE, Uchegbu NN. *In Vitro* assessment of antibacterial effect of extracts of *Ocimum gratissimum* and *Carica papaya* leaves. *Internal Journal of Applied Science and Technology*. 2014; 4 (1): 171-176.
4. Hanks J, Spodnick G. Wound healing in the veterinary rehabilitation patient. *Veterinary Clinics of North America: Small Animal Practice*. 2005; 35: 1453-1471.
5. Pan S, Litscher G, Gao S. Historical perspective of traditional indigenous medical practices: the current renaissance and conservation of herbal resources. *Evidence-Based Complement Alternative Medicine*. 2014; 84: 967-976.
6. Ijeh II, Njoku OU, Ekenza EC. Medicinal evaluation of *Xylopi aethiopica* and *Ocimum gratissimum*, *Journal of Medicinal Aromatis Science*. 2004; 26 (1): 45-46.
7. Deeptanjali S, Ajay K. Secondary metabolites of *Ocimum gratissimum* and their biological activities. *International Research Journal of Pharmacology*. 2013; 4(8):10-28.
8. Matasyoh LG, Matasyoh JC, Wachira FN, Kinyua MG, Thairu MAW, Mukiyama TK. Chemical composition and antimicrobial activity of the essential oil of *Ocimum gratissimum* L. growing in eastern Kenya. *African Journal of Biotechnology*. 2007; 6(6): 760-765.
9. Chah KF, Eze CA, Emuelosi CE, Esimone CO. Antibacterial and wound healing properties of methanolic extracts of some Nigerian medicinal plants.

- Journal of Ethnopharmacology*. 2006; 104: 164-167.
10. OECD. OECD guideline for testing of chemicals: acute dermal toxicity 402. 1987; Available at: http://www.oecd.org/document/22/0,2340,en_2649_34377_191605_4_1_1_1_1,00,html.
 11. Paul F. Laboratory animal anaesthesia 4th Edition. 2015.
 12. Chandra J, Murthy MS, Ranjana R. Evaluation of the wound healing activity of caesalpinia bonducella and cyclea peltata extracts in experimentally induced diabetic rats. *International Journal of Pharmacy and Pharmaceutical Sciences*. 2017; 9(10): 5-8.
 13. Lee KH. Studies on mechanism of action of salicylates II. Retardation of wound healing by aspirin. *Journal of Pharmaceutical Sciences*. 1968; 57: 1042-1043.
 14. Dernel WS. Initial wound management. *Veterinary Clinics of North America: Small Animal Practice*. 2006; 36: 713-738.
 15. Gerald C, Walker MW, Criscione L, Gustafson EL, Batzl-Hartmann C, Smith KE, Vaysse P, Durki MM, Laz TM, Linemeyer DL, Schaffhauser AO, Whitebread S, Hofbauer KG, Taber RI, Brancheck TA, Weinshank RLA. Receptor subtype involved in neuropeptide-Y-induced food intake. *Nature*. 1996; 382:168-171.
 16. Bonner J. Scar Wars. *Chem Ind (Lond)*. 2000; 23:770-3.
 17. Nayak BS, Sandiford S, Maxwell A. Evaluation of the wound-healing activity of ethanolic of *Morinda Citrifolia* L. leaf. *Evidence Based Complement Alternative Medicine*. 2009; 6: 351-356.
 18. Henry G, Garner WL. Inflammatory mediators in wound healing. *Surgical Clinics of North America*. 2003; 83:483-507.
 19. Suguna L, Singh S, Sivakumar P, Sampath P, Chandrakasan G. Influence of *Terminalia chebula* on dermal wound healing in rats. *Phytotherapy Research*. 2002; 16: 227-231.
 20. Udupa SL, Shetty S, Udupa AL, Somayaji SN. Effect of *Ocimum sanctum* linn. on normal and dexamethasone suppressed wound healing. *Indian Journal of Experimental Biology*. 2006; 44: 49-54.
 21. Raina R, Prawez S, Verma P, Pankaj N. Medicinal Plants and their role in wound healing. *Veterinary Scan*. 2008; 3: 1-24.
 22. Jull AB, Cullum N, Dumville JC, Westby MJ, Deshpande S, Walker N. Honey as a topical treatment for wounds. *Cochrane Database of Systematic Reviews*. 2015; 3 (3): 50-83.
 23. Hosgood G. Wound repair and specific tissue response to injury. In: *Textbook of Small Animal Surgery*, 3rdedn. D Slatter WB Saunders, Philadelphia. 2003; 66-86.
 24. Chitra P, Sajithlal GB, Chandrakasan G. Influence of Aloe vera on collagen turnover in healing of dermal wounds in rats. *Indian Journal of Experimental Biology*. 1998; 36: 896-901.
 25. Kumar S, Parmeshwaraiiah S, Shivkumar HG. Evaluation of topical formulations of aqueous extract of *Centella asiatica* on open wounds in rats. *Indian Journal of Experimental Biology*. 1998; 36: 569-572.
 26. Mukherjee PK, Suresh B. Studies on *in Vivo* wound healing activity of leaf extract of *Hypericum mysorense* with different wound models in rats. *Natural Product Science*. 2000; 26: 73-78.
 27. Shetty BS, Udupa SL, Udupa AL, Somayaji SN. Effect of *Centella asiatica* L. (Umbelliferae) on normal and dexamethasone suppressed wound healing in Wistar albino rats. *Journal of Lower Extremity Wounds*. 2006; 5: 137-143.
 28. Bairy KL, Rao C M. Wound healing profile of *Ginkgo biloba*. *Journal of National Remedies*. 2001; 25-27.
 29. Jaswanth A, Loganathan V, Manimaran S, Rukmani S. Wound healing activity of *Aegle marmelos*. *Indian Journal of Pharmaceutical Science*. 2001; 63: 41-44.
 30. Hukkeri VT, Karadi RV, Akki KS, Savadi RV, Jaiprakash B, Kuppast J, Patil MB. Wound healing property of *Eucalyptus globulus* leaf extract. *Indian Drugs*. 2002; 39: 481-483.