



Iranian Veterinary Surgery Association

## IRANIAN JOURNAL OF VETERINARY SURGERY

Journal homepage: [www.ivsajournals.com](http://www.ivsajournals.com)

### ORIGINAL ARTICLE

## Evaluation of Application of Chitosan/Nano Sodium Selenite Biodegradable Film on Full Thickness Excisional Wound Healing in Rats

Hawdam Rostami<sup>1</sup>, Rahim Mohammadi<sup>1,\*</sup>, Siamak Asri-Rezaei<sup>2</sup>, Aliasghar Tehrani<sup>3</sup>

<sup>1</sup> Department of Surgery and Diagnostic Imaging, Faculty of Veterinary Medicine, Urmia University, Urmia, Iran

<sup>2</sup> Department of Internal Medicine and Clinical Pathology, Faculty of Veterinary Medicine, Urmia University, Urmia, Iran

<sup>3</sup> Department of Pathobiology, Faculty of Veterinary Medicine, Urmia University, Urmia, Iran

Received: 6 January 2018

Accepted: 27 May 2018

Available Online: 18 July 2018

#### Keywords:

Wound healing;  
Full thickness;  
Chitosan-nanoselenium;  
Selenium nanoparticles;  
Rat.

#### Abstract

**Objective-** This study aimed at evaluation of histopathological findings of application of chitosan- nano selenium biodegradable film on full thickness excisional wound healing in rats.

**Design-** Experimental Study

**Animals-** Seventy-two male Wistar rats

**Procedures-** Animals were randomized into six groups of 12 animals each. Group I: Animals with created wounds and no further treatment. Group II: Animals with wounds were dressed with chitosan film only. Group III: Animals with wounds were treated with sodium selenite. Group IV: Animals with wounds were treated with sodium selenium nanoparticles. Group V: Animals with wounds were dressed with chitosan/ sodium selenite film. Group VI: Animals with wounds were dressed with chitosan/nano sodium selenite film.

\* Correspondence to: Rahim Mohammadi, Department of Surgery and Diagnostic Imaging, Faculty of Veterinary Medicine, Urmia University, Nazloo Road, Urmia, 57153 1177, Iran.

E-mail: [r.mohammadi@urmia.ac.ir](mailto:r.mohammadi@urmia.ac.ir)

[www.ivsajournals.com](http://www.ivsajournals.com) © Iranian Journal of Veterinary Surgery, 2018

This work is licensed under the terms of the Creative Commons Attribution (CC BY-NC 4.0)

DOI: 10.22034/IVSA.2018.113760.1135

**Results-** There were significant differences in comparisons of group VI and other groups, particularly in terms of cellular infiltration and neovascularization. During the study period, scores for neovascularization was significantly higher in group VI rats than other groups ( $P < 0.05$ ). Polymorphonuclear (PMN) and mononuclear (MNC) cell count and fibroblast cell proliferation in group VI were significantly higher than those of other experimental groups ( $P < 0.05$ )

**Conclusion and Clinical Relevance-** Chitosan/nano sodium selenite biodegradable film resulted in significant improvement in histopathological indices in full thickness wound healing. Thus, from this study it could be concluded that chitosan/nano sodium selenite biodegradable film have a reproducible wound healing potential and hereby justifies its use in practice.

## 1. Introduction

Wound healing involves continuous cell-cell interaction and cell-matrix interactions that allow the process to proceed in different overlapping phases and processes including inflammation, wound contraction, re-epithelialization, tissue remodeling, and formation of granulation tissue with angiogenesis. The phases of wound healing normally progress in a predictable, timely manner, and if they do not, healing may progress inappropriately to either a chronic wound such as a venous ulcer or pathological scarring such as a keloid scar.<sup>1</sup>

Well-designed scaffold with a suitable porous structure can support cell migration and guide vascular infiltration, making it an ideal dermal substitute for wound regeneration. Several *in vitro* studies that focused on determining the optimal mean pore size of collagen-based scaffolds indicated that large pores ( $\geq 250 \mu\text{m}$ ) favor cell attachment, proliferation and migration.<sup>2</sup>

The basic strategy of engineered tissue regeneration is the construction of a biocompatible scaffold that, in combination with living cells and/or bioactive molecules, replaces, regenerates, or repairs damaged tissues. The scaffold should possess suitable properties, like biocompatibility, controlled porosity and permeability, and, additionally, support for cell attachment and proliferation. This artificial “dermal layer” needs to adhere to and integrate with the wound, which is not always successful for the current artificial dermal analogues available.<sup>3</sup>

Chitosan is three-high-molecular weight natural polymer. It is nonpoisonous; it can accelerate wound healing, reduce blood cholesterol levels, stimulate the immune response and can be biologically decomposed. It has a stronger antimicrobial property compared to chitin in avoiding fungi because it has an active group that will bind to microbes, so it can inhibit microbial growth. Another interesting detail was the low activity of carboxymethyl chitosan against the fungal species. The authors concluded that the polycationic character of chitosan is crucial for antifungal activity, because this functional group masks the cationic amino groups.

Chitosan has a good chemical reactivity because it has a number of hydroxyl (OH) and amine groups (NH<sub>2</sub>) attaching to its chain. One of its important characteristics is that it has a positive charge in acidic solution. The substance is a stronger antifungal factor compared to chitin. In addition, chitosan is polycationic, so it can be used as a clotting agent.<sup>4-6</sup> An increasing number of products emerging from the application of nanotechnology to the science of wound healing is currently under clinical investigation. The nanoscale strategies, both carrier, drug related and scaffold target the main phases of wound repair.<sup>7</sup>

During the last years, nanoparticles have emerged as important platforms to treat skin wounds. Silver, gold, and copper nanoparticles, as well as titanium and zinc oxide nanoparticles, have shown potential therapeutic effects on wound healing.<sup>8</sup> Due to their specific characteristics, nanoparticles such as nanocapsules, polymersomes, solid lipid nanoparticles, and polymeric nanocomplexes are ideal vehicles to improve the effect of drugs (antibiotics, growth factors, etc.) aimed at wound healing. On the other hand, if active excipients are added during the formulation, such as hyaluronate or chitosan, the nanomedicine could significantly improve its potential. In addition, the inclusion of nanoparticles in different pharmaceutical materials may enhance the beneficial effects of the formulations, and allow achieving a better dose control.<sup>8</sup>

Selenium is one of the essential trace elements for humans. The bioavailability of Se is related to its different chemical species. Recently, elemental selenium nanoparticles are attracting more and more attention due to their excellent high biological activity and lower toxicity.<sup>9</sup> Elemental selenium nanoparticles in liquid phase can be used as the materials for medical purposes.<sup>10</sup> For these applications, it is important to have good stability of elemental selenium nanoparticles in liquid phase. One of the effective methods for stability of nanoparticles in liquid phase is to add modifiers. Bai et al.,<sup>11</sup> used the chitosan as modifiers for the fabrication of elemental selenium nanoparticles.

This study aimed at evaluation of histopathological findings of application of chitosan- nano selenium biodegradable film on full thickness excisional wound healing in rats.

## 2. Materials and Methods

The study was approved by the institutional animal research ethics committee and 3R's principles were strictly followed. Seventy-two adult healthy male Wistar rats weighting 200– 250g were used and housed in individual cages under room temperature and humidity with natural light/dark cycle, and had *ad libitum* access to chow and water throughout the study.

### Preparation of chemicals

Chemicals were all analytical grade. Double distilled water was used throughout the experiment to prepare the solutions. All the aqueous solutions were stored at 4 °C and filtrated by the

0.45 µm microvoid filter film before used. The solution of Se (IV) was prepared by dissolving SeO<sub>2</sub> in double distilled water.

### Preparation of chitosan- nano selenium biodegradable matrix

Water-soluble chitosan solution was prepared using a method described by others.<sup>12</sup> Briefly, Medium molecular weight crab shell chitosan was dissolved (~400 kDa, 85% deacetylated, Sigma- Aldrich St. Louis, MO, USA) into an aqueous solution (1% v/v) of glacial acetic acid (Merck, Germany) to a concentration of 2% (w/v) while stirring on a magnetic stirrer-hot plate. The solution was stirred with low heat (50° C) for 3 hours. The resultant chitosan solution was filtered through Whatman filter paper after vacuum filtration to remove any un-dissolved particles. For the preparation of elemental selenium nanoparticle sol, 1.5 mL 0.227 mol/L Vc was mixed with 1.0 mL 2.40 mol/L acetum, then the appropriate amounts of 5.36 mmol/L Se (IV) solution was added into the mixtures, the mixed solution was diluted to 10 mL. For the preparation of selenium nanoparticle-chitosan solution, appropriate amounts of chitosan solution was mixed with 1.5 mL 0.227 mol/L Vc and 1.0 mL 2.40 mol/L acetum, respectively. The appropriate amounts of 5.36 mmol/L Se(IV) solution was added into the mixtures, then the mixed solution was all diluted to 10 mL. Philips diffractometer was used to obtain X-ray diffraction pattern. X-ray diffraction (XRD) patterns were acquired from  $2\theta=10^\circ$  to  $80^\circ$  using Cu K $\alpha$ 1 radiation. (Fig. 1). Transmission electron microscope (Philips ES 30 KW0) was used to determine size of nanoparticles (Fig. 2).

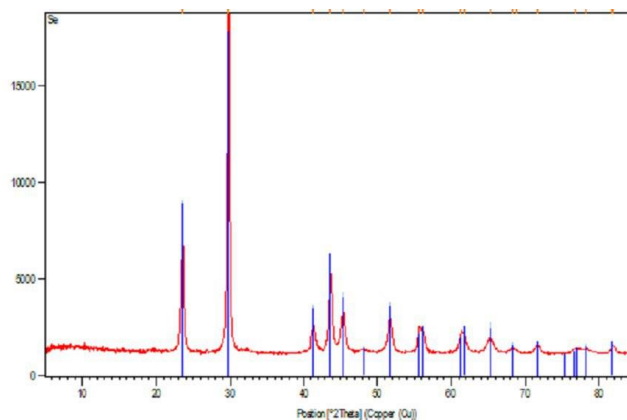


Figure 1. XRD pattern of elemental selenium nanoparticle.



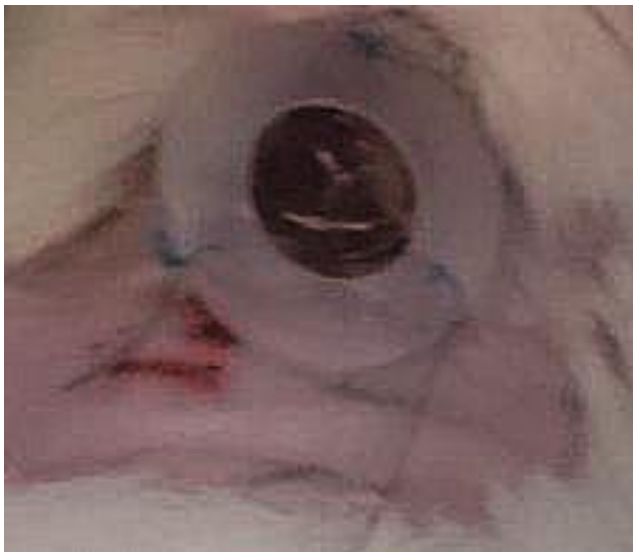
Figure 2. TEM image of elemental selenium nanoparticle shows sizes of the nanoparticle were in the range of 50 nm.

### Study design and animal grouping

Assessment of the healing process was based on excision and histopathological studies 7, 14, and 21 days after surgery the rats were randomly selected and allocated into six groups of 12 rats each. A power calculation based on earlier studies suggested that 4 animals in each subgroup would be sufficient to detect a statistically significant difference in histomorphometric analyses, which was the primary outcome in this study. Group I: Animals with created wounds and no further treatment. Group II: Animals with wounds were dressed with chitosan film only. Group III: Animals with wounds were treated with sodium selenite. Group IV: Animals with wounds were treated with sodium selenium nanoparticles. Group V: Animals with wounds were dressed with chitosan/ sodium selenite film. Group VI: Animals with wounds were dressed with chitosan/nano sodium selenite film. The treatments were performed on a daily basis for 3 days.

### ***The procedures for wound creation and wound infection***

Rats were anesthetized by an intraperitoneal injection of ketamine (Alfasan – Holland) (70 mg/kg of b.w.) and xylazine (Alfasan – Holland) (5 mg/kg of b.w.), the hair on their back was shaved and the skin cleansed with 70% alcohol solution. Following shaving and aseptic preparation, a circular excision wound was made by cutting away a full thickness of 10 mm in diameter excision circle wounds extending through the panniculus carnosus using a 10 mm dermal biopsy with homemade sterile punch. The selected model of wound creation was based on similar works of others. A doughnut -shaped 0.5mm-thick silicone splints with inner diameter of 10 mm was made and centered and then fixed to the skin with both immediate bonding adhesive and 4-0 nylon interrupted sutures. The rats were placed in their individual cages warmed by a heater and allowed to recover fully from anesthesia (Fig. 3).



**Figure 3.** A doughnut -shaped 0.5mm-thick silicone splints with inner diameter of 10 mm was made and centered and then fixed to the skin with both immediate bonding adhesive and 4-0 nylon interrupted sutures.

### ***Histological preparation and quantitative morphometric studies***

The tissue samples were taken on 7, 14, 21 days after surgery from periphery of the wound along with normal skin and fixed in 10% buffered formalin, dehydrated and

embedded in paraffin wax, sectioned at 5  $\mu$ m and stained with hematoxylin and eosin (H&E) stains. Photomicrographs were obtained under light microscope to assess the predominant stage of wound healing. Three parallel sections were obtained from each specimen. Cellular infiltration including the number of mononuclear cells, polymorphonuclear cells and fibroblastic aggregation were quantitatively evaluated.

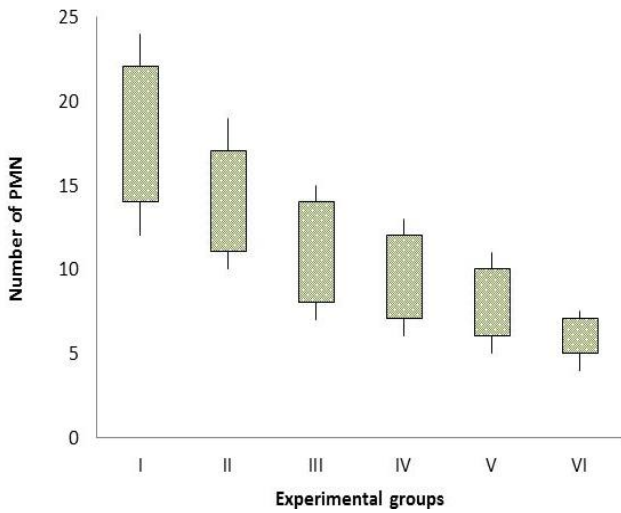
### **3. Statistical Analysis**

Differences among groups were evaluated by Kruskal–Wallis variance analysis. When the P-value from the Kruskal–Wallis test statistics was statistically significant, multiple comparison tests were used to know differences. Student’s t-test was used for evaluation of test results. SPSS 11.5 (SPSS Inc., Chicago, IL, USA) was used for statistical analysis. A P-value was set at 0.05.

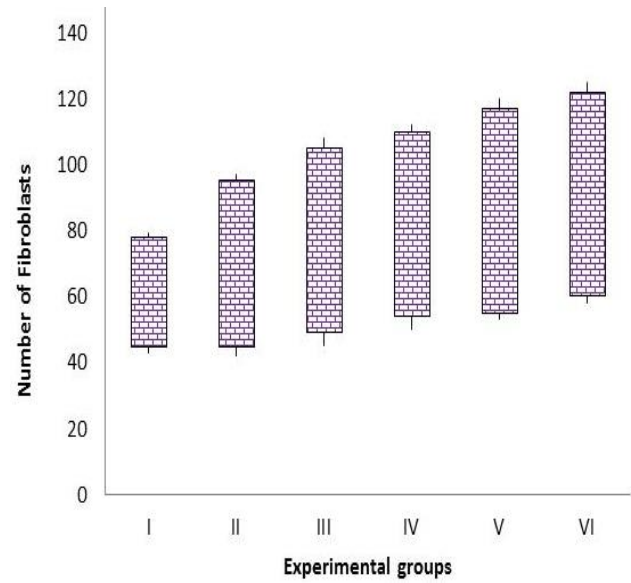
### **4. Results**

#### ***Histological and morphometric findings***

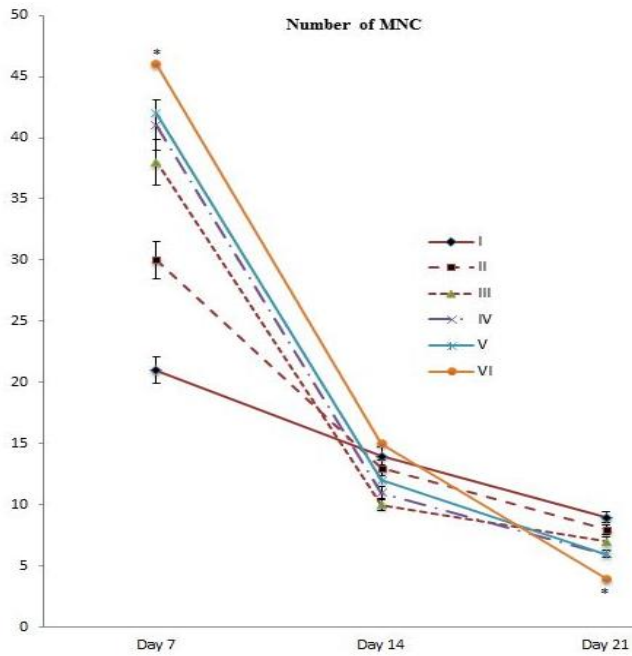
There were significant differences in comparisons of group VI and other groups, particularly in terms of cellular infiltration. Polymorphonuclear (PMN) and mononuclear (MNC) cell count and fibroblast cell proliferation in group VI were significantly lower than those of other experimental groups ( $P < 0.05$ ). Sample from the 6 groups were collected on 7, 14, 21 days after wound induction for histopathological examination. In group VI on the day 7 after injury showed fewer polymorphonuclear cells, however, better mononuclear cell infiltration and had more rapid reepithelization. Maximum accumulation of fibroblasts was observed on day 7 and reduced in density until day 21. There was a significant increase ( $P < 0.05$ ) in mononuclear cell and fibroblast proliferation, however, reduced number of inflammatory cells on day 14 and 21 in group treated with Chitosan/Nanoselenium when compared to other groups. Findings on day 14 after injury revealed a better epithelialization with more rete ridges and dermal papillae and more developed dermal matrix in comparison with the other groups. On day 21 after injury, intense collagen deposition was found in different groups, however, group treated with Chitosan/Nanoselenium showed more organized collagen formation and less cellularity (Figs. 4-8).



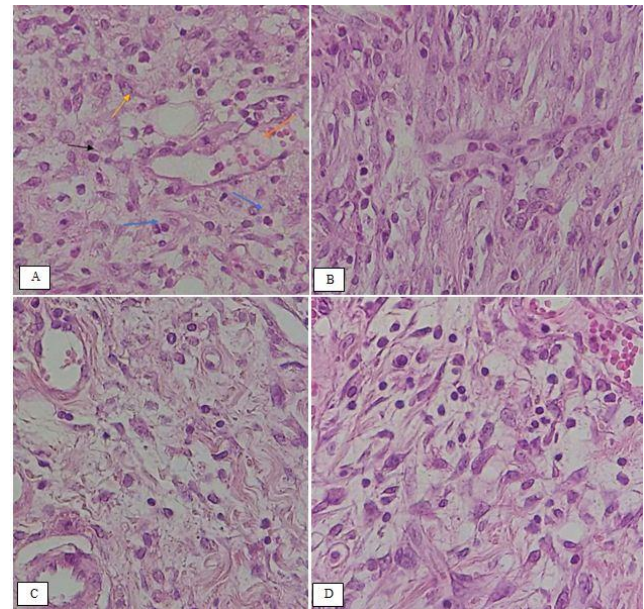
**Figure 4.** Box-and-whisker plots of number of polymorph nuclear cells in excisional model of the rat's skin in experimental groups. Results were expressed as mean  $\pm$  SEM.



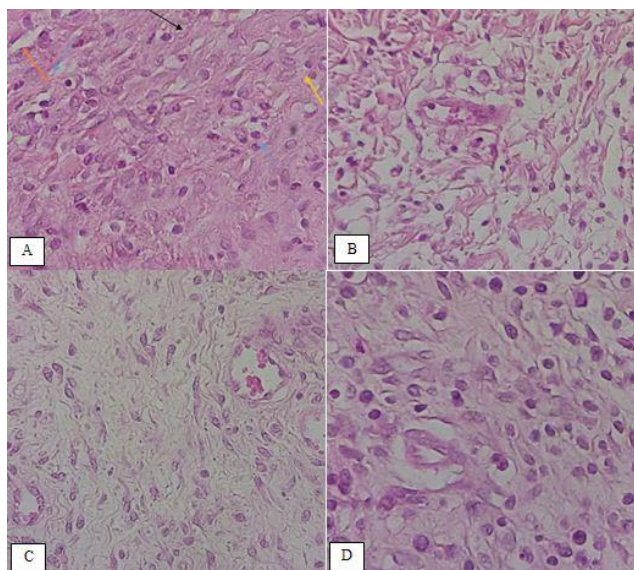
**Figure 6.** Box-and-whisker plots of number of fibroblasts in excisional model of the rat's skin in experimental groups. Results were expressed as mean  $\pm$  SEM.



**Figure 5.** Line graph indicating number of mononuclear cells in excisional model of the rat's skin in experimental groups. Results were expressed as mean  $\pm$  SEM. \*  $P < 0.05$  vs other experimental groups.



**Figure 7.** Histological characteristics of rat skin on the days 7 after wound creation in excisional wound model in experimental groups (A) Group III, (B) Group IV, (C) Group V and (D) Group VI. Black arrow: MNC, Blue arrow: PMN, Yellow arrow: Fibroblast, Orange arrow: blood vessel. (H&E staining,  $\times 400$ ).



**Figure 8.** Histological characteristics of rat skin on the days 14 after wound creation in excisional wound model in experimental groups (A) Group III, (B) Group IV, (C) Group V and (D) Group VI. Black arrow: MNC, Blue arrow: PMN, Yellow arrow: Fibroblast, Orange arrow: blood vessel. (H&E staining,  $\times 400$ ).

## 5. Discussion

Inflammation, proliferation and tissue remodeling are three phases of healing process which occur following tissue damages as closely as possible to its natural state. The healing process is activated when platelets come into contact with exposed collagen leading to platelet aggregation and the release of clotting factors resulting in the deposition of a fibrin clot at the site of injury. The fibrin clot serves as a provisional matrix and sets the stage for the subsequent events of healing. Inflammatory cells also arrive along with the platelets at the injury site providing key signals known as growth factors. The fibroblast is the connective tissue cell responsible for collagen deposition required to repair the tissue injury. The collagen is the main constituent of extra cellular tissue, which is responsible for support and strength.<sup>13</sup>

Nanoparticles (NPs) have become significant in the regenerative medicine field in the last two decades.<sup>14</sup> Many biological processes happen at through mechanisms that fundamentally act at the nanometer scale. Thus, materials such as NPs can be used as unique tools for drug delivery, imaging, sensing, and probing biological processes.<sup>15</sup> In the context of wound healing, the special properties of NPs like electric conductivity, antimicrobial activity, and high

surface to volume ratio, swelling, and contraction make NPs versatile resources.<sup>15</sup>

Several reports have demonstrated that there is a beneficial effect of chitosan as a biologically active dressing in wound management. It has been reported that the application of chitosan to the open wounds in dogs induced exudate, which has a high growth factor activity, and induced infiltration by inflammatory cells and granulation tissue formation accompanied by angiogenesis.<sup>16,17</sup> Chitosan-membrane-based wound products have been investigated both in laboratory animals and humans, however, are still at the early stages of development. Since 1980, chitosan and its derivatives have been used in skin and wound management products in Japan. Beschitin W, an artificial skin prepared from chitin threads, has been developed for human use and is on the market.<sup>18,19</sup>

We selected chitosan as a dressing material due to its biocompatibility, biodegradability, haemostatic activity, anti-inflammatory activity and property to accelerate wound healing.<sup>20</sup> The N-acetyl glucosamine (NAG) present in chitin and chitosan is a major component of dermal tissue which is essential for repair of scar tissue. Its positive surface charge enables it to effectively support cell growth and promotes surface induced thrombosis and blood coagulation. Free amino groups which are present on the chitosan membrane surface may form polyelectrolyte complexes with acidic groups of the cellular elements of blood.<sup>20</sup> It has several advantages over other type of disinfectants because it possesses a higher antimicrobial activity, a broader spectrum of activity, a higher killing rate and a lower toxicity toward mammalian cells. However, synthetic polymers are available at a lower price than biopolymer chitosan, substitution of chitosan by these synthetic polymers could reduce the price of chitosan-based films with safe effect on their functionality.<sup>20</sup>

The use of nanocomposites containing metals and metal oxides allows the therapeutic use of both unique properties of nanoparticles and polymer matrix properties. In this case, often the use of nanoparticles in nanocomposite structure allows not only to increase the stability of nanoparticles but also to reduce their potential cytotoxicity.<sup>21</sup>

Selenium is a nonmetal that has some metal properties. The use of selenium in nanoform is promising for regenerative medicine. It is well known that nanoselenium is a highly effective long-acting antioxidant. Its local introduction in the area of injury can lead to violation of redox signaling. Selenium nanoparticles have been investigated for various medical applications and as a potential material for orthopedic implants.<sup>22</sup> Currently, studies which indicate

precisely the ability of the selenium compounds to inhibit bacterial growth and formation of bacterial biofilms are also available.<sup>22</sup> Selenium has reported to show significant antiproliferative activity against HeLa and HepG2 cell lines.<sup>23</sup> The wound healing activity of selenium nanoparticles have revealed that 5% selenium ointment heals the excision wound of Wistar rats up to 85% within 18 days compared to the standard ointment.<sup>23</sup>

Biomaterials derived from natural products can provide materials with greater complexity and composition. In order to mimic the extracellular matrix (ECM) conditions of the wound and to provide a scaffold for the fibroblasts for collagen deposition, ECM-based therapies have gained popularity.<sup>24</sup> A phase I clinical trial using fibroin to enhance wound healing is currently underway. Finally, there have been numerous marine polysaccharide hydrogels like marine collagen from *Stomolophus nomurai meleagris*, *Oncorhynchus keta*, *Lates calcarifer*, *Stichopus japonicas*, and *Salmo salar*, alginate from *Macrocystis pyrifera*, chitosan from crabs and shrimps, which are bioactive and increase wound healing rates in mice.<sup>25</sup>

The histopathological findings of the present study demonstrated fewer polymorphonuclear cells were present in first week in animals treated with Chitosan/Nanoselenium. Improved mononuclear cell infiltration and more rapid reepithelization were also present in Chitosan/Nanoselenium treated animals. The reduced number of inflammatory cells on days 14 and 21 were observed in animals treated with Chitosan/Nanoselenium. On day 21 after injury, intense collagen deposition was found in different groups, however, group treated with Chitosan/Nanoselenium showed more organized collagen formation and less cellularity

In our study, chitosan/nano sodium selenite biodegradable film revealed that there was a significant difference by means of histopathological examinations in group VI compared to other experimental groups and showed significant effect on inflammatory infiltration and number of fibroblasts in time-dependent activity. This showed promising effect of chitosan/nano sodium selenite biodegradable film on wound healing.

Chitosan/nano sodium selenite biodegradable film resulted in significant improvement in histopathological indices in full thickness wound healing. Thus, from this study it could be concluded that chitosan/nano sodium selenite biodegradable film have a reproducible wound healing potential and hereby justifies its use in practice.

## Acknowledgment

This work was a part of a dissertation of first author (H.R) submitted as a Partial Fulfillment of the Degree of Doctor of Veterinary Science (DVSc) that was supported from Vice- Chancellor for Research and Technology, Urmia University.

## Conflicts of interest

None

## References

1. Sorg H, Tilkorn DJ, Hager S, Hauser J, Mirastschijski U. Skin Wound Healing: An Update on the Current Knowledge and Concepts. *European Surgical Research*, 2017;58(1-2):81-94.
2. Seno H, Miyoshi H, Brown S L, Geske MJ, Colonna M, Stappenbeck TS. Efficient colonic mucosal wound repair requires Trem2 signaling. *Proceedings of the National Academy of Sciences* 2009;106:256–261.
3. Tran PA, Zhang L, Webster TJ. Carbon nanofibers and carbon nanotubes in regenerative medicine. *Advanced Drug Delivery Reviews*, 2009;61(12):1097-114.
4. Sinha VR, Singla AK, Wadhawan S, Kaushik R, Kumria R, Bansal K, Dhawan S. Chitosan microspheres as a potential carrier for drugs. *International Journal of Pharmaceutics* ,2004;274:1-33.
5. No HK, Park NY, Lee SH, Meyers SP. Antibacterial activity of chitosans and chitosan oligomers with different molecular weights. *International Journal of Food Microbiology*, 2002;74:65-72.
6. Kishen A, Shi Z, Shrestha A, Neoh KG. An investigation on the antibacterial and antibiofilm efficacy of cationic nanoparticulates for root canal disinfection. *Journal of Endodontics*, 2008;34:1515-1520.
7. Mofazzal Jahromi MA, Sahandi Zangabad P, Moosavi Basri SM, Sahandi Zangabad K, Ghamarypour A, Aref AR, Karimi M, Hamblin MR. Nanomedicine and advanced technologies for burns: Preventing infection and facilitating wound healing. *Advanced Drug Delivery Reviews*, 2018;123:33-64

8. Oyarzun-Ampuero F, Vidal A, Concha M, Morales J, Orellana S, Moreno-Villoslada I. Nanoparticles for the Treatment of Wounds. *Current Pharmaceutical Design*, 2015;21(29):4329-4341.
9. Wang HL, Zhang JS, Yu HQ. Elemental Selenium at Nano Size Possesses Lower Toxicity without Compromising the Fundamental Effect on Selenoenzymes: Comparison with Selenomethionine in Mice. *Free Radical Biology and Medicine*, 2007;42:1524-1533.
10. Gao XY, Zhang JS, Zhang LD. Hollow sphere selenium nanoparticles: their in vitro antihydroxyl radical effect. *Advanced Materials*, 2002;14(4): 290-293.
11. Bai Y, Wang Y, Zhou Y, Li W, Zheng W. Modification and modulation of saccharides on elemental selenium nanoparticles in liquid phase. *Materials Letters*, 2008;62:2311-2314.
12. Ojagh SM, Rezaei M, Razavi SH, Hosseini SMH. Development and evaluation of a novel biodegradable film made from chitosan and cinnamon essential oil with low affinity toward water. *Food Chemistry*, 2010;122(1):161-166.
13. Martin J, Zenilman M, Lazarus GS. Molecular microbiology: new dimensions for cutaneous biology and wound healing. *Journal of Investigative Dermatology*, 2010;130:38-48.
14. McLaughlin S, Podrebarac J, Ruel M, Suuronen E J, McNeill B, Alarcon EI. Nano-engineered biomaterials for tissue regeneration: what has been achieved so far? *Frontiers in Materials*, 2016;3:27.
15. Wang EC, Wang AZ. Nanoparticles and their applications in cell and molecular biology. *Integrative Biology*, 2016;6:9-26.
16. Okamoto K, Sibazaki S, Minami A, Matsuhashi S, Tanioka Y, Shigemasa Y. Evaluation of chitin and chitosan on open wound healing in dogs. *Journal of Veterinary Medical Science*, 1995;57:851-854.
17. Mizuno K, Yamamura K, Yano K, Osada T, Saeki S, Takimoto N, Sakurai T, Nimura Y. Effect of chitosan film containing basic fibroblast growth factor on wound healing in genetically diabetic mice. *Journal of Biomedical Materials Research Part A*, 2003;64:177-181.
18. Koji k. Clinical application of chitin artificial skin (Beschitin W). in: C.J. Brine, P.A. Sanford, J.P. Zikakis, (Eds), *Advances in chitin and chitosan* Elsevier Applied Science, Landon and New York, 1992 pp, 9-15.
19. Azad AK, Sermsintham N, Chandkrachang S, Stevens WF. Chitosan membrane as a wound-healing dressing: characterization and clinical application. *Journal of Biomedical Materials Research Part B Applied Biomaterials*, 2004;69:216-222.
20. Archana D, Dutta J, Dutta PK. Evaluation of chitosan nano dressing for wound healing: characterization, in vitro and in vivo studies. *International Journal of Biological Macromolecules*, 2013;57:193-203.
21. Li X, Wang H, Rong H, Li W, Luo Y, Tian K, Quan D, Wang Y, Jiang L. Effect of composite SiO<sub>2</sub>@ AuNPs on wound healing: in vitro and vivo studies. *Journal of Colloid and Interface Science*, 2015;445:312-319.
22. Wang Q, T. Webster J. Nanostructured selenium for preventing biofilm formation on polycarbonate medical devices. *Journal of Biomedical Materials Research Part A*, 2012;100(12):3205-3210.
23. Ramya S, Shanmugasundaram T, Balagurunathan R. Biomedical potential of actinobacterially synthesized selenium nanoparticles with special reference to anti-biofilm, anti-oxidant, wound healing, cytotoxic and anti-viral activities. *Journal of Trace Elements in Medicine and Biology*, 2015;32:30-39.
24. Das S, Baker AB. Biomaterials and Nanotherapeutics for Enhancing Skin Wound Healing. *Frontiers in Bioengineering and Biotechnology*, 2016;31:4:82.
25. Chandika P, KO SC, Jung WK. Marine-derived biological macro-molecule-based biomaterials for wound healing and skin tissue regeneration. *International Journal of Biological Macromolecules*, 2015;77:24-35.



نشریه جراحی دامپزشکی ایران

سال ۲۰۱۸، جلد ۱۳ (شماره ۱)، شماره پیاپی ۲۸

چکیده

## ارزیابی کاربرد لایه زیست تخریب پذیر کیتوزان-نانوسلنیوم بر روی التیام زخم‌های برداشتی تمام ضخامت پوست در موش صحرایی

هاوادم رستمی<sup>۱</sup>، رحیم محمدی<sup>۱</sup>، سیامک عصری رضایی<sup>۲</sup>، علی اصغر طهرانی<sup>۳</sup>

<sup>۱</sup> گروه جراحی و تصویربرداری تشخیصی، دانشکده دامپزشکی، دانشگاه ارومیه، ارومیه، ایران  
<sup>۲</sup> گروه بیماری‌های درونی و کلینیکال پاتولوژی، دانشکده دامپزشکی، دانشگاه ارومیه، ارومیه، ایران  
<sup>۳</sup> گروه پاتوبیولوژی، دانشکده دامپزشکی، دانشگاه ارومیه، ارومیه، ایران

**هدف:** هدف از انجام این مطالعه ارزیابی هیستوپاتولوژی کاربرد لایه زیست تخریب پذیر کیتوزان-نانوسلنیوم بر روی التیام زخم‌های برداشتی تمام ضخامت پوست در موش صحرایی بود.

**طرح:** مطالعه تجربی.

**حیوانات:** هفتاد و دو موش صحرایی نر سلام نژاد ویستار.

**روش کار:** در این مطالعه حیوانات به‌طور تصادفی به شش گروه دوازده‌تایی تقسیم شدند. گروه اول: ایجاد زخم بدون به‌کارگیری درمان. گروه دوم: ایجاد زخم همراه با کاربرد لایه کیتوزان بر روی زخم به‌تنهایی به‌عنوان درمان. گروه سوم: ایجاد زخم همراه با کاربرد سلنیت سدیم بر روی زخم به‌عنوان درمان. گروه چهارم: ایجاد زخم همراه با کاربرد نانو ذرات سلنیوم به‌عنوان درمان. گروه پنجم: ایجاد زخم همراه با کاربرد لایه زیست تخریب پذیر کیتوزان-سلنیت سدیم بر روی زخم به‌عنوان درمان. گروه ششم: ایجاد زخم همراه با کاربرد لایه زیست تخریب پذیر کیتوزان-نانوسلنیوم بر روی زخم به‌عنوان درمان.

**نتایج:** تفاوت معنی‌داری بین گروه ششم در مقایسه با سایر گروه‌ها از نظر رگ زایی و نفوذ سلولی وجود داشت. در طول دوره این مطالعه امتیازات رگ زایی مربوط به گروه ششم در مقایسه با سایر گروه‌ها دارای تفاوت معنی‌دار ( $P < 0.05$ ) بیشتری بوده است.

**نتیجه‌گیری و کاربرد بالینی:** کاربرد لایه زیست تخریب پذیر کیتوزان-نانوسلنیوم به‌صورت معنی‌داری باعث افزایش بهبودی در شاخص‌های پاتولوژیک ترمیم زخم‌های برداشتی تمام ضخامت می‌گردد. بر اساس این مطالعه لایه زیست تخریب پذیر کیتوزان-نانوسلنیوم دارای توانای بالقوه بهبود التیام زخم است که با استناد بر این مطالعه می‌توان از آن به‌صورت عملی برای التیام زخم استفاده کرد.

**کلمات کلیدی:** التیام زخم، زخم تمام ضخامت، کیتوزان-نانوسلنیوم، نانو ذرات سلنیوم، رت.