



Ultrasonographic Examination of Mammary Glands in Caspian Mares during the Lactation and Dry Period

Jalil Abshenas¹, Seyed Mohsen Sajjadian², Mohammad Taghavi³

Abstract

Objective- The aim of this study was to determine the normal ultrasonographic and morphologic appearance of mammary gland and teat in Caspian mares during lactation and dry period.

Design- Experimental study.

Animals- Seven mature Caspian mares

Procedures- Using a 6.5-8.5 MHz linear transducer the ultrasonographic appearance of lactating and dry mammary glands was determined in 7 mature Caspian mares aged from 5 to 12 years. In macroscopic study, parameters of length and width of teat, length and thickness of udder were evaluated by a caliper. During the ultrasonography, the ultrasound probe was placed in horizontal and sagittal position related to the examined subject. Two methods of examination were used – direct (transcutaneous ultrasonography) and immersion of the examined organ in water (“water bath” method).

Results- The teat was best scanned in sagittal position, whereas the mammary parenchyma – in horizontal probe position. The application of the “water bath” method was more effective when examining the mammary papilla, and the transcutaneous method – when examining the structures in the other areas of the mammary gland. Mean teat measurements by ultrasonography including teat canal length, teat cistern diameter, teat wall thickness and middle cistern wall thickness were 8.87, 10.37, 1.75 and 6.44 mm respectively. No significant differences were found between the mentioned parameters of fore and hind glands in one udder.

Conclusion and Clinical Relevance- There were differences in the visualizations of the separate structures of the udder, depending on the presence or absence of the milk. According to the results of present study it is recommended to perform ultrasonography of mare’s mammary gland during lactation period.

Key words- Caspian mare, mammary gland, ultrasonography

Introduction

The Caspian horse is a special breed and is believed to be the direct descendant of the earliest equine.¹ This breed is probably the most direct ancestor of the oriental breeds and subsequently of all light horse breeds.² The Caspian miniature horse was re-founded in the northern part of Iran around the Caspian sea in 1969.³ The conformation of the Caspian horse is similar to that of

the horse (*Equus caballus*), and apart from the height, there are only a few minor anatomical differences between this animal and *Equus caballus*.³ Subsequent studies confirmed the visual picture osteologically and proved that the Caspian is a miniature horse, not a pony.^{4,5}

The mammary glands of the mare, in common with all mammals, are modified apocrine sweat glands, both developing in uterus from a common precursor. The udders of the Caspian mare are two in number. They are situated along the ventral midline in all mammals in a varying number of pairs. The mare normally has four glands, two larger cranial ones and two smaller caudal ones, though six glands have been reported in the occasional mare. Each of the two mammary glands is completely independent, with no passage of milk from one quarter to another.⁶ They are separated by and contained within a fibroelastic capsule and supported by

¹Department of Clinical Sciences, Faculty of Veterinary Medicine, Shahid Bahonar University of Kerman, Kerman, Iran.

²Department of Basic Science, Faculty of Veterinary Medicine, Shahid Bahonar University of Kerman, Kerman, Iran.

³Graduated Student, Faculty of Veterinary Medicine, Shahid Bahonar University of Kerman, Kerman, Iran.
Address all correspondence to Dr. Jalil Abshenas (DVM, DVSc),
E-mail: jabshenas@mail.uk.ac.ir

the medial suspensory ligament, running along the mare's midline. Each udder half, either side of the midline, is made up of two quarters and the openings from these two quarters exteriorize via a single teat. The mammary tissue itself is made up of millions of alveoli and connecting ducts.⁶

Adequate secretion of milk (including colostrum) must take place at the appropriate time for normal growth and development of the foal. Lactational abnormalities are rarely encountered in mares. Yet when a particular mare is involved and her foal is at risk, these problems are highly significant to the mare's owner.⁷

Ultrasonography is a simple, reliable, non-invasive imaging technique without side effects. Nowadays, ultrasonography can be seen as an extension of the clinical evaluation of different structures or masses, providing information on their anatomical or morphological features.⁸ Sonographic breast imaging, along with mammography, is currently used as part of the standard procedure in the diagnosis of human breast masses.⁹⁻¹¹ This rapid, simple and non-invasive technique provides useful information on the characteristics of a tissue, using a grey scale and two-dimensional image. The use of ultrasonography in the study of the mammary gland has been also developed for farm animals.^{9,12,13} Ultrasonography has important applications in the bovine mammary glands. Ultrasound studies have characterized not only the normal ultrasonographic appearance of the mammary glands and teats but also some pathologic lesions of the mammary glands.¹⁴ The potential of ultrasonography for examination of various physiological and pathological conditions of the mammary gland has been thoroughly studied for cows,^{12,15,16} buffaloes,¹⁷ sheep,¹⁸⁻²⁰ camels,²¹ mares²² and carnivores.^{9,23} However, to the authors' knowledge, few studies have been published on the sonomorphological characteristics of the Caspian mare mammary gland. Therefore, the aim of the present study was to establish a ultrasonographic appearance of Caspian mare mammary gland and teat during lactation and dry period.

Materials and methods

Animals

The experiment was carried out in seven healthy registered Caspian mares, according to mammary gland examination and complete blood cell evaluation (CBC), with normal reproductive histories. Age ranged from 5 to 12 years, height from 100 to 120 cm and weighing between 160 and 230 kg at the beginning of the study. All examination was done in the dioestrous period of the crude according to ultrasonographic scanning of reproductive tubules and ovaries. During this study the animals were corralled outdoors at the Gharran Caspian breeding center in Bahramjerd, an area located 50 km from south Kerman, Iran (latitude 29°50'N; longitude

56°50'E, altitude 2860 m above sea level, with an annual rainfall of 0.4 mm, an average temperature of 27.3 °C and a relative humidity of 20%). Diets were formulated to meet or exceed NRC requirements. The ultrasonography examination was performed in milking and dry Caspian mares.

Ultrasonographic scanning and measurement

Ultrasonographic imaging of the udder and teats was carried out on Caspian mares in the standing position, 2 hours after sucking by foals, with an ultrasound scanner (SONOACE 600V; Kretz-Technik) equipped with a 6.5-8.5 MHz (7.5 MHz median frequency/60 mm foot print) linear array multi-frequency, waterproof transducer. For documentation of the data obtained, a black and white thermo-printer (SONY Inc., Tokyo, Japan) was used and pictures printed on UPP-110S Type I Paper (SONY Inc., Tokyo, Japan).

Two examination methods were used including "direct method" or transcutaneous ultrasonography which the probe was placed on the skin after using of a contact gel and immersing the examined organ in warm water or "water bath" method.²⁴ In order to implement the second method, plastic cups of various sizes were filled with warm water, with the transducer being in contact with the vessel or inside it. To prevent deformation of the teat and to ensure complete presentation of the tip of the teat, the teat was dipped in a water-filled. During the scan itself, the transducer was positioned along the length and width of the mammary gland, designated, respectively, as sagittal and horizontal positions. Initially, the echo-structures of the mammary papilla were outlined (e.g. papillary orifice, teat canal, the Furstenberg's rosette, the papillary part of the cistern and the separate layers of the papillary wall). After that, the mammary lobes were examined. The parenchyma, the gland cistern and lactiferous ducts were observed. Teats were examined by sagittal planes and the probe was positioned equally at all times during the experimental period. When characteristic structures of the teat and teat canal as described by Franz et al¹², appeared, and the picture showed a satisfactory quality, it was frozen at its maximal size of the height and width diameters were measured with integral electronic calipers, and it was printed out.¹⁹ The teat canal length (Furstenberg's rosette was included; TCL), teat end width (TEW), teat wall thickness (TWT) and teat cistern diameter (TCD) were measured in ultrasonographic scans while the teats were immersed in warm water (Fig. 1), as described by Enda and Dinç,²⁴ In gross study, parameters of length and width of teat, length and thickness of udder were evaluated by a caliper.

Statistical Analysis

The data were expressed as means ± standard errors of mean (SEM). SPSS Version 17 was used for obtaining

mean and standard deviation of measurements and the data comparison for TCL, TEW, TWT, TCW and MCWT were analyzed between anterior and posterior glands by Paired Sample T-test at $P < 0.05$.

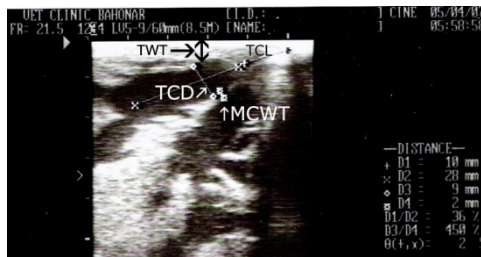


Figure 1. Ultrasonographic teat measurements: TCL, Teat Canal Length; TCD, Teat Cistern Diameter; TWT, Teat Wall Thickness and MCWT, Middle Cistern Wall Thickness.

Results

The teat is short and cone-shaped and somewhat flattened from side to side. Table 1 shows the results of mammary gland parameters in lactating and dry Caspian mares. Appearance of udders was significantly different in each group (Table 1), and ultrasound images of the mammary glands varied at the different stages of lactation (Fig. 3A and B). There was no significant difference in findings between left and right udder.

In Caspian mares, B-mode ultrasonography with 6.5-8.5 MHz linear array transducer in the sagittal plane, showed that each mammary gland was consisted of two distinct glands, each leading to a separate gland cistern; and each gland cistern connected to the teat cistern, which were completely separated from each other. In the lactating animals, the papillary duct and orifices, teat cistern, annular fold, gland cistern, lactiferous ducts and mammary parenchyma were imaged easily (Fig. 2 and 3A), while in dry animals the duct and orifices were not detectable (Fig. 3B).

Sagittal ultrasonographic examination of the teat in the lactating mares indicated that the wall of the teat could be divided into 3 layers, a hyperechoic outer layer (skin/epidermis), a homogenous and thick median layer with moderately echogenicity (muscle layer) and a thin hyperechoic inner layer (mucous membrane) respectively (Fig. 2A and B). The papillary orifices of the teat were visualized as a small anechoic formation at

its tip. Directly above it, the papillary duct appeared unclearly as a linear stria, bordered by the sonographic image of the adjacent teat wall and monitored at the front and behind sides of line dividing teat cistern. Furstenberg's rosette was determined as a homogenous hypoechoic structure between papillary duct and teat cistern. Multiple small anechoic areas were observed within the middle layer of the teat wall on the images (Fig. 2A and B).

The small anechoic areas within the middle layer of the teat and in the area of the annular fold observed in the present study were consistent with blood filled vessels known to be the plexus venousus pempiniferous (Fig. 2B).

In lactating examined mares, teat cistern which filled with milk was monitored as an anechoic image. The base of the teat and the annular folds appeared as a hyperechoic linear structure extending into the teat cistern. The boundary between the gland cistern and teat cistern included large round anechoic structures (blood vessels from the Furstenberg's venous ring (Fig. 2B).

The cisternes of the gland appeared as an anechoic area which continued with the teat cistern. The lining of the wall of the gland cistern appeared as mixed hyper to hypoechoic areas within the hypoechoic material of the glands (Fig. 3A).

Examination of the mammary gland parenchyma in lactating mares was performed primarily by horizontal scans. It was homogenous and appeared as a hyperechoic structure (Fig. 3A), with anechoic zones, parts of blood vessels or lactiferous ducts. The milk secretion in the cistern gave an anechoic image with single echoic particles. The large lactiferous ducts within the cisterns were clearly visible and anechoic as well (Fig. 3A). The gland cistern appeared as a homogenous anechoic area that continued with the teat cistern. The lactiferous ducts were elongating anechoic branches in hyper-echoic mammary parenchyma.

The results of the ultrasonographic measurements of lactating Caspian mares udder parameters examined are shown in Table 2. Measured parameters were not significantly different ($P > 0.05$) between fore and hind gland in mare udder. In dry mare teats, a measurement of the teat parameters was not possible.

Table 1. Length of the udder and teat (mean \pm SEM) in lactating and dry Caspian mares (n=7)

Udder status and direction	Teat length(mm)	Teat width(mm)	Udder length(cm)	Udder width(cm)	
Milking(n=4)	Right	11.25 \pm 0.49 ^a	9.25 \pm 0.16 ^a	9.19 \pm 0.21 ^a	8.25 \pm 0.28 ^a
	Left	11.00 \pm 0.42 ^a	8.25 \pm 1.00 ^a	8.94 \pm 0.22 ^a	8.12 \pm 0.24 ^a
Dry(n=3)	Right	8.00 \pm 0.22 ^b	6.83 \pm 0.31 ^b	6.42 \pm 0.35 ^b	7.43 \pm 0.32 ^b
	left	8.17 \pm 0.60 ^b	6.50 \pm 0.22 ^b	6.25 \pm 0.33 ^b	5.92 \pm 0.24 ^b

The values with different alphabetical superscripts differ significantly ($P < 0.05$) within each column.

Table 2. Ultrasonographic measurement (mm) of teat parameters (mean±SEM) in 4 lactating Caspian mares

Parameter	TCL	TCD	TWT	MCWT
Fore teat	8.87±0.29	10.37±0.32	1.75±0.16	6.44±0.32
Hind teat	8.50±0.43	9.50±0.27		

TCL, Teat Canal Length; TCD, Teat Cistern Diameter; TWT, Teat Wall Thickness and MCWT, Middle Cistern Wall Thickness. No statistical differences were observed between fore and hind gland parameters. Measurements were obtained during longitudinal scans, peripheral to the teat.



Figure 2. Sagittal scan of the milking Caspian mare teat (A) and glands (B) in a water-bath. SC (streak canal), FR (Furstenberg's rosette), PP (plexus pempiniferous), TC (teat cistern), GC (gland cistern), P (parenchyma), FVR (Furstenberg's venous ring). Three layers of the teat wall can be identified: OL (outer layer), ML (middle layer) and IL (inner layer). The sonogram was obtained with 7.5 MHz linear array transducer.



Figure 3. Sonogram of a physiological gland parenchyma with medium homogeneous echogenicity and isolated anechoic lactiferous ducts and vessels in a milking (A) and dry (B) Caspian mare (horizontal scan): P (glandular parenchyma), LD (lactiferous ducts), BV (blood vessels). The sonogram was obtained with 8.5 MHz linear array transducer. The udder skin is on the top of the ultrasonogram, the dorsal portion of the udder is to the left, ventral to the right.

Discussion

Ultrasound examination as reported by Neijenhuis et al.,²⁵ in cow's and Franz et al.¹⁹ in sheep's is a very useful tool to measure teat and teat canal structures. The method is also relatively easy to use, repeatable, safe and noninvasive. This makes the ultrasound scanning a useful technique to study the teat and udder of Caspian mare.¹⁵ The B-mode ultrasonography technique as described in this study seems to be reliable for determining the anatomic features of the udder and measuring the teat parameters of the Caspian mares. The normal appearance of the udder and teat are

amenable to sonographic imaging because of their superficial location and the technique has the potential to diagnose different conditions of the organ. Ultrasonography is an efficient way of monitoring changes in the intramammary structures.^{26,27} Ultrasonographic scanning of udder and teat can be performed by direct contacting the transducer with teat or in a water-bath. Direct contact can be easily applied; however, the shape of the teat may change because the teat wall near the probe and Furstenberg's rosette area cannot be seen completely.²¹

In our previous report Abshenas et al.,²¹ and also in agreement with Gungor et al.,²² using a 7.5 MHz linear

ultrasound transducer, showed two visible hyperechoic lines in the images of the papillary duct of camels and mares which were also observed during our examinations of Caspian mares. Seeh *et al*²⁸ reported that an image with a satisfactory quality could be achieved via direct contact of the mammary papilla with a 3.5 or 5 MHz probe, whereas Abshenas *et al.*,²¹ and Will *et al.*,²⁹ achieved better visualization using a different method by the “water bath”. The plastic “water bath” containers should be smooth in order to ensure a good contact and to conduct ultrasonic waves.^{16,21,22} Cartee *et al*³⁰ observed that the use of the water-bath increased the acoustic impedance difference between the teat wall and the surrounding medium.

The presence of milk in the teat cistern acted similarly as a “window” of acoustic impedance difference for imaging the deeper structures and far wall of the teat¹⁹. Ultrasonographic findings of the udder of Caspian mares were similar to ultrasonographical findings of Gungor *et al.*,²² but, in contrast to the previous reports in mares, differences between fore and hind teat parameters were not significant in Caspian mares. However, hind part of the gland in Caspian mare had enough growth and we did not observe any significant difference with fore-gland in teat parts. In the present study, no significant differences were found between parameters of fore and hind glands in an individual teat, which was in contrast with the findings of Gungor *et al.*,²² and Freeman,³¹ who found differences in mammary gland structures.

The boundary between the gland cistern and teat cistern is marked by the annular (cricoid) folds. The gland cistern is anechoic, as is the teat cisterns lumen, even when filled with milk. If milk is not present in the teat cistern, the lumen cannot be discerned. The rosette of Furstenberg appeared as hyperechoic circular area in the centre of the teat. The small anechoic areas within the middle layer of the teat and in the area of the annular fold observed in the present study were consistent with blood filled vessels known to be the plexus venosus papillaris and the circulus venosus papillae, respectively.^{16,17,32}

Similar to the studies of Cartee *et al.*,³⁰ Gungor *et al.*,²² and Franz *et al.*,¹⁶ our examination on structures of the mammary gland’s parenchyma showed better results

with direct contact between the transducer and the skin and horizontal scan. The visualization of echo-structures in this area is hard to perform with the water bath technique because it is uncomfortable for the operator.

The data obtained in this study proved that the lack of milk secretion in dry mares impeded the visualization of the various structures. It is acknowledged that fluids play the role of an acoustic window. The lactiferous ducts were anechoic areas within the hypothetic matrix of the fold. Gungor *et al*²² described the lactiferous duct as an elongating anechoic branch in hyper-echoic mammary parenchyma. Some of the anechoic areas within the glandular parenchyma may have been blood vessels but others certainly were lactiferous ducts, because they could be seen entering the gland cistern.

The present study showed that the features of normal mammary glands at different stages of lactation and dry period could be visualized by ultrasound. To the authors’ knowledge, in mares and Caspian mares the anatomical measurement of teat and udder length and width, and ultrasonographical measurements have not been reported yet.

In conclusion, morphological structure of Caspian mare teat and udder can be differentiated with B-mode ultrasound. Since there are several reports of udder infection, udder obstruction and mastitis problems in mares,³³⁻³⁵ further investigations are necessary to evaluate ultrasonographic images as an additional diagnostic tool for abnormalities of the udder and teat in mares. Application of the “water bath” method is more effective when the mammary papilla is examined, and the transcutaneous method – when examining the structures in the other areas of the mammary gland.

Acknowledgements

The authors would like to thank Dr. Mohammad-Mehdi Shafipour, Dr. Ali Shafipour and his colleagues for providing animals and facilities.

References

1. Shirazi A, Gharagozloo F, Ghasemzadeh-Nava H. Ultrasonic characteristics of preovulatory follicle and ovulation in Caspian mares. *Anim Reprod Sci* 2004;80:261-266.
2. Shirazi A, Gharagozloo F, Niasari-Naslaji A, *et al.* Ovarian follicular dynamics in Caspian mares. *J Equine Vet Sci* 2002;22:208-211.
3. Firouz L. Osteological and historical implication of the Caspian pony to early domestication in Iran. Proc 3rd Int Congr Agricultural Museum, Budapest 1971:1-5.
4. Hendricks BL, Dent AA. International encyclopedia of horse breeds: Univ of Oklahoma Pr, 2007.
5. Sakha M, Ozmaie S, Sohrabi-Haghdoust I, *et al.* Perineal sarcoid in a Caspian miniature horse. *Comp Clin Path* 2011:1-3.
6. Morel MCGD. Equine reproductive physiology, breeding and stud management: Cabi Publishing, 2008.
7. Young quist RS, Threlfall WR, ScienceDirect. Current therapy in large animal theriogenology: Saunders Elsevier, 2007.
8. Gonzalez Bulnes A, Pallares P, Vazquez M. Ultrasonographic Imaging in Small Ruminant Reproduction. *Reprod Domest Anim*;45:9-20.

9. Payan-Carreira R, Martins-Bessa AC. Ultrasonographic assessment of the feline mammary gland. *J Feline Med Surg* 2008;10:466-471.
10. Sehgal CM, Weinstein SP, Arger PH, et al. A review of breast ultrasound. *J Mammary Gland Biol Neoplasia* 2006;11:113-123.
11. Schroeder RJ, Bostanjoglo M, Rademaker J, et al. Role of power Doppler techniques and ultrasound contrast enhancement in the differential diagnosis of focal breast lesions. *Eur Radiol* 2003;13:68-79.
12. Franz S, Hofmann-Parisot MM, Baumgartner W. Evaluation of three-dimensional ultrasonography of the bovine mammary gland. *Am J Vet Res* 2004;65:1159-1163.
13. Nudda A, Pulina G, Vallebella R, et al. Ultrasound technique for measuring mammary cistern size of dairy ewes. *J Dairy Res* 2000;67:101-106.
14. Y. Ribadu A, Nakao T. Bovine reproductive ultrasonography: a review. *J Reprod Dev* 1999;45:13-28.
15. Klein D, Flöck M, Lorenz Khol J, et al. Ultrasonographic measurement of the bovine teat: breed differences, and the significance of the measurements for udder health. *J Dairy Res* 2005;72:296-302.
16. Franz S, Floek M, Hofmann-Parisot M. Ultrasonography of the Bovine Udder and Teat. *Vet Clin North Am Food Anim Pract* 2009;25:669-685.
17. Rambabu K, Sreenu M, Kumar S, et al. Ultrasonography of the udder and teat in buffaloes: a comparison of four methods. *Buffalo Bulletin* 2008; 27: 269-273.
18. Ruberte J, Carretero A, Fernández M, et al. Ultrasound mammography in the lactating ewe and its correspondence to anatomical section. *Small Rumin Res* 1994;13:199-204.
19. Franz S, Hofmann-Parisot M, Güttler S, et al. Clinical and ultrasonographic findings in the mammary gland of sheep. *N Z Vet J* 2003;51:238-243.
20. Rovai M, Caja G, Such X. Evaluation of udder cisterns and effects on milk yield of dairy ewes. *J Dairy Sci* 2008;91:4622-4629.
21. Abshenas J, Vosough D, Masoudifard M, et al. B-mode ultrasonography of the udder and teat in camel (*Camelus dromedarius*). *J Vet Res* 2007;62 :27-31.
22. Gungor O, Pancarci ŞM and Karabacak A. Examination of equine udder and teat by B-mode ultrasonography. *Kafkas Univ Vet Fak Derg* 2005;11:107-111.
23. Träsch K, Wehrend A, Bostedt H. Ultrasonographic description of canine mastitis. *Vet Radiol Ultrasound* 2007;48:580-584.
24. Enda S, Dinç D. Ultrasonography of the bovine udder. *Turk J Vet Anim Sci* 1999;23:545-552.
25. Neijenhuis F, Klungel G, Hogeveen H. Recovery of cow teats after milking as determined by ultrasonographic scanning. *J Dairy Sci* 2001;84:2599-2606.
26. Seker I, Risvanli A, Yuksel M, et al. Relationship between California Mastitis Test score and ultrasonographic teat measurements in dairy cows. *Aust Vet J* 2009;87:480-483.
27. Khol J, Franz S, Klein D, et al. Influence of milking technique and lactation on the bovine teat by means of ultrasonographic examination. *Berl Munch Tierarztl Wochenschr* 2006;119:68.
28. Seeh C, Hospes R, Bostedt H. Use of visual methods (sonography/endoscopy) for the diagnosis of a webbed teat in cattle. A case report. *Tierarztl Pract* 1996;24:438.
29. Will S, Würgau S, Fraunholz J, et al. Ultrasonographic findings of the bovine teat. *Dtsch Tierarztl Wochenschr* 1990;97:403-406.
30. Cartee R, Ibrahim A, McLeary D. B-mode ultrasonography of the bovine udder and teat. *J Am Vet Med Assoc* 1986;188:1284.
31. Freeman KP. Cytological evaluation of the equine mammary gland. *Equine Vet Educ* 1993;5:212-213.
32. Fasulkov I, Georgiev P, Antonov A, et al. B-mode ultrasonography of mammary glands in goats during the lactation period. *Blg J Vet Med* 2010;13:245-251.
33. Spadari A, Valentini S, Sarli G, et al. Mammary adenoma in a mare: Clinical, histopathological and immunohistochemical findings. *Equine Vet Educ* 2008;20:4-7.
34. Reesink H, Parente E, Sertich P, et al. Malignant fibrous histiocytoma of the mammary gland in a mare. *Equine Vet Educ* 2009;21:467-472.
35. Mohammadi GHA, Mori BN, Barati F, et al. Mastitis in mare; a case report. *Sci Res Iran Vet J* 2008;20 : 123-126.

چکیده

بررسی اولتراسونوگرافی غدد پستانی مادپانه‌های اسبچه خزر در طول دوره های شیرواری و خشک

جلیل آب شناس^{۱*}، سید محسن سجادیان^۲، محمد تقوی^۳

^۱ گروه علوم درمانگاهی، دانشکده دامپزشکی دانشگاه شهید باهنر کرمان، کرمان، ایران.
^۲ گروه آموزشی علوم پایه، دانشکده دامپزشکی دانشگاه شهید باهنر کرمان، کرمان، ایران.
^۳ دانش‌آموخته دانشکده دامپزشکی دانشگاه شهید باهنر کرمان، کرمان، ایران

هدف- مطالعه سونوگرافیک و مورفومتریک غده پستانی و سرپستانک اسبچه خزر در دوره شیرواری و خشکی.
طرح مطالعه- مطالعه تجربی.

حیوانات- هفت راس مادپان اسبچه خزر بالغ

روش کار- غدد پستانی و سرپستانک های هفت راس مادپان اسبچه خزر بالغ با میانگین سنی ۵ تا ۱۲ سال با استفاده از دستگاه سونوگرافی متصل به پراب خطی ۸/۵ تا ۶/۵ مگاهرتز مورد مطالعه قرار گرفت. برای مطالعه ماکروسکوپی با استفاده از کولیس طول و پهنای سرپستانک و قطر و طول غدد پستانی اندازه گیری شد. در طول مطالعه سونوگرافی، پراب در امتداد محور افقی و عمودی غدد پستانی قرار داده می شد. تصویر برداری با دو روش اتصال مستقیم پراب و استفاده از ظرف آب انجام شد.
نتایج- بهترین تصویر برداری از سرپستانک در مقطع عمودی و غدد پستانی در مقطع عرضی بدست آمد. استفاده از ظرف آب برای تصویر برداری از سرپستانک مفید بود، در حالیکه برای تصویر برداری از غدد پستانی اتصال مستقیم پراب نتایج بهتری داشت. نتایج حاصل از اندازه گیری سرپستانک با استفاده از سونوگرافی برای طول کانال سرپستانک، طول مخزن سرپستانک، ضخامت دیواره سرپستانک و قطر دیواره بین مخزن سر پستانک به ترتیب ۸/۸۷، ۱۰/۳۷، ۱/۷۵ و ۶/۴۴ میلی متر بدست آمد؛ هیچ تفاوت معناداری بین غدد جلو و عقب در یک غده پستانی مشاهده نگردید.

نتیجه گیری و کاربرد بالینی- تفاوت در مشاهده ساختارهای مختلف غدد پستانی وابسته به حضور و یا عدم حضور شیر می باشد. بنابراین توصیه می شود اولتراسونوگرافی در مادپانه‌های شیروار انجام شود.

کلید واژگان- مادپان اسبچه خزر، غدد پستانی، اولتراسونوگرافی

