



Original Study

Possibility and Reproducibility of Renal Assessing and Size Measurement by Three- Dimensional vs Two- Dimensional Ultrasonography in Dogs

Mohammad Molazem DVM

Resident of Veterinary Radiology and Diagnostic Imaging

Alireza Vajhi, DVSc

Assistant Professor of Veterinary Radiology and Diagnostic Imaging

Majid Masoudifard DVSc,

Assistant Professor of Veterinary Radiology and Diagnostic Imaging

Daruosh Vosough DVM

Resident of Veterinary Radiology and Diagnostic Imaging

Department of Clinical Sciences, Faculty of Veterinary Medicine, University of Tehran, Tehran-Iran.

Abstract

Objective- To determine the possibility and reproducibility of three-dimensional ultrasonography (3DUS) and comparison of the achieved measurements to normal two-dimensional ultrasonography (2DUS)

Design- Descriptive study

Animals- 10 young mixed normal dogs, age 1.5-2.5 year, weighing 9.7-12 kg

Corresponding author:

Alireza Vajhi, Department of Clinical Sciences, Faculty of Veterinary Medicine, University of Tehran, P.O.Box: 14155-6453, Tehran-Iran.

Telephone#: 0098 912 2729351

Fax#: 0098 21 66933222

E-mail: avajhi@ut.ac.ir

Procedure- Renal width, length, and depth measured in coronal and transverse sections. The measurements were taken in both 2DUS and 3DUS scans. Each kidney was imaged five times in coronal and transverse section and the measurements were recorded for each image.

Statistical analysis- Descriptive analysis, paired t-test

Results- The mean difference of the measurements obtained by 3DUS in compare with 2DUS was: 0.17 cm for renal length, 0.08 cm for renal width, and 0.13 cm for renal depth. There was no significant difference between 3DUS and 2DUS.

Conclusion and Clinical Relevance- In this study the correlation was seen between 3DUS and 2DUS. The 3DUS method gives us extremely useful images for teaching and diagnosing purposes. The 3DUS image presentation can also be easily demonstrated in rotating 3D animation.

Key Words: three-dimensional ultrasonography, two-dimensional ultrasonography, renal, dog

Introduction

Real-time three-dimensional ultrasonography (3DUS) is a recently introduced imaging modality which provides three-dimensional volume rendering of structures as easily as conventional two-dimensional ultrasonography (2DUS). 3DUS has been shown to be more accurate than 2DUS imaging in different quantifications. 3DUS is a safe, fast, and non-invasive imaging technique which is being used with increasing frequency in veterinary medicine. Evaluation of the kidneys by 3DUS, the size and shape can be noted as well as the internal architecture in all orthogonal planes¹. It is therefore important to determine the accuracy and reliability of linear dimensions measured by this technique. Alternation in size of the kidneys may be accompanied by changes in shape, so it may be more useful clinically to estimate renal mass or volume. For routine use in veterinary medicine, the technique must be quick and simple. It is necessary therefore to evaluate the feasibility of a simple method of renal volumetry in the dog. The aim of this study was first to determine the possibility and reproducibility of 3DUS and then comparison of the achieved measurements to normal 2DUS scan.

Materials and Methods

A total of 10 (5 male and 5 female) young mixed normal dogs (1.5-2.5 years old) weighing 9.7-12 kg were selected. A General Electric Voluson 730-Pro with a 6-12 MHz linear array 3D-Volume transducer was used to perform images. A protocol was established for the 3D ultrasonographic examination of each kidney in the dog. The animal was placed in dorsal recumbency. All the abdominal hair was clipped ventral to the sublumbar muscle and over the last two intercostals spaces. The skin was prepared by cleaning and plenty of acoustic gel. All the cases were put into deep anesthesia by using Acepromazine (0.1 mg/kg, IM) and Ketamin (10 mg/kg, IM) and then attached to respiratory ventilator apparatus to avoid respiratory motion by artificial apnea during 3DUS scanning². The kidney was found by 2D scan initially, lying superficially in each case just beneath the abdominal wall.³

Two standard planes of initially 2DUS scan were imaged in each kidney:

Coronal section:

The plane of section was taken along the long axis of the kidney, and altered until the image size was maximal and the renal pelvis could be seen clearly. 3DUS images were then obtained with the proper adjustment and taking the measurements repeated for this technique too.

Transverse section:

The head of the transducer was then rotated through 90° to achieve a transverse section. Adjustments were made until the section was as round or oval as possible, with no tendency to obliquity, and the renal pelvis

could be clearly seen. The width and depth were measured. The values for renal width obtained on coronal and transverse sections were combined to give an average renal width. 3DUS was performed by the same investigator immediately after initial 2DUS and taking the measurements repeated for this technique too.

Two problems were considered; reproducibility and comparison with 2DUS kidney dimensions.

Each kidney was imaged five times in coronal section and five times in transverse section and the measurements recorded for each image. The reproducibility of each measurement was then assessed.

3DUS results were graded with respect to image quality and compared with results of 2DUS by using the mean difference.

Results

Time for the 3DUS acquisition for both kidneys was 3 minutes on average. A total of 20 kidneys in 10 dogs were evaluated. Finding the best plan for measuring correctly was much easier in 3DUS than 2DUS and it needed less to investigate all the aspects of the kidney. By using "Niche mode" and "Magic cut" which were two programs helping better assessing the kidney, all desire points of the image were under the operator vision (Fig. 1 and 2). The age and sex differences were not statistically significant.

When comparing the measurement of renal width on the coronal sections and on the transverse sections, the reproducibility of measurements was comparable. Application of a paired t-test showed no significant difference between the populations.

Application of a paired t-test showed no significant difference between the mean renal width, length, and depth measured in 3DUS and the means of 2DUS ($P < 0.001$) and their mean differences were 0.08 cm, 0.17 cm, and 0.13 cm respectively (Table 1).

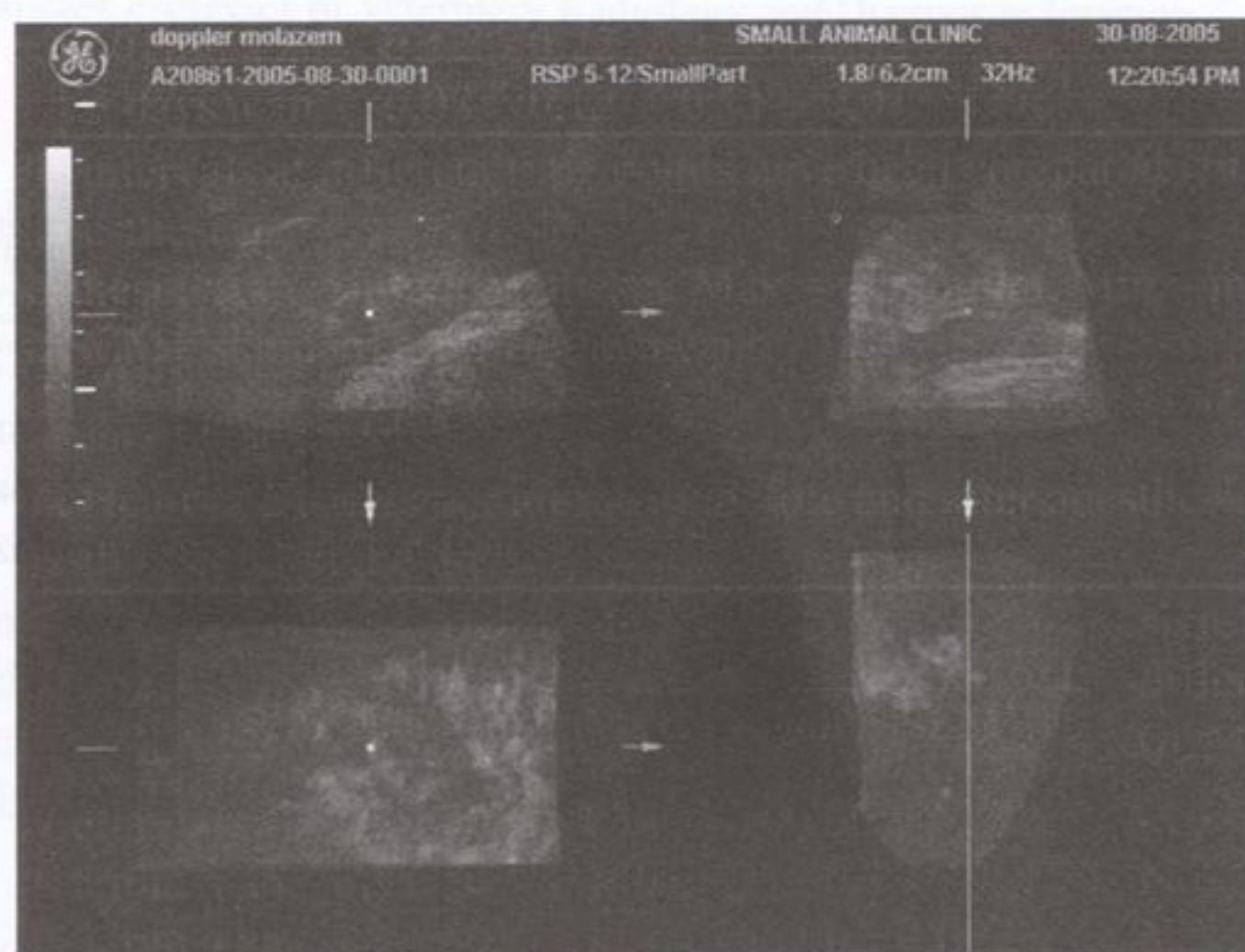

Fig 1: Orthogonal 3D ultrasonographic image of the dog's kidney and making magic cut to omit the useless parts

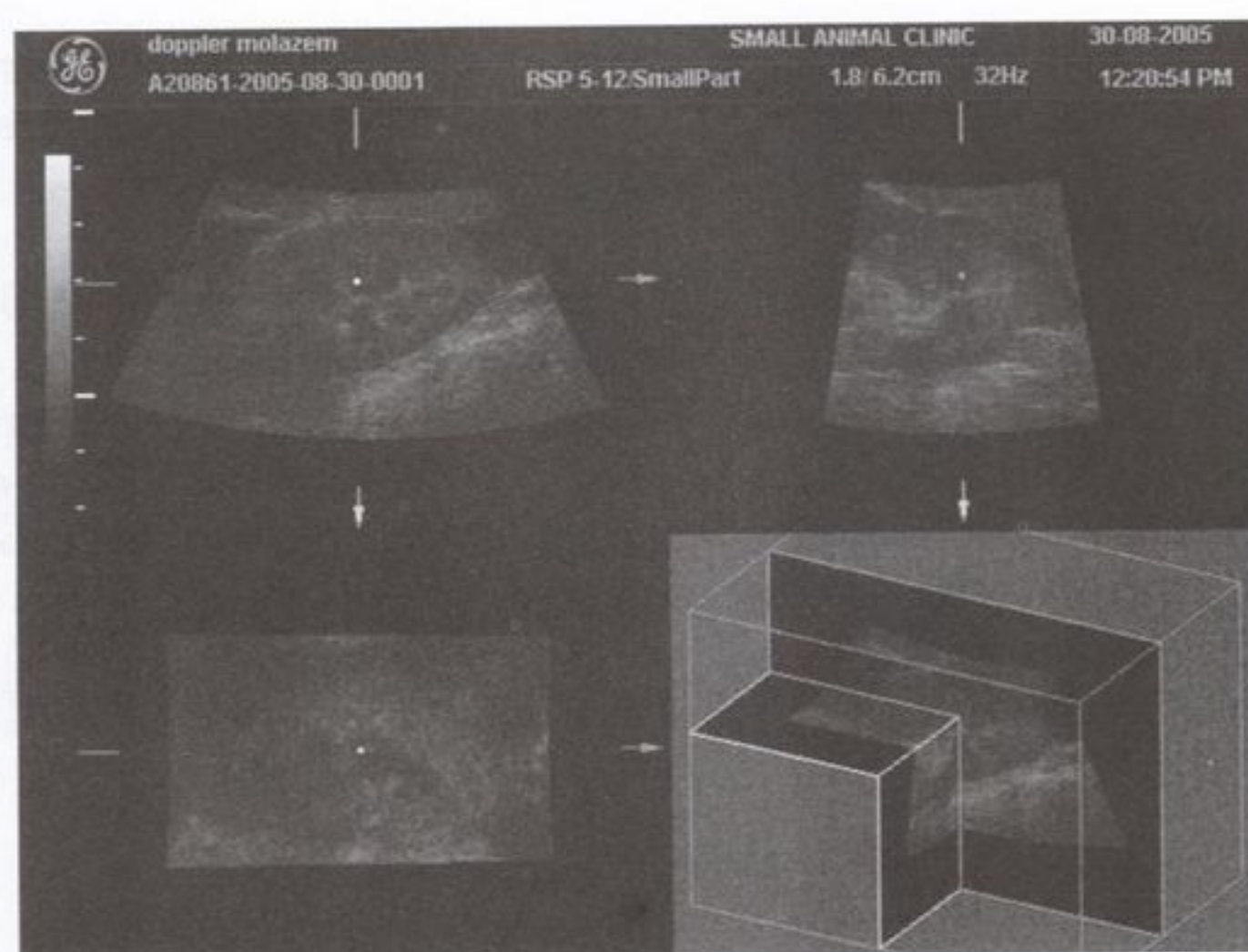


Fig 2: Niche mode 3D ultrasonographic image of the dog's kidney

Table 1: Statistical summary of three-dimensional and two-dimensional ultrasonographic measuring in dog's kidney:

	Paired t-test	Mean (cm)	Mean difference (cm)
Renal length in 3DUS	P<0.001	6.32	0.17
Renal length in 2DUS		6.15	
Renal width in 3DUS	P<0.001	3.08	-0.08
Renal width in 2DUS		3.16	
Renal depth in 3DUS	P<0.001	4.88	0.13
Renal depth in 2DUS		4.75	

Discussion

Previous authors have noted a statistically significant correlation between renal measurements in 2DUS and at necropsy; in this study the correlation was also seen between 3DUS and 2DUS which shows logically a correlation to necropsy, so for the "animal's right" the dogs were not sacrificed.^{4,5}

The 3DUS image reconstruction required less than three minute and its reconstruction can be performed in real-time too. The 3DUS method gives us extremely useful images for teaching and diagnosing purposes. The 3D image presentation can be easily demonstrated in video using the rotating 3D animation too. Besides the improved volume assessment 3DUS offers, other benefits that support its use are as follow: 3DUS requires less time for examination of the patient, although more time is necessary afterward for evaluation of the 3DUS data. 3DUS enables a multiplanar view that may show abnormalities in critical sections, a capability that is not achievable by using 2DUS^{6,7,8}. 3DUS offers the potential for creation of rendered views (e.g., for comprehensive demonstration of the dilated collecting system in patients with hydronephrosis⁶). 3DUS offers an improved standardization with better inter- and intraobserver variabilities. 3DUS creates optimal information for comparison of data obtained during US follow-up and/or for comparison of results with those of other imaging modalities. Finally, 3DUS may serve as an ideal teaching and counseling tool, as one can virtually "rescan" the area and examine any anatomic relationship or structure, without the patient's presence being required, just by scrolling through the 3DUS data set.

3DUS relies on the quality of the 2DUS source images. Since a good 2DUS acquisition is compulsory, some investigator dependency will remain^{9,10}. Structures and regions not seen with 2DUS (e.g., because of

interfering structures, restricted acquisition size, or insufficient penetration) or areas not included for reconstruction cannot be visualized, and repeated 3DUS acquisitions may be necessary (e.g., for large abnormalities that are difficult to image in their entirety, particularly when the 3DUS transducers with a restricted acquisition range are used)^{7,8,11}.

A variety of artifacts that are present at 2DUS may then be imported into the 3DUS data set and distort the 3DUS image by being amplified by the reconstruction algorithm throughout all planes. Furthermore, phenomena and artifacts specific to 3DUS (derived from data acquisition, reconstruction, or rendering) have to be considered¹². Patient motion (e.g., that caused by breathing distorts 3DUS data so unfortunately, in this study, the dogs had to put into deep anesthesia that 3D imaging was able to be scanned apart from respiratory motion. Therefore it was inevitable to use such drugs. However the data is supposed to obtain in the same condition to be dependable.^{7,8,10}

Finally we consider the 3DUS a reliable, easy, fast, and accurate enough to be used in veterinary practice.

Acknowledgement

The authors acknowledge the contributions and helps of Davod Faskhoodi for his kind assistances.

References

1. Riccabona M, Fritz GA, Schöllnast H, et al. Hydronephrotic kidney: Pediatric three-dimensional US for relative renal size Assessment—Initial Experience. *Radiology* 2005; 236:276-283.
2. Katzung T, Trevor AJ. *Examination and board review pharmacology*. 3rd ed. Prentice-hall: John Dolan, 1993; pp: 143-162.
3. Lawrence JK, Christopher RL. Comparative organ imaging. *Vet Radiol* 1989; 30: 133-141.
4. Barr FJ. Evaluation of ultrasound as a method of assessing renal size in the dog. *J Small Anim Prac* 1990; 31:174-179.
5. Zagzebski, J. A., Banjavic, R. A. & Tolbert, D. D. Analysis of 'in vivo' volume measurements obtained with diagnostic ultrasound. *Med Physics*, 1976; 3:319-323.
6. Gilja OH, Thune N, Matre K, et al. In vitro evaluation of three dimensional ultrasonography in volume estimation of abdominal organs. *Ultrasound Med Biol* 1994; 20:157-165.
7. Stanojevic M, Hafner T, Kurjak A. Three-dimensional (3D) ultrasound: a useful imaging technique in the assessment of neonatal brain. *J Perinat Med* 2002; 30:74-83.
8. Riccabona M, Fritz G, Ring E. Potential applications of three-dimensional ultrasound in the pediatric urinary tract: pictorial demonstration based on preliminary results. *Eur Radiol* 2003; 13:2680-2687
9. Nelson TR, Pretorius DH, Sklansky M, et al. Three-dimensional echocardiographic evaluation of fetal heart anatomy and function: acquisition, analysis and display. *J Ultrasound Med* 1996; 15:1-9.
10. Riccabona M, Nelson TR, Resch B, et al. Potential of three-dimensional ultrasound in neonatal and pediatric neurosonography: a pictorial essay. *Eur Radiol* 2003; 13:2082-2093.
11. Fritz GA, Riccabona M, Bohdal G, et al. Accuracy of renal volume assessment in children using three-dimensional sonography [in German]. *Rofo* 2003; 175:540-546.
12. Nelson TR, Pretorius DH, Hull AD, et al. Sources and impact of artifacts on clinical 3DUS imaging. *Ultrasound Obstet Gynecol* 2000; 15:1-11.

ارزیابی و اندازه گیری ابعاد کلیه با دو روش اولتراسونوگرافی دو بعدی و سه بعدی

و تکرار پذیری آن در سگ

دکتر محمد ملازم

رزیدنت بخش جراحی دامپزشکی، گروه علوم درمانگاهی، دانشکده دامپزشکی، دانشگاه تهران، تهران، ایران.

دکتر علیرضا وجهی

استادیار بخش رادیولوژی، گروه علوم درمانگاهی، دانشکده دامپزشکی، دانشگاه تهران، تهران، ایران.

دکتر مجید مسعودی فرد

استادیار بخش رادیولوژی، گروه علوم درمانگاهی، دانشکده دامپزشکی، دانشگاه تهران، تهران، ایران.

دکتر داریوش وثوق

رزیدنت بخش رادیولوژی، گروه علوم درمانگاهی، دانشکده

گروه آموزشی علوم درمانگاهی، دانشکده دامپزشکی دانشگاه تهران، تهران- ایران

هدف: ارزیابی اولتراسونوگرافی سه بعدی کلیه و تکرارپذیری آن و همچنین مقایسه اندازه های بدست آمده با نتایج حاصل از روش دو بعدی بوده است.

طرح: مطالعه توصیفی

حیوانات: ده قلاده سگ جوان سالم نژاد مخلوط با سن بین ۲/۵ - ۷/۵ سال و با وزن ۱۲ - ۹/۷ کیلوگرم

روش: اندازه گیری عرض، طول و قطر کلیه در سونوگرافی دوبعدی و سه بعدی در مقاطع عرضی و کروئال صورت گرفت. هر سه بعد کلیه پنج بار اندازه گیری شدند. اختلاف میانگین اندازه های بدست آمده در روشهای سه بعدی و دو بعدی محاسبه گردید.

تجزیه و تحلیل آماری: آنالیز توصیفی، paired t-test

نتایج: اختلاف میانگین اندازه های بدست آمده در اولتراسونوگرافی سه بعدی و دو بعدی محاسبه گردید، این اختلاف برای طول کلیه ۰/۱۷ سانتی متر، پهنا ۰/۰۸ سانتی متر و ضخامت ۰/۱۳ سانتی متر بود. اختلاف معناداری بین اندازه های بدست آمده از اولتراسونوگرافی دو بعدی و سه بعدی وجود نداشت.

نتیجه گیری: این مطالعه نشان داد که بین اندازه های حاصل از سونوگرافی دوبعدی و سه بعدی ارتباط معناداری وجود دارد که این خود می تواند نشانگر ارتباط بین اندازه های بدست آمده از سونوگرافی سه بعدی و کالبد گشایی باشد.

کید واژه ها: اولتراسونوگرافی سه بعدی، اولتراسونوگرافی دو بعدی، کلیه، سگ