



Original Study

The Use of Tail Vertebra as Cortical Bone Graft in Experimentally Induced Ulnar Defects in Dogs

Ali Baniadam, DVSc,

Associate Professor of Veterinary Surgery

Fereidoon Saberi Afshar, DVSc,

Assistant Professor of Veterinary Surgery

Ali Reza Ghadiri, DVSc,

Assistant Professor of Veterinary Radiology

Zahra Karimi Jalalabadi, DVM,

Graduated from the Faculty of Veterinary Medicine, Shahid Chamran University, Ahvaz, Iran.

Department of Surgery, Faculty of Veterinary Medicine, Shahid Chamran University, Ahvaz, Iran.

Abstract

Objective- To evaluate tail vertebra as an autogenous cortical bone and cancellous bone for filling ulnar segmental bone defect in dogs.

Design- Experimental study.

Corresponding author:

Ali Baniadam

Address: Department of Surgery, Faculty of Veterinary Medicine, Shahid Chamran University, Ahvaz, Iran.

Telephone #: +98 611 3363217

Fax #: +98 611 3360807

E-mail address: baniadam@sua.ac.ir

Animals- Eight adult mongrel dogs with an average age of 37.5 months and average body weight of 17.62 kg.

Procedure- The animals were randomly divided into two groups. A bone defect (2.5-cm) was created on the middle portion of the right ulna in all dogs. Ulna was fixed by intramedullary pinning. In 5 dogs (test group) ulnar bone defects were filled with tail vertebra, after tail docking. Cancellous bone harvested from the iliac crest was also used to promote bone healing in the host-graft interfaces. In the other 3 dogs (control group) ulnar bone defects were not filled. Postoperative clinical assessment was included measurement of body temperature, heart rate, respiratory rate, and evaluation of the degree of lameness. Radiographic assessment of bone based on the process of bone healing and consolidation of the host-graft interface, periosteal reaction, and soft tissue swelling were performed immediately and at the weeks 1, 3, 5, 7, 10, 13 and 17 after surgery.

Results- Significant difference ($P < 0.05$) in the degree of lameness and soft tissue swelling were observed between the two groups. The difference of the mean of periosteal reaction was not significant between the two groups. Bone healing process was completed in the cortical autograft group and clinical union was observed in 100% of dogs in comparison with nonunion in 100% of animals in the control group.

Conclusion and Clinical Relevance- The results of this study showed that tail vertebra can be used as an excellent material for filling of segmental ulnar bone defects in dogs.

Key Words: cortical graft, tail vertebra, bone graft, ulna, dog

Introduction

Bone grafts are the most common methods for treating various types of bone defects, nonunions, delayed unions, osteomyelitis and large bone defects. Different bone grafts include autograft, isograft, allograft, alloimplant and xenograft.^{1,2,3} Depending on the type of graft, bone performs four different functions when it is incorporated into host tissue. These include osteogenesis, osteoinduction, osteoconduction, and mechanical support.^{1,4} Bone grafts in clinical practice are primarily used to help achieve bony union in cases of indolent healing of fractures or pseudoarthrosis arising after fracture; to supplement the healing of certain fresh fractures which open reduction and internal fixation are used; to promote fusion (arthrodesis) of joints damaged by injury,⁵ disease, or deformity; and to fill defects in bone created by tumors, chronic infection, or injury.^{1,3} Cancellous and corticocancellous bone grafts are the most common autogenous grafts used in orthopedic surgery. Because autogenous grafts are collected from the same patient, they provide early revascularization and osteoinduction, osteogenesis and osteoconduction, but cancellous and corticocancellous grafts do not provide structural support like cortical grafts. Disadvantages to this type of graft include a limit to the volume, size, and type of graft that can be obtained; increased time under general anesthesia and morbidity at the collection sites.^{1,6,7} Because of these limiting factors, other bone grafting techniques have been developed. These include vascularized autografts,^{8,9} freeze-dried allografts chips,⁸ segmental allografts⁸ demineralized bone matrix (DBM),^{8,10} bone morphogenetic protein (BMP),^{8,2,10,11,12} bone marrow^{13,14} hormones,^{15,2} synthetic bone substitutes¹³ and electrical stimulation.¹⁶ Cortical grafts provide mechanical support as well as scaffolding for osteoconduction.^{2,17}

In this study we tried to present a new source of cortical autograft in dogs. Tail vertebra used as a source of cortical bone graft and cancellous bone graft used to promote healing in the interfaces of tail vertebra and recipient bone.

Material and Methods

This study was carried out on 8 mongrel dogs with an average age of 37.5 months and average body weight of 17.62 kg. The animals were divided into two groups randomly. Before surgery lateral and anteroposterior radiographs were obtained from the right forelimb in all dogs. The sites of surgery were prepared aseptically including tail, the region of iliac crest and right forelimb from humerus down.

After inducing anesthesia using acepromazine (0.08 mg/kg) and thiopental sodium (10 mg/kg) the anesthesia was maintained using halothane. At first, tail docking was performed for the test group and then a part of the tail included the third and fourth vertebrae was prepared for grafting. After incising the skin, all of the muscle and debris was removed from the tail and one of the tail vertebrae which had the same length as needed prepared for grafting. After preparation of the tail vertebra, another surgeon incised the caudolateral aspect of the right forelimb approximately on the middle portion of the ulna at which the radius and ulna were apart. After retracting the muscles, the ulna was exposed and a 2.5-cm length of ulna was surgically removed using Gigli saw. At the same time an intramedullary pin which was appropriate for the size of medullary canal was selected. According to the size of pin, the tail vertebra was perforated using the appropriate drill bit, and the pin was introduced through the vertebra to be certain about the size of vertebra hole. The ulna fixed using intramedullary pinning and the tail vertebra was inserted to the defect. Cancellous bone was harvested from the previously prepared donor site (iliac crest) and placed around the host-graft interfaces. After suturing the muscles, the skin was closed using nylon 2/0. In the control group no material was used to fill the segmental bone defect as a model of nonunion.¹³

The animals received penicillin and streptomycin before surgery and for 7 days after operation. The animals were followed up for 17 weeks to obtain radiographic records. Radiography was performed immediately and at 1, 3, 5, 7, 10, 13 and 17 weeks after surgery.

Observations of vital signs and the appearance of the surgical wound recorded daily for 2 weeks and the degree of lameness was recorded for 8 weeks. One examiner determined the degree of lameness. The following determinants were scored by the examiner: 0 = non weight bearing, 1 = only claws touching the ground, 2 = weight bearing with severe lameness, 3 = weight bearing with mild lameness, 4 = weight bearing without lameness. The amount of periosteal reaction and soft tissue swelling was evaluated based on a scale of 0 (without), I (minimal), II (moderate), or III (proliferative). Radiographic union based on consolidation of the host-graft interfaces and remodeling was graded on a scale of 0 to VI. The analysis of the variances and Kruskal-Wallis using SPSS 9 was used for the analysis of the data. $P < 0.05$ was considered statistically significant.

Results

The animals were under close observation for at least two weeks. The sutures were removed 14 days after surgery without any complication. The heart rate, respiratory rate and body temperature were at the normal range after operation. The mean of periosteal reaction also showed no significant difference between the two groups during the study. Soft tissue swelling disappeared sooner in the test group so that the mean of soft tissue swelling showed significant difference at the week of 5 and 7 ($P < 0.05$). Lameness disappeared much sooner in the tail vertebra group. There was significant difference between two groups from the day 5 to 49 ($P < 0.05$) (Fig. 1). Bone healing process was completed in the cortical autograft group and clinical union was observed in 100% of dogs in comparison with nonunion in 100% of animals of the control group (Fig. 2 - 4).

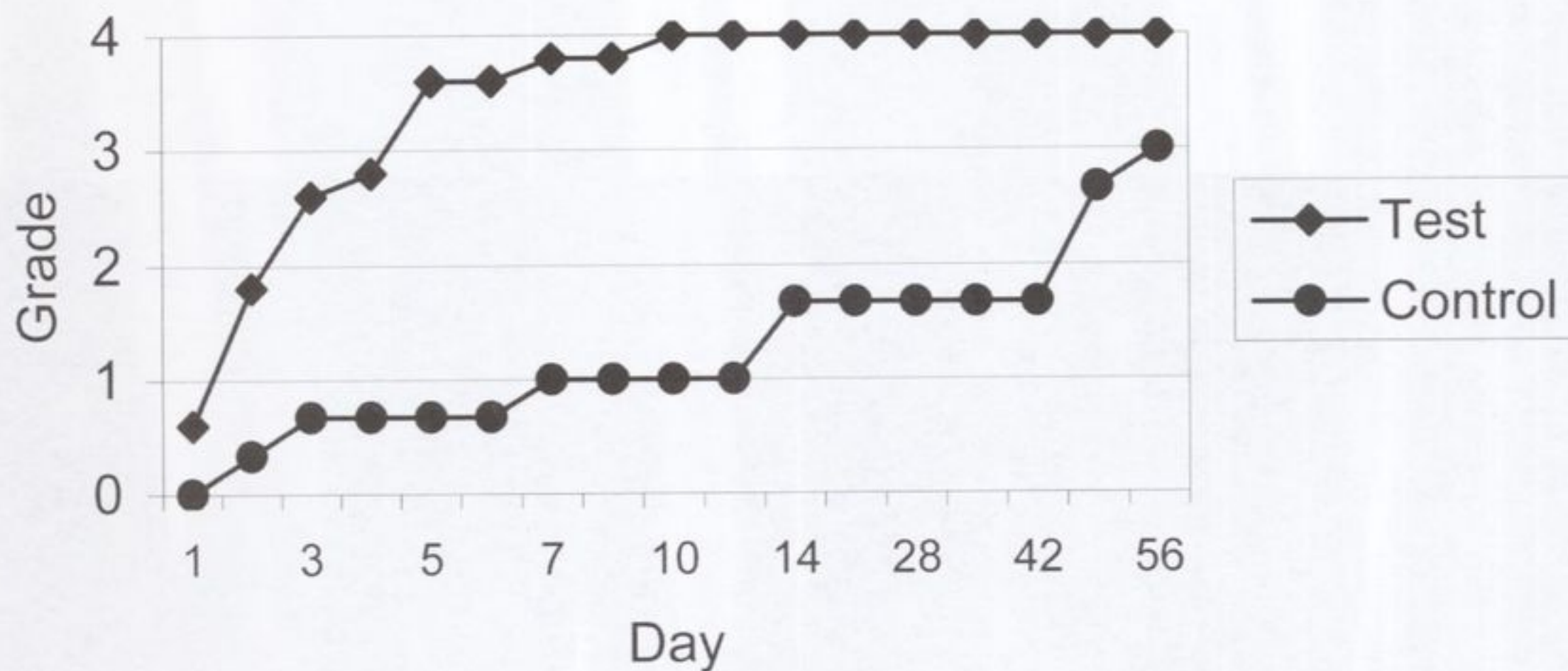


Fig. 1: Mean of lameness grade* in the test and control group**. The lameness disappeared much sooner in the test group.

* 0 = non weight bearing, 1 = only claws touched the ground, 2 = weight bearing with severe lameness, 3 = weight bearing with mild lameness, 4 = weight bearing without lameness

** There was significant difference between the two groups from the day 5 to 49 ($P < 0.05$).

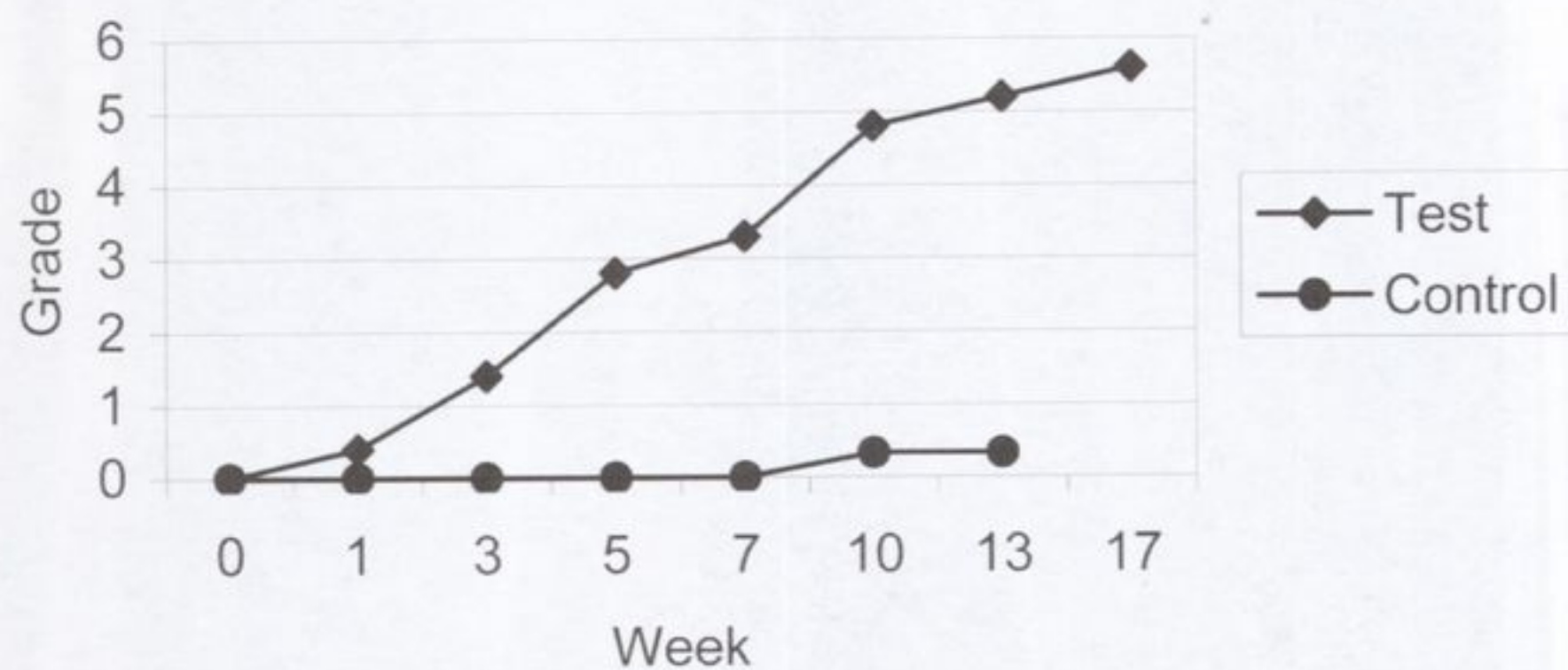

Fig. 2: Mean of bone healing grade* in the test and control group**.

* A score of 0 equaled nonunion. I-IV equaled different stages of bone healing and consolidation of the host-graft interfaces, V equaled clinical union, and VI equaled remodeling.

** Clinical union was observed in 100% of dogs in the test group.

Material and Methods

This study was carried out on 3 mongrel dogs, both of which were of 12-14 months old and average body weight of 47.5 kg. The animals were divided into two groups: control and test group. Before surgery, lateral and anteroposterior radiographs were obtained from the dogs for baseline. The study of the study group continued postoperatively, and the progress of the repair of the intervertebral disc was monitored.

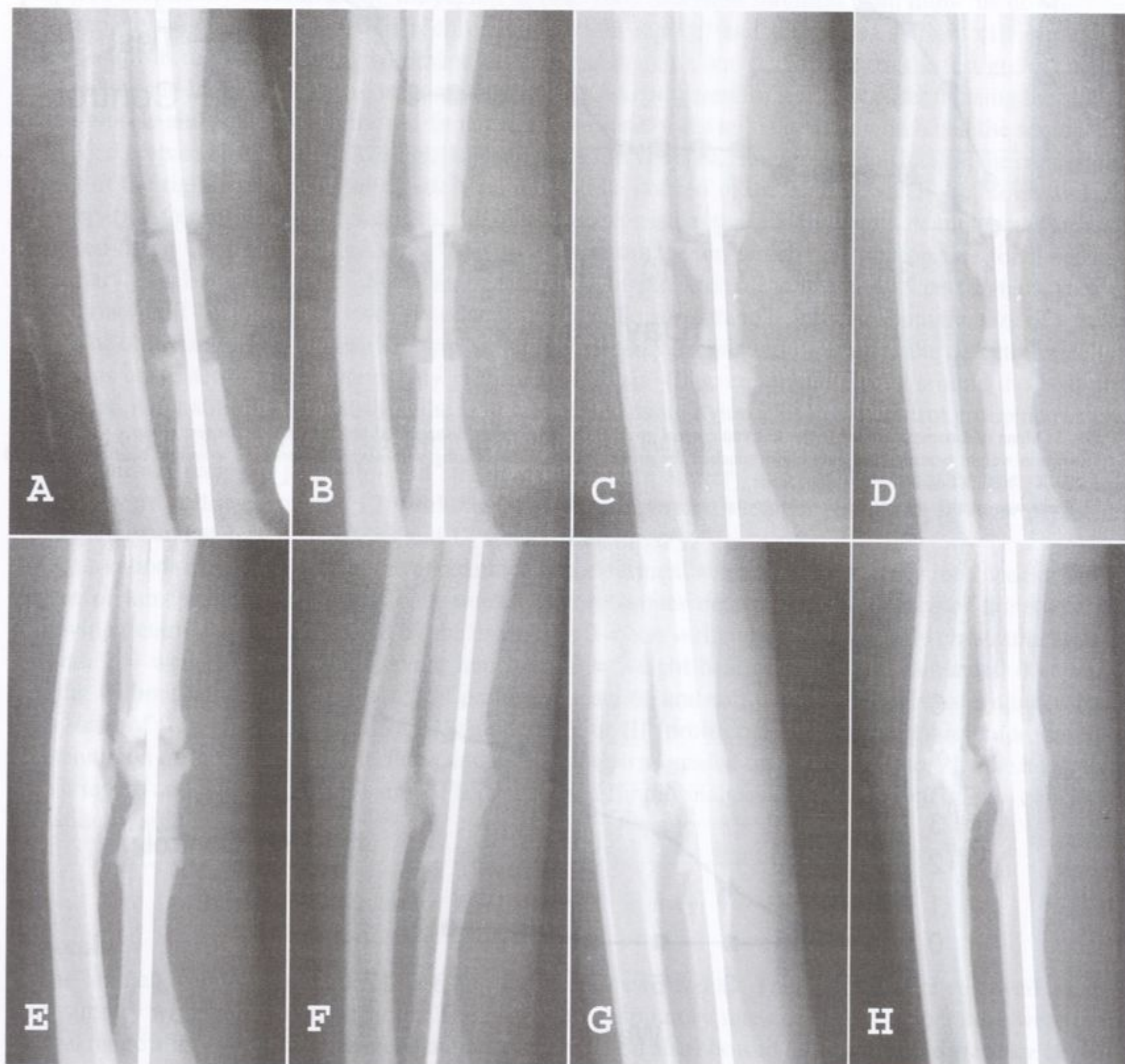


Fig. 3: Radiographs taken from dog No. 3 (test group). (A) immediately postoperatively, (B) one, (C) three, (D) five, (E) seven, (F) ten, (G) 13, and (H) 17 weeks following operation.

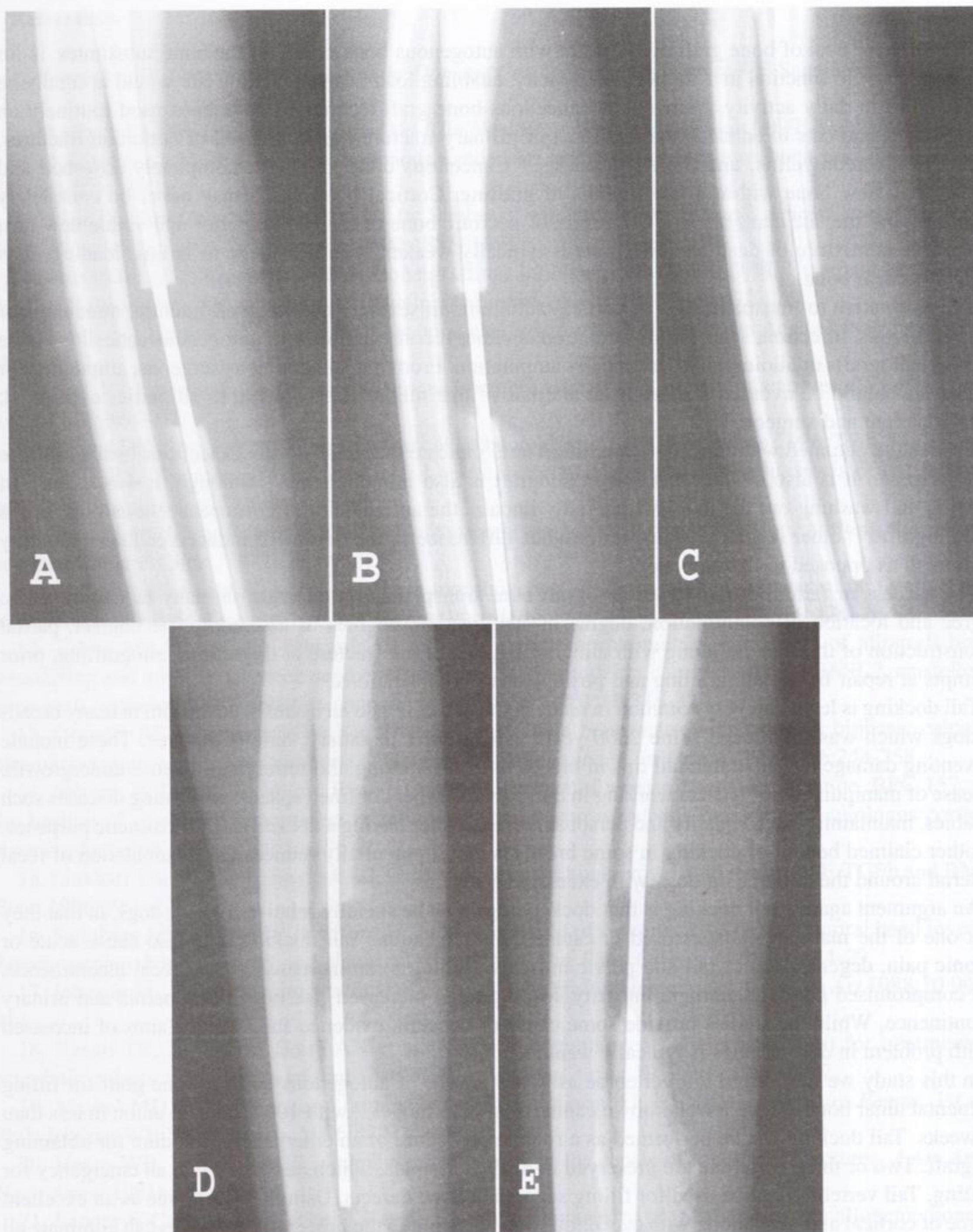


Fig. 4: Radiographs taken from dog No. 6 (control group). (A) immediately postoperatively, (B) three, (C) five, (D) ten, and (E) 13 weeks following operation.

Discussion

The ultimate goal of bone grafting, whether with autogenous bone or any of the bone substitutes, is for the grafted site to function in a supportive capacity, enabling load bearing that the site would normally be subjected to in daily activity. Autogenous cancellous bone graft techniques have been used routinely on dogs, horses and cats to enhance the treatment of primary fracture repair, delayed or nonunion fractures, bone cysts, osteomyelitis, and joint arthrodesis.¹⁸ Cancellous bone grafts are completely absorbed and replaced by new bone within a few months of grafting. Cortical bone grafts may never be completely absorbed, and the site can remain a composite of necrotic bone of the original graft and viable new host bone. This admixture of dead and live bone is typically weaker, with resistance to fatigue loading, than normal cortical bone.¹⁹

The alternative to transplantation of cortical autografts in severely comminuted fracture, nonunions or delayed unions, infection, sequestrum formation is either reconstruction with autogenous cancellous bone grafting, allografts or alloimplants, and finally amputation. From our standpoint as surgeons, amputation or euthanasia should be avoided if there is an alternative that might be acceptable to all parties concerned; clients, patient and surgeon.²⁰

The results obtained with leukocyte migration tests indicate that fresh corticocancellous bone grafts are immunogenic. It is also evident that frozen allograft is also immunogenic.³ Although, it was stated that freezing and washing out the marrow markedly impairs the antigenicity of corticocancellous bone grafts and allografts,^{3,5} other results revealed no obvious difference in the degree of induced cellular immunity from fresh as opposed to frozen bone.²¹

The success or failure of diaphyseal allograft bone transplantation depends on many factors includes: degree and location of comminution, degree of stabilization, degrees of osteotomy site contact, partial reconstruction of the fracture along with allografting, age of the fracture at the time of allografting, prior attempts at repair before allografting and postoperative complications.²²

Tail docking is legal and very common in many countries. It is also an established custom in many breeds of dogs which was introduced some 2000 years ago in order to satisfy various motives. These include preventing damage to vulnerable tail tips in breeds used for hunting and retrieving in dense undergrowth, for ease of manipulation of terriers working in burrows and other confined spaces, preventing diseases such as rabies, maintaining breed quality and personal preference for having a docked dog for cosmetic purposes. Another claimed benefit of docking in some breeds is that it potentially reduces the accumulation of fecal material around the tail area on dogs with excessive coats.^{23,24}

An argument against tail docking is that docked dogs may be socially relative to other dogs, in that they lack one of the main appendages used in canine communication. Tail docking may also cause acute or chronic pain, degeneration of tail and pelvic muscles, leading to an increased risk of fecal incontinence, and compromised pelvic diaphragm integrity, leading to an increased risk of perineal hernia and urinary incontinence. While the studies provide some cause of concern, evidence supporting claims of increased health problem in docked dogs is typically weak.³⁰

In this study we introduced tail vertebrae as a new source of autogenous cortical bone graft for filling segmental ulnar bone defect, a well known canine nonunion model,¹³ with 100% clinical union in less than 17 weeks. Tail docking can be performed as a routine procedure or an emergency procedure for obtaining the graft. Two or three vertebrae are preserved in docked animals, which can be used in an emergency for grafting. Tail vertebrae can be used for filling segmental bone defects. Using tail vertebrae as an excellent source of cortical autograft along with cancellous bone grafting in the host-graft interfaces can eliminate all the disadvantages of cortical allografts. However, for harvesting the graft, another operation must be performed which can prolong the duration of anesthesia, and also requires more assistants.

Acknowledgment

The authors would like to express their thanks to the research council of the Shahid Chamran University of Ahvaz for their help and financial support of this project.

References

1. Alexander JW. *Orthopedic Surgery of the Dog and Cat*. 3rd ed. Philadelphia: WB Saunders Co, 1985;38-43.
2. Martinez SA, Walker T. Bone grafts. *Vet Clin North Am: Small Anim Pract* 1999;29:1207-1219.
3. McLaughlin RM, Roush JK. Autogenous cancellous and corticocancellous bone grafting. *Vet Med* 1998;83:1071-1074.
4. Millis DL, Martinez SA. Bone grafts. In: Slatter D, ed. *Text Book of Small Animal Surgery*. 3rd ed. Vol 1. Philadelphia: WB Saunders Co, 2002:1875-1891.
5. Nunamaker DM, Rhinelander FW. Bone grafting. In: Newton C.D. and D.M. Nunamaker, eds. *Text Book of Small Animal Orthopaedics*. Philadelphia: Lippincott Co, 1985;519-522.
6. Moseley C. Complications of iliac crest bone grafting, in *Proceeding of Am Acad Orthop Surg Annu Meet* 2000.
7. Seiler JG, Johnson J. Iliac crest autogenous bone grafting: donor site complications. *J South Orthop Assoc* 2000;9:91-97.
8. Lehman DE, Rougraff BT. Recent advances in bone graft. *Curr Opin Orthop* 1996;7:71-74.
9. Moore RS. The role of free vascularized grafts in the management of osteonecrosis of the femoral head. *Uni Penn Orthop J* 2000;13:89-95.
10. Vaccaro AR, Chiba K, Heller JG et al. Contemporary concepts in spine care: Bone grafting alternatives in spinal surgery. *Spine J* 2002;2:206-215.
11. Wolfe MW, Salkeld SL Cook SD. Bone morphogenetic proteins in the treatment of non-unions and bone defects: Historical perspective and current knowledge. *Uni Penn Orthop J* 1999;12:1-6.
12. Zabka AG, Pluhar RB, Edwards III RB et al.: Histomorphometric description of allograft bone remodeling and union in a canine segmental femoral defect model: a comparison of rhBMP-2, cancellous bone graft, and absorbable collagen sponge. *J Orthop Res* 2001;19:318-327.
13. Grundel RE, Chapman MW, Yee T, et al. Autogeneic bone marrow and porous biphasic calcium phosphate ceramic for segmental bone defects in the canine ulna. *Clin Orthop* 1994;266:244-258.
14. Sebecic B, Nikolic V, Sikiric P et al. Osteogenic effect of a gastric pentadecapeptide, BPC-157, on the healing of segmental bone defect in rabbits: a comparison with bone marrow and autologous cortical bone implantation. *Bone* 1999;24:195-202.
15. Linkhart TA, Mohan S, Baylink DJ. Growth factors for bone growth and repair: IGF, TGFb and BMP. *Bone* 1996;19:1-12.
16. Steinberg ME, Larcom P, Strafford B., et al. Treatment of osteonecrosis of the femoral head by core decompression, bone grafting, and electrical stimulation. *Uni Penn Orthop J* 1997;10:24-29.
17. Johnson AL. Principles and practical of cortical-bone grafting techniques. *Con Edu Art* 1988;10:906-913.
18. Kasari TR, Taylor TS, Baird AN et al.: Use of autogenous cancellous bone graft for treatment of osteolytic defects in phalanges of three cattle. *J Am Vet Med Assoc* 1992;201:1053-1057.
19. Markel MD. Bone grafts and bone substitutes. In: Nixon AJ, ed. *Equine Fracture Repair*. 1st ed. Philadelphia: WB Saunders Co, 1996;87-91.
20. Henry WB, Wadsworth PL. Diaphyseal allografts in the repair of long bone fractures. *J Am Anim Hosp Assoc* 1981a;17:525-534.
21. Langer F, Czitrom A, Pritzker KP et al. The immunogenesity of fresh and frozen allogenic bone. *J Bone Joint Surg* 1975;57A:216-220.
22. Henry WB, Wadsworth PL. Retrospective analysis of failures in the repair of severely comminuted long bone fractures using large diaphyseal allografts. *J Am Anim Hosp Assoc* 1981b;17P:535-546.
23. Bennett PC, Perini E.: Tail docking in dogs: a review of the issues. *Aust Vet J* 2003;81:208-218.
24. Krahwinkel DJ, Bone DL. Surgical management of specific skin disorders. In: Slatter D, ed. *Text Book of Small Animal Surgery*. 3rd ed. Vol. 1. Philadelphia: WB Saunders Co, 1985;513-514.

استفاده از مهره دمی به عنوان پیوند استخوان کورتیکال در نقایص تجربی ایجاد شده در استخوان زندزیرین در سگ

دکتر علی بنی آدم

دانشیار بخش جراحی دانشکده دامپزشکی دانشگاه شهید چمران اهواز، اهواز، ایران.

دکتر فریدون صابری افشار

استادیار بخش جراحی دانشکده دامپزشکی دانشگاه شهید چمران اهواز، اهواز، ایران.

دکتر علیرضا غدیری

استادیار بخش رادیولوژی دانشکده دامپزشکی دانشگاه شهید چمران اهواز، اهواز، ایران.

دکتر زهرا کریمی جلال آبادی

دانش آموخته دانشکده دامپزشکی دانشگاه شهید چمران اهواز، اهواز، ایران.

هدف: ارزیابی امکان استفاده از مهره دمی به همراه استخوان اسفنجی جهت پر کردن نقیص استخوانی در استخوان زندزیرین در سگ

طرح: مطالعه تجربی

حیوانات: هشت سگ ولگرد با میانگین سن ۳۷/۵ ماه و متوسط وزن ۱۷/۶۲ کیلوگرم

روش: حیوانات به صورت تصادفی به دو گروه تقسیم شدند. یک نقیصه استخوانی (۲/۵ سانتیمتری) در بخش میانی استخوان زندزیرین همه سگها ایجاد گردید. استخوان زندزیرین با یک پین داخل مغز استخوان تثبیت شد. در پنج قلاده از سگها (گروه آزمایش) نقیصه استخوان زندزیرین پس از قطع دم با یک مهره دمی پر شد. برای افزایش سرعت التیام، استخوان اسفنجی برداشت شده از ستیغ ایلوم بین پیوند و استخوان اصلی قرار داده شد. در سه قلاده از سگها (گروه کنترل) جهت پر کردن نقیصه استخوان زندزیرین، از مادهای استفاده نشد. ارزیابی کلینیکی بعد از عمل شامل اندازهگیری درجه حرارت، ضربان قلب، تعداد تنفس و ارزیابی درجه لنگش بود. ارزیابی رادیوگرافی نیز بر اساس روند التیام و جوش خوردن پیوند با استخوان اصلی، واکنش ضریع و تورم بافت نرم در بلافاصله بعد از عمل و در هفتههای ۱، ۳، ۵، ۷، ۱۰، ۱۳ و ۱۷ بعد از جراحی صورت گرفت.

نتایج: اختلاف معنی داری ($p < 0.05$) از نظر درجه لنگش و تورم بافت نرم بین دو گروه مشاهده گردید. اختلاف واکنش ضریع بین دو گروه معنیدار نبود. در گروه پیوند استخوان کورتیکال خودی روند التیام کامل شده و جوش خوردن کلینیکی در ۱۰۰٪ از سگها حاصل گردید در حالی که در ۱۰۰٪ از حیوانات گروه کنترل استخوان جوش نخورد. نتیجه گیری - نتایج این مطالعه نشان دارد که مهره دمی میتواند به عنوان یک ماده ایده آل جهت پر کردن نقیصه استخوان زندزیرین در سگها مورد استفاده قرار گیرد.

کلید واژه ها: پیوند کورتیکال، مهره دمی، پیوند استخوان، زندزیرین، سگ