



Clinical Report

A rare congenital anomaly of wing in a pigeon chick (*Columba livia*)

Masoud Rajabioun, Hossein Kazemi Mehrjerdi, Jamshid Razmyar

Abstract

Case Description- A 20-day-old pigeon chick with left wing distal to the carpal joint into left flank presented to our avian medicine and surgery clinic.

Clinical Findings- The bird had a mal-shaped wing structure, whereas the axial skeleton, thoracic and pelvic limbs skeleton were normal radiographically and clinically, excluding the left wing. The only clinical sign observed was recumbency.

Treatment and Outcome- The affected bird underwent surgery successfully for removal of the manus. The bird did not exhibit any unusual distress after the surgery, 3 and 13 months later, except of abnormal function of corrected wing.

Clinical Relevance- Among the anomalies in birds, the most frequently occurring type is skeletal deformities. In this case the exact cause was unclear and remained unknown but based on owner's report the pigeon chick had the anomaly from first day after the birth and it might be due to a malposition in embryonic period. According to our knowledge this is the first report of such a rare condition.

Key words- Pigeon, anomaly, wing

Case Description

An approximately 20-day-old pigeon chick was referred to Ferdowsi University of Mashhad, Veterinary Teaching Hospital for abnormal shape of left wing. The left wing was into the body distal to the left carpal joint. Historically, this abnormality was seen after birth.

Clinical Findings

On physical examination, the bird was alert and the vital signs were within normal limit. The bird appeared completely normal except for the left wing distal to the carpal joint that was into the body (Fig.1). For further evaluation, lateral and ventrodorsal whole body radiographs were taken. Non significant abnormalities were seen in axial and appendicular skeleton except the presence the left wing distal to the carpal joint into the body. As an accidental finding crop and ventriculus filled by seeds that represents good bird's appetite (Fig.2). For correction of this situation and further investigation the bird was referred to avian surgery section.

Department of Clinical Sciences, Faculty of Veterinary Medicine, Ferdowsi University of Mashhad, Mashhad, Iran.
Address all correspondence to Dr. Masoud Rajabioun (DVM, DVSc), E-mail: Rajabioun@um.ac.ir

Treatment and Outcome

The bird was anesthetized with isoflurane (Isoflo, Abbott Laboratories, Chicago, IL, USA) and oxygen and placed in dorsal recumbency on a heating pad and the legs abducted caudally. The abdomen was plucked and prepared surgically for a ventral celiotomy. The skin and muscles were incised separately and wing was removed from the abdomen. Muscles were closed with 4-0 polydioxanone with a simple Continuous pattern. Skin was closed with a simple interrupted pattern using the same suture material. Anesthetic recovery was uneventful.

Postoperatively, cefazoline ([Cefazex®, Loghman pharmaceutical Co, Tehran, Iran]) 20 mg/kg was administered for three days. On palpation and visual examination, no bony fusion was seen between the wing and the other bony structure and the wing represented normal appearance (Fig.3).

Two weeks after surgery, the bird was bright and alert, and incision had healed. The bird was re-evaluated 3 and 13 months postoperatively, general status of the bird was good but the corrected wing did not show normal function, the left carpal joint was immobile (Fig.4).

Radiographic examination revealed reduced bone density and the bones to be fused together in left carpal joint due to ankylosis (Fig.5).

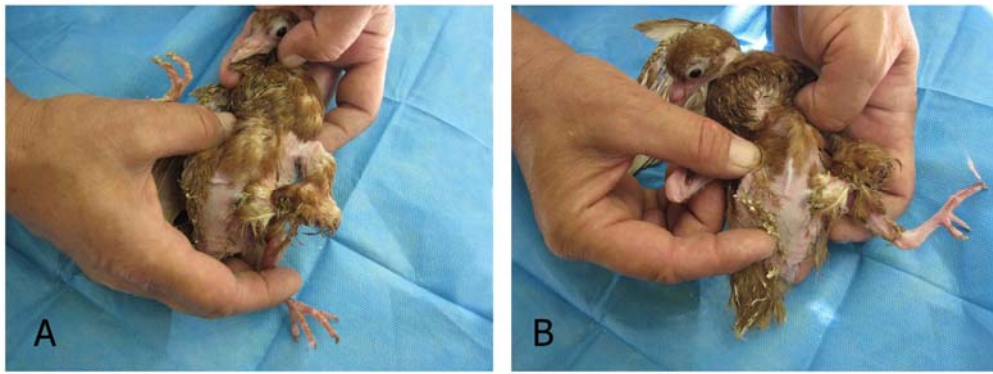


Figure 1- Gross photographs of the bird showing the location of the left wing (A,B). Note the palpable bony structure of the wing under the skin (B).

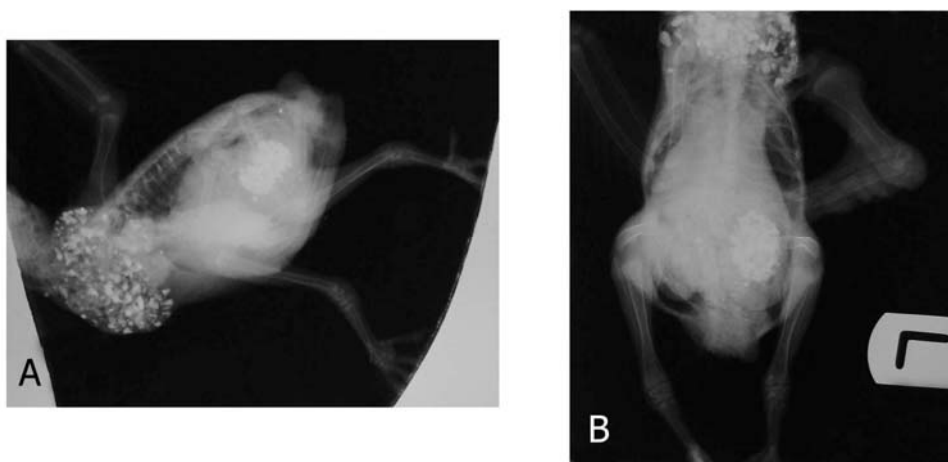


Figure 2- Lateral (A) and Ventrodorsal (B) whole body radiographs of the bird described in figure 1.

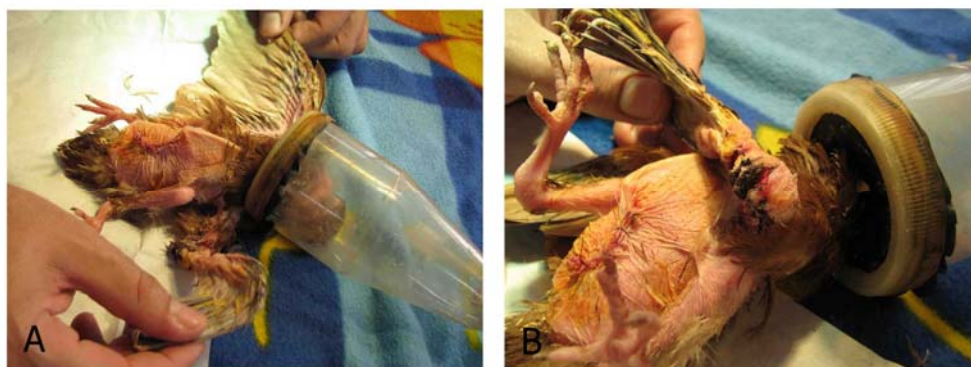

Figure 3- Gross photographs after operation. Note normal anatomical appearance of corrected wing.



Figure 4- Gross photograph of the pigeon, 13 month after surgery.

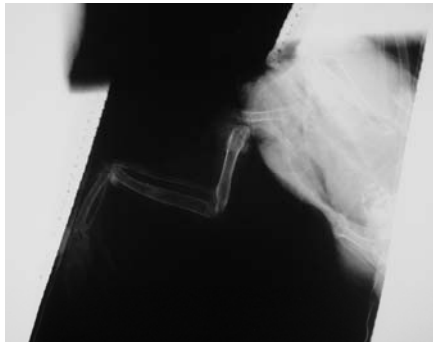


Figure 5- Lateral radiograph of the corrected wing, 3 months after surgery.

Clinical Relevance

The majority of the reports on developmental malformation are related to the wild birds and secondarily to poultry birds. The most frequently types involved the skeletal system and the other ones included ocular anomalies and abnormalities of the heart, gastrointestinal and urogenital system.¹ Several skeletal abnormalities have been reported in birds included anomaly of skull, hyoid apparatus, sternum and legs.¹

Congenital abnormalities of the wing have been rarely reported in the birds. Johnson described a four winged adult female Green-winged teal (*Nettion Carolinense*) that the supernumerary wings appeared as a miniature set springing from the underside of the primary wings at the region of the elbow.² An Ectopic wing has been reported by Osofsky et al, in an approximately 5-month-old black Vulture (*Coragyps atratus*) that was attached to the distal surface of the last few cervical vertebrae with its own pectoral girdle, the birds showed deformation of the spinal canal at the point of attachment as well.³ Barreiro et al. represented a tawny owl chick (*Strix aluco*) with multiple congenital malformation in the limbs as well as absence of most parts of the bones of the manus in both wings.⁴ Two case of unilateral micromelia were

described in wild juvenile little penguins (*Eudyptula minor*), the left wing was markedly reduced in size and had limited range of elbow and carpal movement. A severe reduction in size and distortion of the humerus and shortening and fusion of the ulna, radius, metacarpals and phalanges was seen radiographically.⁵

In many cases, abnormalities in skeletal elements are combined with other malformations¹, but in this case we could not find any other malformations. In association with literature review and our knowledge, this is the first report of such a rare condition in bird.

The cause of congenital malformation can be divided into 3 categories: Unknown, genetics and environmental. The cause of a majority of animal malformation is unknown.¹ The malformation depends on bird's nature, in poultry populations it is related mainly to inherited diseases whereas in wild population more complicated situation which involved spontaneous, genetics, toxicological and environmental factors must be considered.¹ The etiology of this anomaly is not clearly clarified, more likely it can be due to malposition in embryonic period because it was seen after birth but the others causes are unknown.

The cause of dysfunction of corrected wing was not clarified but the constant position of the wing, flexed carpal joint, in this anomaly can be considered. Reduced bone density was because of disuse osteoporosis and immobility of the carpal joint must be considered as a cause of ankylosis.

References

1. Pourlis AF, Developmental malformation in Avian Species. Manifestations of Unknown or Genetic Etiology-A Review. *Asian J Anim Vet Advances* 2011;6(5):401-415.
2. Johnson CE, A four winged wild duck. *Auk* 1915; 32:469-480.
3. Osofsky SA, Brown TP and Carrig CB, An ectopic wing in a wild black Vulture (*Coragyps atratus*). *Avian Dis* 1990;34(3):765-769.
4. Barreiro A, de Trocóniz PF, Vila M, López-Beceiro AM, et al. Congenital skeletal abnormalities in a Tawny owl chick (*Strix aluco*). *Avian Dis* 2003;47(3):774-776.
5. Raidal Sh, Shearer P, Cannel B, et al. Micromelia in little penguins (*Eudyptula minor*). *J Avian Med Surg* 2006;20:258-262.

چکیده

گزارش یک مورد ناهنجاری مادرزادی نادر بال در یک جوجه کبوتر

مسعود رجبیون*، حسین کاظمی مهرجردی، جمشید رزم‌یار

گروه علوم درمانگاهی، دانشکده دامپزشکی دانشگاه فردوسی مشهد

توصیف بیمار: یک عدد جوجه کبوتر ۲۰ روزه در حالیکه قسمت انتهایی بال چپ در داخل بدن قرار داشت به بخش بیماریهای پرندگان ارجاع داده شد.

یافته‌های بیماری: در معاینه بالینی، بال چپ پرنده حالت غیر طبیعی را نشان داد. سیستم اسکلتی، پاها و بال راست از نظر کلینیکی و رادیولوژی طبیعی بودند. تنها علامت بالینی قابل مشاهده بی‌حالی پرنده بود.

درمان و نتیجه: عمل جراحی برای بیرون آوردن قسمت انتهایی بال چپ با موفقیت به‌انجام رسید. بعد از عمل، پرنده علائم غیرطبیعی بروز نداد و در پیگیری انجام شده در ۳ و ۱۳ ماه بعد از جراحی، تنها مشکل کبوتر عدم عملکرد طبیعی بال اصلاح شده بود.

کاربرد بالینی: در بین آنومالی‌های پرندگان، متداولترین نوع، اختلالات اسکلتی است. در این مورد، علت دقیق چنین عارضه‌ای نامعلوم است؛ بنابه گزارش صاحب پرنده جوجه کبوتر از روز اول بعد از تولد این عارضه را داشته است، لذا جایگزینی ناصحیح در دوره جنینی ممکن است دلیل این اتفاق باشد. بر اساس دانش نویسندگان، این مورد اولین گزارش از این آنومالی نادر است.

کلمات کلیدی: کبوتر، ناهنجاری، بال.