

## Clinical Evaluation of Two Suture Pattern Techniques in Laparoscopic Gastrojejunostomy in Dog

Azin Tavakoli<sup>1</sup> DVM  
Jalal Bakhtiari\*<sup>1</sup> PhD  
Alireza Khalaj<sup>2</sup> PhD

<sup>1</sup>*Department of clinical Sciences, Faculty of Veterinary Medicine,  
Tehran University, Tehran, Iran*

<sup>2</sup>*Department of Surgery, Faculty of Medicine, University of Shahed, Tehran, Iran*

---

### Abstract

**Objectives-**To evaluate the clinical safety and feasibility of one layer suture pattern technique in gastrojejunostomy in dog in comparison to two layer suture pattern technique.

**Study Design-**Elective experimental study

**Animals-**Sixteen mix-breed healthy male and female dogs

**Methods-**Sixteen healthy male and female dogs were randomly divided in two groups. In the control group the two layer side to side laparoscopic gastrojejunostomy were performed. In the case group the one layer anastomosis between stomach and jejunum were done. Clinical parameters include body temperature, heart rate, respiratory rate, CRT, mean surgical time, blood loss, surgical complications, CBC, total protein, albumin and weight loss were evaluated.

**Results-**There were no significant differences between body temperature, heart rate, respiratory rate, CRT, CBC, total protein and albumin in both groups. There was significance difference between mean surgical time and blood loss and in two groups.

**Conclusion and Clinical Relevance-** Laparoscopic gastrojejunostomy with one layer closure technique based on clinical data revealed several advantages include feasibility, safety and less time consuming in comparison to two layer suture pattern technique.

**Key Words:** suture pattern, laparoscopy, gastrojejunostomy

---

\* **Corresponding author:**

Jalal Bakhtiari PhD

Department of clinical Sciences, Faculty of Veterinary Medicine, Tehran University, Tehran, Iran

E-mail address: [bakhtiar@ut.ac.ir](mailto:bakhtiar@ut.ac.ir)

## **Introduction**

Gastric out-flow tract disease is an overall term used to describe a variety of diseases which cause reduced or delayed gastric emptying. It may result from intraluminal masses or foreign material, mucosal or mural proliferative disease and compression of the outflow tract by masses or organs external to the stomach or secondary to malposition of the stomach. Definitive treatment is usually surgical and the aims of surgical management are to remove abnormal pyloric tissues, relieve pyloric obstruction and to establish normal gastric emptying and make a definitive diagnosis. Numerous surgical procedures have been described to relieve gastric outflow obstruction<sup>1, 2</sup>. Gastrointestinal anastomoses are one of the most common procedures performed on the intestinal tract procedures for management of gastric outflow obstruction. It includes gastroduodenostomy and gastrojejunostomy. Gastrojejunostomy (Billroth II) procedure is usually performed for resection of gastric adenocarcinoma. The currently technique is that after removal of the pylorus and the antrum, the gastric stump and duodenum are oversewn. Full thickness incisions are made in the stomach and jejunum and a side to side anastomosis is then fashioned<sup>2, 3</sup>.

Laparoscopic surgeries in gastrointestinal tract have several advantages. The most important advantages of the technique in gastrointestinal surgeries is reduction in the period of postoperative intestinal paralysis so that gastrointestinal function returns more rapidly to normal status following minimally invasive surgery<sup>3</sup>. It also involves a reduce immune response compared with open surgery<sup>4</sup>. This technique not only results reduced tissue desiccation and foreign body contamination but also fewer intra-abdominal adhesions<sup>5</sup>. It has gained wide clinical acceptance in surgical practice. There are some reports of performing laparoscopic gastrointestinal anastomosis which were summarized successively<sup>6, 7, 8</sup>. Surgeons agreed that the laparoscopic gastrointestinal anastomosis is superior to open technique because of faster recovery, less pain and better cosmetic<sup>9</sup>. The feasibility and safety of laparoscopic Billroth 2 gastrectomy in canine model was reported by Soper et al<sup>3</sup> in 1994.

The veterinary literature has multiple studies examining the effectiveness of various techniques for creating gastrointestinal anastomosis<sup>10</sup>. Gastrojejunostomy have been reported by use of several suture patterns including two-layer techniques, one-layer techniques and use of staplers. Two-layer techniques include simple continuous (both layers), simple interrupted (external layer), simple continuous (inner layer) and inverting pattern like lembert (external layer), simple continuous (inner layer). One-layer techniques using a full thickness simple interrupted, continuous inverting, simple continuous and continuous vertical mattress have also been reported<sup>11, 12, 13, 14, 15</sup>. Anastomotic leakage is an important complication of resection of the intestine which often followed by serious morbidity or death and if surgical techniques are sound the single layer anastomosis is efficient and safe<sup>16</sup>.

The objective of this present experimental study was to determine the suitability and feasibility of a single layer continuous technique for laparoscopic gastrointestinal anastomosis (gastrojejunostomy) in dog.

## **Materials and methods**

### *Animals*

Sixteen mix breed dogs, weighing 15-20 (mean 17.5 Kg), from both sexes were studied. Dogs were randomly divided in two groups (control and case), each group include eight dogs. They

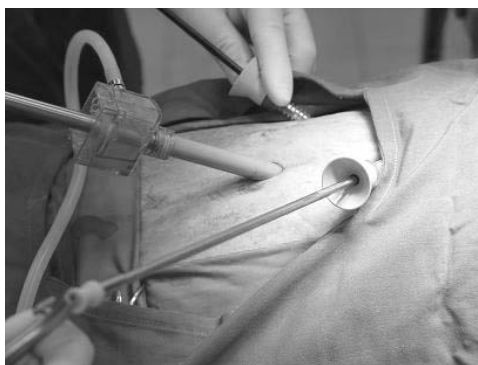
were considered healthy based on clinical examination, result of complete blood count and serum biochemical profile.

#### *Experimental design (surgical procedure)*

After induction of general anesthesia and endotracheal intubation, the abdomen was prepared and draped under aseptic laparoscopic surgery. Dogs were placed in dorsal position and 30 degree tilted to the horizon. The surgeon stood up between the patients' legs and the camera operator stood up on the left side of the patient. A Co2 pneumoperitoneum was established through the 10 mm laparoscopic trocar which used for introducing camera into the abdomen. An automatic high flow Co2 insufflator was connected to the laparoscopic cannula to a pressure of 14-18 mmHg. Before inserting trocars a 15 mm skin incision was first made at the umbilicus and then the abdomen approached through three portals bluntly. A 10 mm laparoscopic trocar and sheath were inserted into the peritoneal cavity from the umbilicus, through which a 0 degree video laparoscope that was connected to a light source was placed. Under direct vision two other laparoscope portals were placed through two 10 mm skin incisions for laparoscopic instrument insertion. One of them was located in the right side of abdomen, 4 cm caudal to the xiphoid and 12 cm from linea alba. The second one was placed in the left side of abdomen, 2 cm caudal to the xiphoid and 6 cm from linea alba. The laparoscopic procedures were recorded on videotapes. Before beginning the procedure, a 360 degree scan was performed for evaluation of any abdominal abnormalities. The antrum was identified and transversally closed by a 0 polyglycolic acid suture material in order to stop the gastric flow from the pylorus to the duodenum. Then the beginning loop of jejunum was identified and brought up to the diaphragmatic surface of the greater curvature of the stomach which was first decompressed by the esophagi gastric tube if needed. The 2 cm side to side hand sewn anastomosis between the greater curvature of the stomach and jejunum was performed. In the control group laparoscopic gastrojejunostomy were done by two layer side to side anastomosis technique. The seromuscular simple interrupted sutures were placed between the stomach wall and jejunum first, and then mucosa and submucosa were closed by the simple continuous suture pattern. In the case group the one layer anastomosis was performed by using the simple continuous pattern including all tissue structures. The suture material was 3-0 polyglycolic acid on a taper needle which formed to the ski-needle fashion before the procedure and all surgeries were performed by the same surgeon. The monopolar cautery was used for this procedure (Fig.1).

#### *Statistical analysis*

Statistical analysis and comparisons were determined using Student's T-Test and proportions were compared using the chi-square test. The *P* values less than 0.05 were considered statistically significant.



**Fig.1. Location of the videolaparoscope and laparoscopic forceps via three portals through abdomen.**

## **Results**

All animals of both groups with side to side laparoscopic gastrojejunostomy tolerated the operation.

### *Operative data*

The operative data are summarized in Table 1. Mean operative times in the case and control groups were 83 +/- 16 min and 124 +/- 24 min, respectively. The estimated blood losses 4.5 +/- 1.3 and 14 +/- 2.2 ml as well. Longer operative time was required for control group than for case ( $p=0.001$ ), also the blood loss in both procedures are comparable. Although the mean suture material consumption in the case group was more than that of the control group, there was no statistical significant in suture material consumption in two groups ( $p=0.79$ ).

### *Post-operative data*

All patients were recovered the anesthesia and began walking after the surgery and the time to resumption of oral intake was similar in both groups in the second day after the operation. There was no statistically significant difference among clinical data such as heart rate, respiratory rate, CRT and temperature between two groups ( $p>0.05$ ).

The stress leukograms were observed in both groups during the first days after the operation but there was no significant difference regarding hematological data such as PCV, WBC, and CBC in the two groups. Whereas the WBC counts in the first two days after operation was higher in the control group. Mean total protein and mean albumin concentration for the dogs in both groups are shown in table 1.

The Body weights were monitored weekly during the study and there was no statistically significant difference regarding weight loss between the two groups during the third postoperative week ( $P=0.566$ ).

### *Complications*

During the operation both group, we experienced some complications in totally 7 cases (Table 2). Minor laceration of spleen, liver and also the mesenteric vessels which resulted in

bleeding were seen in this study. There were no leakages or stenosis at the anastomotic site during the operation and period of the study.

**Table 1: Operative data**

<b>Parameter</b>	<b>Control</b>	<b>Case</b>
<b>Mean operative time (min)</b>	<b>124+/-24</b>	<b>83+/-16</b>
<b>Estimated blood loss (ml)</b>	<b>14+/-2.2</b>	<b>4.5+/-1.3</b>
<b>Suture material consumption (packages)</b>	<b>6.5+/-0.5</b>	<b>3.9+/-0.4</b>
<b>Days to oral intake</b>	<b>2</b>	<b>2</b>
<b>Mean protein concentration (g/dl)</b>	<b>6.8+/- 0.3</b>	<b>6.6+/- 0.2</b>
<b>Mean Albumin concentration (g/dl)</b>	<b>3.1+/- 0.4</b>	<b>2.9+/- 0.6</b>

**Table 2: Complications**

<b>Complication</b>	<b>Control</b>	<b>Case</b>
<b>Minor laceration of spleen</b>	<b>1</b>	<b>1</b>
<b>Minor laceration of liver</b>	<b>1</b>	
<b>Laceration of mesenteric vessel</b>	<b>2</b>	
<b>Skin emphysema</b>	<b>1</b>	<b>1</b>

## **Discussion**

Animals with gastric out flow obstruction usually need surgery for establishing normal gastric flow from stomach to the lower parts of intestine. There are very few reports of laparoscopic gastrojejunostomy in animals<sup>17</sup>. Although there are several reports of using different suture pattern techniques in laparoscopic gastrointestinal anastomosis, to the authors' knowledge the safety of one layer suture pattern for hand sewn laparoscopic gastrojejunostomy in dogs and human has not been determined. Since laparoscopy-assisted gastrectomy has been increasingly reported as the treatment of choice for early gastric cancer, prior to use this suture pattern technique in the human operating room, the need for proving the safety and efficacy of this technique in animal model was felt<sup>18</sup>.

The present study was the first experimental laparoscopic gastrojejunostomy in dog in Iran which has been set up by Small Animal Teaching Hospital in University of Tehran. The purposes of this clinical study were to compare the results of using one layer suture pattern technique with those of two layer technique in gastrojejunostomy in dogs. After successful surgical procedure all of the animals were observed and clinical data were issued. The experimental one layer continuous suture pattern used for the gastro intestinal anastomosis in this study appears to be safe in dogs as none of the dogs in the case group developed any clinical signs of post-operative leakage or peritonitis. We used the simple continuous suture pattern because it is faster and easier to apply. Boure in 2005 set up the experimental study of usage of laparoscopic one layer closure of bladder in calves. He stated that if the rupture of

the bladder occurred it would be at the incision line<sup>19</sup>. During the surgeries, the sutures were placed so that the distance between bites was around 5 mm and appositioning of the tissue structure was tried to be established well. No leakage happened at the anastomotic site.

There was no statistical significant in suture material consumption in two groups ( $p=0.79$ ). The mean surgical time and estimated blood loss were lesser in the case group than the control group. These are the advantages of the one layer suture pattern technique over the two layer technique.

There were no statistically differences between the heart rate, respiratory rate, CRT and temperature in both groups during the period of the study. However the recovery time in the control group was longer than the case group and they reached to the normal body temperature later but there were no significant difference between the temperature in both groups and the variations were in normal range ( $p>0.05$ ). The hematological data indicates no significant difference between the two groups just for WBC count in the first two days after operation. Shimizu in 2000 reported the lower WBC count in laparoscopic assisted distal gastrectomy group in compare with the open procedure in first post operative day of this may because of reduce immune response in laparoscopic surgeries<sup>3</sup>. The higher WBC count from the normal values may be due to more trauma and manipulation of viscera in the control group. Also longer anesthesia time which causes more stress is responsible for this higher WBC count. Anastomotic leakage is one of the most important complications of gastrointestinal tract surgery because of the high morbidity and mortality rates associated with it. Clinicopathologic abnormalities associated with anastomotic leakage in human and animals include hypoproteinemia, neutrophilia and low serum albumin concentration ( $<0.3$  g/dl)<sup>10</sup>. In our study no leakage occurred in all dogs and these data are within normal range without any significant differences in both groups. Beginning of oral consumption of food was early in all cases without any serious complication and defecation was normal after beginning of the oral intake. Reduction in the period of postoperative intestinal paralysis is one of the most valuable parameters which were emphasized by Shimizu in 2000<sup>3</sup>. The complications were all because of inserting of the trocar through the spleen and liver or tearing of the vessel by the tip of the laparoscopic instruments which resulted to minor laceration and bleeding. These are important events especially for the inexperienced surgeons which may happen during placement of the laparoscopic portals. There were no complications related to the surgical procedure or general anesthesia. In this study the one layer continuous technique for gastrojejunal anastomosis in dogs was used. There's a historic belief to close the hollow viscous in two layers to achieve adequate healing and watertight seal in contrast to recommend the one layer closure to achieve anatomic reconstruction and healing, minimum reduction in luminal diameter and a watertight seal<sup>19</sup>.

We concluded the laparoscopic gastrojejunostomy with one layer closure technique based on clinical data had several advantages include feasibility, safety and less time consuming.

## References

1. Gregory S. Gastric outflow tract disease. Lecture in small animal surgery, *Royal Vet College*, 2003;23-35.
2. Rasmussen L. Stomach. In Slatter D, ed. *Text book of small animal surgery*. 3<sup>rd</sup> ed. Philadelphia: Saunders Co, 2002;618-634.
3. Shmizu S, Uchiyama A, Mizumoto K, et al. Laparoscopic assisted distal gastrectomy for early gastric cancer. *Surg Endosc* 2000;14:27-31.

4. Hiki N, Shimizu N, Yamaguchi H, et al. Manipulation of the small intestine as a cause of the increased inflammatory response after open compared with laparoscopic surgery. *Br J Surg* 2006;93:195-204.
5. Freeman LJ, Introduction to veterinary laparoscopy. In Freeman LJ, ed. *Veterinary endosurgery*. 1<sup>st</sup> ed. Missouri: Mosby Co, 1999;14-15.
6. Gonzalez R, Lin E, Venkatesh KR, et al. Gastrojejunostomy during laparoscopic gastric bypass: analysis of three techniques. *Arch Surgery* 2003;138:181-184
7. Kitano S, Yasunori I, Moriyama M, Sugimachi K. Laparoscope-assisted Billroth I gastrectomy. *Surg Laparosc Endosc* 1994;4:146-148.
8. Nagai Y, Tanimura H, Takifuji K, et al. Laparoscope-assisted Billroth I gastrectomy. *Surg Laparosc Endosc* 1995;5:281-287.
9. Goh PM, Alponat A, Mak K, et al. Early international results of laparoscopic gastrectomies. *Surg Endosc* 1997;11:650-652.
10. Christopher Ralph S, Jessen R, Lipowitz J. Risk factors for leakage following intestinal anastomosis in dogs and cats:115 cases. *JAVMA* 2003;223:73-77.
11. Brodsky JT, Dadian N. Single layer continuous suture for gastrojejunostomy. *Am J Surg* 1997;63:395-399.
12. Burch JM, Franciose RJ, Moore EE, et al. Single continuous versus two-layer interrupted intestinal anastomosis: a prospective randomized trail. *Ann Surg* 2000; 23:832-837.
13. Hori S, Ochiai T, Gunji Y, et al. A prospective randomized trial of hand -sutured versus mechanically stapled anastomoses for gastroduodenostomy after distal gastrectomy. *Gastric Cancer J* 2004;7:24-30.
14. Moriura S, Kobayashi I, Ishiguro S, et al. Continuous mattress suture for all hand-sewn anastomoses of the gastrointestinal tract. *Am J Surg* 2002;184:446-448.
15. Vagholkar KR. Healing and anastomosis in the gastrointestinal tract: Retrospective study of 35 cases. *Bhj J* 2001;4302:269-279.
16. Matheson NA, Irving AD. Single layer anastomosis in the gastrointestinal tract. *Surg Gynecol Obstet*.1976;143:619-624.
17. Soper NJ, Brunt LM, Brewer JD, Meininger TA. Laparoscopic Billroth II gastrectomy in the canine model. *Surg Endosc* 1994;8:1395-1398.
18. Mochiki E, Nakabayashi T, Kamimura H, et al. Gastrointestinal recovery and outcome after laparoscopy-assisted versus conventional open distal gastrectomy for early gastric cancer. *World J of Surgery* 2002;26:1145-1149.
19. Boure LP, Kerr CL, Pearce SG, Runciman R, Landsdowne J, Caswell JL. Comparison of two laparoscopic suture patterns for repair of experimentally ruptured urinary bladders in normal neonatal calves. *Vet surg J* 2005;34:47-54.

## ارزیابی بالینی دو الگوی مختلف بخیه در گاستروژژنوستومی به روش لاپاروسکوپی در سگ

دکتر آذین توکلی<sup>۱</sup>، دکتر جلال بختیاری<sup>۱</sup>، دکتر علیرضا خلیج<sup>۲</sup>

<sup>۱</sup> گروه آموزشی علوم درمانگاهی دانشکده دامپزشکی دانشگاه تهران، تهران، ایران

<sup>۲</sup> گروه آموزشی علوم درمانگاهی دانشکده پزشکی دانشگاه شاهد، تهران، ایران

**هدف:** ارزیابی سهولت و کفایت الگوی بخیه یک لایه در آناستوموز ژژنوم به معده در مقایسه با دو لایه به روش لاپاروسکوپی در سگ  
**طرح:** مطالعه تجربی انتخابی

**حیوانات:** شانزده قلاده سگ از نژاد مخلوط و از دو جنس نر و ماده

**روش کار:** در این مطالعه شانزده قلاده سگ از نژاد مخلوط و از دو جنس نر و ماده به طور تصادفی به دو گروه مساوی تقسیم شدند. در گروه شاهد آناستوموز پهلوی به پهلوی ژژنوم به معده به روش دست دوز و دو لایه صورت گرفت و در گروه آزمایش آناستوموز به صورت یک لایه با الگوی بخیه ساده سرتاسری انجام شد. پارامترهای کلینیکی اندازه گیری شده شامل درجه حرارت بدن، تعداد ضربان قلب و تنفس در دقیقه، پر شدن مجدد مویرگی، میانگین مدت زمان به طول انجامیدن جراحی، میزان از دست رفتن خون حین عمل، عوارض جراحی، شمارش کلی سلول های خونی، پروتئین تام سرم، آلبومین و کاهش وزن بودند.

**نتایج:** از لحاظ آماری بین میانگین درجه حرارت بدن، تعداد ضربان قلب و تنفس در دقیقه، پر شدن مجدد مویرگی شمارش کلی سلول های خونی، پروتئین تام سرم و آلبومین در دو گروه شاهد و آزمایش اختلاف معنی داری وجود نداشت. در حالی که بین میانگین مدت زمان به طول انجامیدن جراحی و از دست رفتن خون حین عمل بین دو گروه اختلاف معنی دار وجود داشت.

**نتیجه گیری:** بر اساس نتایج حاصل از آنالیز پارامترهای کلینیکی، آناستوموز ژژنوم به معده با یک لایه بخیه به روش لاپاروسکوپی علاوه بر اطمینان دارای مزایای زیادی از جمله قابلیت انجام، سهولت و صرفه جویی در زمان نسبت به روش دو لایه می باشد.

**کلید واژگان:** الگوی بخیه، گاستروژژنوستومی، لاپاروسکوپی