

Clinical Report

Cutaneous Fibroma and its Surgical Excision in a Horse

Alireza Raayat Jahromi^{1*}, DVM
Abutorab Tabatabaei¹, DVSc
Azizollah Khodakaram Tafti², DVSc
Samira Mehrshad³
Razi Ghalebi¹, DVM

¹ Department of Clinical Sciences ² Department of Pathobiology and
³ Undergraduate Student of Veterinary Medicine, Faculty of Veterinary Medicine,
Shiraz University, Shiraz, Iran.

Abstract

Case Description- An eight-year-old, light brown and crossbred stallion in a horse-racing club had two gray skin masses on his left thigh and thoracic inlet with a slow growth since two years ago. The masses were 5×7 cm in size, irregular shaped with some convex parts. Surface bleeding had been reported occasionally. CBC and WBC were within normal values. General clinical examination of the animal revealed no problem.

Treatment and Outcome- Under general anesthesia (premedication, induction and maintenance by xylazine and ketamine) two neoplastic masses were excised completely. The lesions were restricted to skin with no subcutaneous tissue involvement. Histopathologic results confirmed cutaneous fibroma based on numerous fibroblasts and collagen fibers. There were no recurrence or any other complications in post-operative monitoring for six months.

Clinical Relevance- Treatment of cutaneous fibroma is complete by surgical excision in ablating the tumor masses and preventing re-growth.

Key Words- Cutaneous Fibroma, Surgical Excision, Horse.

* Corresponding author:

A Raayat Jahromi, DVM

Department of Clinical Sciences, Faculty of Veterinary Medicine, Shiraz University, Shiraz, Iran.

E-mail address : Raayat@shirazu.ac.ir

Case Description

An 8-years-old, light brown and crossbred stallion presented with two firm and gray-colored skin masses on his left thigh and thoracic inlet with a slow growth since two years ago. They were irregular in shaped with some convex parts, measuring $5.0 \times 7.0 \times 12.0$ cm (Fig. 1). Surface bleeding had been reported occasionally. The masses were palpated quite intradermal with no subcutaneous tissue involvement. The general clinical examination of the animal, including heart rate, respiratory rate and rectal temperature revealed no problem. CBC and WBC count were normal.



Figure 1. Two neoplastic masses (arrows)

Treatment and Outcome

After a brief sedation by xylazine, a small biopsy was taken from the mass. Histopathologic study confirmed cutaneous fibroma based on numerous fibroblasts and collagen fibers. After surgical preparation, under general anesthesia (premedication, induction and maintenance by xylazine (20 mg/ml, Alfasan, Woerden, Holland), (0.5 mg/kg, IV) and ketamine (100 mg/ml, Aesculaap, Boxtel, Holland), (2 mg/kg, IV) two neoplastic masses were excised completely.

Discussion

Mesenchymal tumors of the skin and soft tissues comprise a wide range of entities, some of which are of uncertain classification. Fibromas are benign neoplasms of fibrocytes with abundant collagenous stroma which has a rare occurrence in large animals. They often occur in adults, sex and species have no effect on its prevalence. The majority of tumors are round to oval intradermal or subcutaneous masses. They are firm, rubbery, and gray/white on cut surface.¹ Published figures from veterinary schools indicate that tumors may account for about 1 to 3 percent of surgical cases. Amongst the common and important tumors dealt with, the most prominent are "equine sarcoid".²

This benign tumor is well circumscribed but unencapsulated. It is composed of mature fibrocytes producing abundant collagen (Fig.s 2 and 3). The collagenous fibers are repetitive and are usually arranged in interwoven fascicles, more rarely in whorls. The neoplastic fibrocytes are uniform, with oval normochromatic nuclei and an indistinct cytoplasm that blends into the extracellular collagenous stroma. Fibromas are slow growing and complete excision is curative.

There is several reports of its occurrence in different parts of body and in various types in horses; guttural pouch fibroma,³ orbital fibroma,⁴ mandibular ossifying fibroma,⁵ ossifying fibroma in the nasal cavity and paranasal sinus,⁶ bilateral nonossifying fibromas in the proximal tibia,⁷ nasal and paranasal sinus fibroma,⁸ and fibroma in the abdomen of a horse.⁹

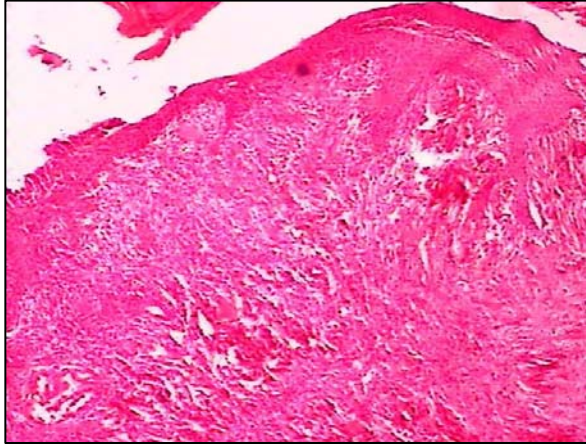


Figure 2. Hyperplasia of the epidermis and connective tissue cells (40×,H&E).

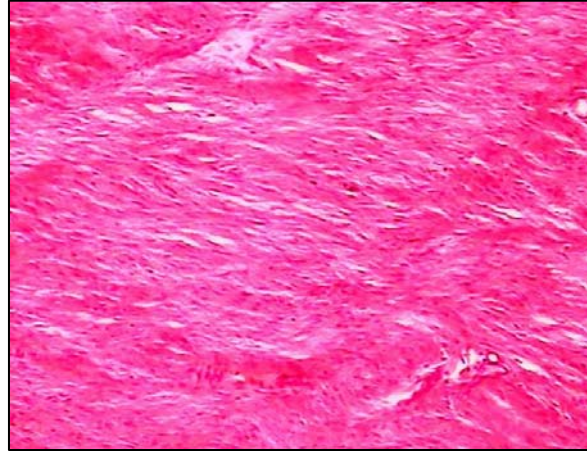


Figure 3. Mature fibrocytes with abundant collagenous stroma (100×, H&E).

Ossifying fibromas are uncommon tumors that frequently recur if incompletely excised. Adjunctive radiotherapy may delay or prevent tumor recurrence in affected horses. Except surgical excision of the tumor and based on its recurrence, other treatments have been used such as use of carbon dioxide laser,¹⁰ use of cisplatin-containing biodegradable beads,¹¹ and radiotherapy such as using radioactive gold₁₉₈ grains.¹² Incomplete surgical excision has been resulted in local recurrence, so that it has had 3 times recurrence which adjunctive radiotherapy consisting of 3,000 cGy of cobalt radiation and 4,000 cGy of photon beam radiation from a linear accelerator have been administered in second and third time, respectively.¹³

In this case, surgical treatment was successful in ablating the tumor masses and preventing re-growth with no complications in post-operative monitoring for six months. The cosmetic outcome of the operation was also satisfactory.

References

1. Meuten DJ. *Tumors in domestic animals*. 4th ed. Iowa: Iowa State Press, 2002; 84-86.
2. Cotchin E. A general survey of tumours in the horse. *Equine Vet J* 1977;9: 16-21.
3. Merriam JG. Guttural pouch fibroma in a mare. *J Am Vet Med Assoc* 1972;161: 487-489.
4. Colitz CM, Gilger BC, Davidson CP, et al. Orbital fibroma in a horse. *Vet Ophthalmol* 2000;3: 213-216.
5. Kidd JA, Bradshaw J. Bilateral nonossifying fibromas in the proximal tibiae of a yearling Thoroughbred filly. *Equine Vet J* 2002;34: 317-320.
6. Puff C, Ohnesorge B, Wagels R, et al. An unusual mucinous osteoma with features of an ossifying fibroma in the nasal cavity of a horse. *J Comp Pathol* 2006;135: 52-55.
7. Morse CC, Saik JE, Richardson DW, et al. Equine juvenile mandibular ossifying fibroma. *Vet Pathol* 1988;25: 415-421.
8. Dixon PM, Head KW. Equine nasal and paranasal sinus tumours. Part 2: a contribution of 28 case reports. *Vet J* 1999;157: 279-294.
9. Wilson TD, Sykes GP. Fibroma in the abdomen of a horse. *Vet Rec* 1981;108: 334.

10. McCauley CT, Hawkins JF, Adams SB, et al. Use of a carbon dioxide laser for surgical management of cutaneous masses in horses: 32 cases (1993-2000). *J Am Vet Med Assoc* 2002;220: 1192-1197.
11. Hewes CA, Sullins KE. Use of cisplatin-containing biodegradable beads for treatment of cutaneous neoplasia in equidae: 59 cases (2000-2004). *J Am Vet Med Assoc* 2006;229: 1617-1622.
12. Wyn-Jones G. Treatment of periocular tumours of horses using radioactive gold198 grains. *Equine Vet J* 1979;11: 3-10.
13. Orsini JA, Baird DK, Ruggles AJ. Radiotherapy of a recurrent ossifying fibroma in the paranasal sinuses of a horse. *J Am Vet Med Assoc* 2004;224: 1483-1486,1454.

فیبرومای پوستی و درمان جراحی آن در اسب

علیرضا رعایت جهرمی^۱، ابوتراب طباطبایی^۱، عزیزالله خداکرم تفتی^۲، سمیرا مهرشاد^۳، رضی غالبی^۱

^۱ گروه علوم درمانگاهی، ^۲ گروه پاتوبیولوژی و ^۳ دانشجوی دکترای عمومی دامپزشکی، دانشکده دامپزشکی دانشگاه شیراز، شیراز، ایران.

توصیف بیمار- در نریان کورنگ هشت ساله از نژاد دوخون که به منظور پرش در باشگاه سوارکاری نگهداری می شد، دو توده خاکستری رنگ پوستی دیده شد که در نواحی ران چپ و مدخل قفسه سینه از دو سال قبل شروع به رشد کرده و به ابعاد ۷×۵ سانتیمتر رسیده بود؛ شکلی نامنظم با برآمدگیهای گنبدی شکل داشت و هر از گاهی خونریزی از سطح آن دیده می شد. نتایج آزمایشات خونی و وضعیت عمومی حیوان در معاینات بالینی کاملا نرمال بود.

درمان و نتیجه آن- نریان فوق با آرامبخشی و القای زایلازین-کتامین تحت بیهوشی عمومی قرار گرفت و پس از آماده سازی جراحی موضع، توده های مذکور از هر دو ناحیه کاملا برداشته و پوست نواحی فوق دوخته شد. درگیری این توده ها صرفا در پوست بود و بافت های زیرین را درگیر نکرده بود. گزارش هیستوپاتولوژی از نمونه های فوق با تاکید بر حضور فراوان فیبروبلاست ها و الیاف کلاژن، فیبرومای پوستی اسب را تایید کرد.

کاربرد بالینی- درمان فیبرومای پوستی با برداشت جراحی کامل آن امکان پذیر است.
کلید واژگان- فیبرومای پوستی، برداشت جراحی، اسب.

