

Ultrasonographic Measurement of the Anterior and Posterior Lens Capsules of the Eyes and its Comparison with a Field Study in Normal Rabbit

Varia Tohidi^{1*}, DVSc
Abbas Veshkini¹, DVSc
Mohammad Razi Esfahani², DVM
Niloufar Piri², DVM
Alireza Vajhi³, DVSc
Mohammad Nasrollahzadeh Masouleh¹, DVSc
Majid Masoudifard³, DVSc
Farrokh Reza Kabir³, DVSc

¹ Department of Clinical Sciences, Faculty of Specialized Veterinary Sciences, Science and Research branch, Islamic Azad University, Tehran, Iran,

² Department of Ophthalmology, School of Medicine, University of Tehran, Tehran, Iran,

³ Department of Clinical Sciences, Faculty of Veterinary Medicine, University of Tehran, Tehran, Iran.

Abstract

Objective- To find normal value of thickness of the lens capsules in domesticated rabbits by ultrasonography.

Design- experimental in vivo study and clinical trial.

Animals- Twelve matured and immature domesticated rabbit.

Procedures- The eyes of 12 non anaesthetized domesticated rabbits were sonographed using a linear 6-12 MHz high frequency transducer. The thickness of anterior and posterior capsule of the lens was measured in millimeter (mm). All measurements were done only by one experienced radiologist and confirmed by another radiologist. Mean and standard errors were calculated statistically by spss statistical software.

Results were compared with ultrasonography of the eye of 75 rabbits referred to different small animal clinic and sonographed by a radiologist.

Results- The measurement of the thickness of anterior and posterior capsule of both eyes was 0.3979 ± 0.03255 . The mean value and standard deviation of 75 clinically studied rabbits was 0.3933 ± 0.02552 .

Conclusion and Clinical Relevance- The thickness of lens capsule can be measured by ultrasonography and this value can be used for diagnosis of production of capsular cataract either experimentally or acquired in rabbit. There was no significant difference

* Corresponding author:

V. Tohidi, PhD

Department of Clinical Sciences, Faculty of Specialized Veterinary Sciences, Science and Research branch, Islamic Azad University, Tehran, Iran.

E-mail address: vrya.touhidi@kiau.ac.ir

between thickness of anterior and posterior capsules of both eyes and has no relation to sex, weight and age of animal.

Key Words- Rabbit, Eye, Lens, Ultrasonography.

Introduction

The lens consists of the capsule, anterior epithelium, and lens fibers. It is divided into two general regions, the cortex (outer areas near the capsule) and the nucleus (central area).¹

Ultrasonography is one of methods to evaluate the eye and orbit in human and animals. High frequency transducer is essential when the eye is evaluated by ultrasonography. Frequency more than 7.5 MHz is needed for ultrasonography of the eye. Ultrasonography units that are being used for heart or abdomen can be used for ultrasonography of the eye if transducer with more than 7.5 MHz is available. Either linear or sector transducer can be used for ultrasonography of the eye. Stand off is not necessary for ultrasonography of the eye unless the anterior part of the eye like cornea is examined.^{2,3,4}

Two dimensional, Doppler and three dimensional ultrasonography of the eye is reported in rabbit and different structure of the eye like lens diameter is measured.^{5,6,7} There is no report of measurement of the capsules of the lens by ultrasonography. It is believed that changes in thickness of the lens capsule are occurred in ocular disease like early production of the capsular and cortical cataract.

The aim of this study was to define the normal value of the lens capsule of the eye.

Materials and Methods

Twelve matured and immature (9mature, 3immature) domesticated rabbit weighing between 600 to 1500 gram of both sexes (6male, 6female) were collected and kept for one week prior to experiment For being clinically healthy. Radiographs were taken of skeletal system of all rabbits for determination of statue of the growth plate. All eyes were examined by ophthalmoscope and slit lamp biomicroscope on non-anaesthetized rabbit (fig 1). Only atropine was applied half an hour before examination for production of mydriasis (fig 2).

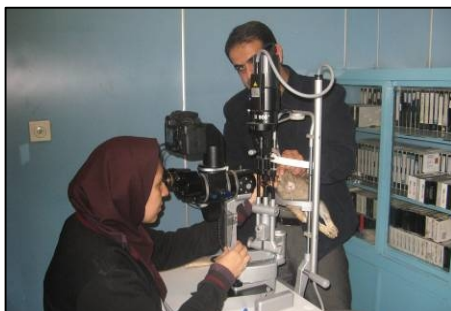

Figure 1. slit lamp biomicroscope examination of the rabbit eye

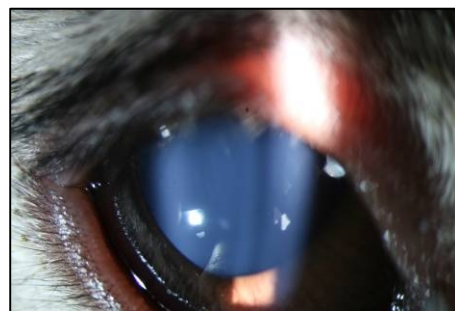


Figure 2. normal rabbit eye viewed by slit lamp biomicroscope

Transcorneal Ultrasonography was performed without stand off on non-anaesthetized rabbits. Ultrasonography was done by a 6-12 MHz linear transducer from titan ultrasonographic units, Sonosite Company. No local anesthesia was used. Measurements were calculated by only one expert person when true sagittal picture was obtained (fig 3).

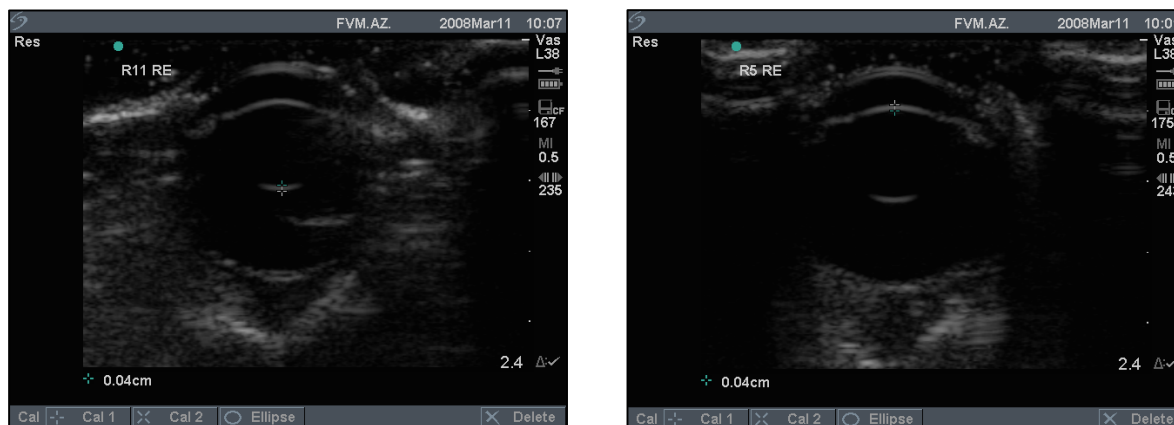


Figure 3. normal sonogram of the rabbit eye.

The results of this study were compared with results of ultrasonography of 75 rabbits that has been done in different veterinary clinics and different ultrasonographic units and radiologists (table 1)

Results

The measurements of the anterior and posterior capsule of the lens of both eyes were given in table 1.

Table 1. mean and standard deviation of anterior and posterior lens capsule thickness.

| | No. | MIN. | MAX. | Mean | SD. |
|--|-----|------|------|--------|---------|
| Thickness of Right Anterior Capsule | 12 | 0.3 | 0.4 | 0.3917 | 0.02887 |
| Thickness of Left Anterior Capsule | 12 | 0.3 | 0.4 | 0.3917 | 0.02887 |
| Thickness of Right Posterior Capsule | 12 | 0.3 | 0.5 | 0.4083 | 0.05149 |
| Thickness of Left Posterior Capsule | 12 | 0.4 | 0.4 | 0.4 | 0 |
| Thickness of Right & Left Anterior Capsule | 24 | 0.3 | 0.5 | 0.4 | 0.04170 |
| Thickness of Right & Left Posterior Capsule | 24 | 0.3 | 0.4 | 0.3958 | 0.02041 |
| Thickness of Right & Left Anterior & Posterior Capsule | 48 | 0.3 | 0.5 | 0.3979 | 0.03255 |
| Thickness of Anterior & Posterior Capsule | 72 | 0.3 | 0.5 | 0.3933 | 0.02552 |

It can be learned from the table that the thickness of the anterior and posterior capsule of the lens of the both eye is less than 0.41 mm in all cases.

There was no significant difference between the thickness of the anterior and posterior of the lens

There was no significant difference between the thickness of the anterior and posterior capsule of the lens of left and right eye.

No significant difference was found in thickness of the anterior and posterior capsule of the lens in relation to sex, age and weight of the rabbits.

The measurements made in field study showed that the thickness of the anterior and posterior capsule of the lens was less than 0.41 in all rabbits.

Discussion

High frequency two dimensional ultrasonography is being used routinely for eye study in human and animal.^{1,2,3,5,8} Special ultrasonography unit called “ultrasound biomicroscope” uses for laboratory animals such as mice and rabbits. Ultrasound biomicroscope has this ability to utilize very high frequency like 75MHz. Ultrasound biomicroscope uses for evaluation of the superficial structures like cornea in human and animal.⁴ General purpose ultrasound unit with frequency more than 12 MHz uses for eye and its lens examination in human and animal these days. Ultrasonography of the eye has been described in detail in animals and normal size of the different structure of the eye has also been reported.

Different structure of the normal eye has been measured by B-mode and A-mode ultrasonography. There was no significant difference between these two methods of eye measurements and because there is not usually A-mode ultrasonography in general purpose ultrasound machine, therefore measurement can also be made by B-mode ultrasonography.^{2,9,10,11} Increased echogenicity of the anterior and posterior capsule of the lens is reported in relation to cataract.^{4,11,12} but the thickness of the capsule has not been reported on the bases of the author's knowledge.

Other methods unlike ultrasonography and biomicroscope such as slit lamp biomicroscope uses for investigation of normal eyes and diagnosis of abnormalities like cataract.

Cataract can be diagnosed very easily by different means when it is in developed stage but early cataract diagnosis especially when dealing with cortical and capsular cataract is very essential.

There is no way by mean of ultrasonography or other diagnostic methods to diagnose early cortical and capsular cataract so far.

It is reported by histopathology, early changes in cortical and capsular cataract is increase in thickness of the capsule of the lens and up to this time there was no thought to measure possibly this increase in thickness of the capsule of the lens even by ultrasonography.

This ignorance may be due to this thought that, the thickness of the capsule doesn't have any importance in diagnosis of cataract and again this ignorance may be due to, that ultrasonography is used for diagnosis such as advanced cataract and lens luxation but increase in thickness of capsule occurs in early capsular and cortical cataract. In histopathologic studies it is reported that cortical cataract is produced by migration of sub capsular epithelial cells to the posterior capsule with retained nuclei, swollen presumptive of the sub epithelial fibers. These evidences is suggestive of degeneration of sub capsular fibers that is called “Bladder cells” and increase thickness of the posterior capsule of the lens. It is reported by histology and electron- microscope examination that occurrence of metaplasia in anterior and posterior capsule may lead to increase thickness of the capsules.¹³ Authors of this paper proved the gradual increase in thickness of anterior and posterior capsule occur in experimentally induced rapid cataract by subcutaneous injection of sodium selenite so normal thickness of anterior and posterior capsule of the lens is necessary for diagnosis of early capsular cataract in rabbit and other animals.

It is suggested that A-mode and ultrasound biomicroscope study on the thickness of the anterior and posterior capsule of lens may show the accuracy of the given values in this study.

References

1. Maggs D.J, Miller P.E, Orfi R, Lens. In; Maggs D.J. Slatter's fundamentals of Veterinary Ophthalmology 4th ed. Philadelphia: WB Saunders Co, 2008; 258- 276.

2. Nautrup PC, Heider HJ, Eggers S. Eye. In: Natroup PC, Tobias R, An Atlas and Textbook of Diagnostic Ultrasonography of the Dog and Cat. 2nd ed. London: Manson Publishing, 2001; 92-108.
3. Reef VB. Eye Ultrasonographic. In: Reef VB. Equine diagnostic ultrasound. Philadelphia: WB Saunders Co, 1998; 483-484.
4. Vander wordt, A. Wilkie, DA. Myer, CW. Ultrasonographic abnormalities in the eyes of the dog with cataract. J Am vet Med Assoc 1993; 202:838-841.
5. Alejandro B, Two-Dimensional and duplex doppler ultrasonography of the eye in normal rabbits, World small animal veterinary association symposium, 2005.
6. Forte R, Cennamo, G, Breve MA. Three- Dimensional Ultrasound Ophthalmic Pathologies. J Ophthalmol. 2009; 223:183-187.
7. Kametaka S, Kasahara T, Ueo M, et al. A novel high resolution in vivo digital imaging system for the evaluation of experimental cataract in diabetic rats. pharmacol sci; 2008; 106 (1):144-51.
8. Silverman R.H., Cannata J., Shung K.K., et al, 75 MHz ultrasound biomicroscopy of anterior segment of eye, J Ultrasonic Imaging, 2006; 28:1-10.
9. Kotecha S, Bhatia P, Rout PG. Diagnostic ultrasound in the head and neck region. Dent Update. 2008; 35(8):529-30, 533-4.
10. Li EY, Mohamed S, Leung CK. Agreement among 3 methods to measure corneal thickness: ultrasound pachymetry, Orbscan II, and Visante anterior segment optical coherence tomography. Absorbed: J Am Orthoptic. 2007; 114(10):1842-7.
11. Nyland TG, Mattoon JS, Herrgesell EJ. Eye. In: Nyland TG, Mattoon JS, eds. Small animal diagnostic ultrasound. 2nd ed. Philadelphia: WB Saunders Co, 2002; 305-324.
12. Oriji, Sasa, Y. Komiya, M. Yoshikait, T. Two Dimensional ultrasonography of the lens in diagnosis of canine cataract and nuclear sclerosis. J Jap Vet Med Assoc. 1996;49:175-179.
13. Chalam K.V, Tripathi R.C, Vinay A. et al. Cataract in Kniest Dysplasia: Clinicopathologic Correlation. J Arch of ophthalmol; 2004; 122:913-915.

اندازه‌گیری شاخص‌های اولتراسونوگرافی دو بعدی کپسول قدامی و خلفی عدسی چشم و مقایسه نتایج آن با یک مطالعه میدانی در خرگوش

وریا توحیدی¹، عباس وشکینی¹، محمد ریاضی اصفهانی²، نیلوفر پیری²، علیرضا وجهی³، محمد نصراله‌زاده ماسوله¹، مجید مسعودی فرد³، فرخ رضا کبیر³

¹ گروه علوم درمانگاهی، دانشکده علوم تخصصی دامپزشکی، دانشگاه آزاد اسلامی واحد علوم و تحقیقات، تهران، ایران،
² گروه چشم پزشکی، دانشکده پزشکی دانشگاه تهران، تهران، ایران،
³ گروه علوم درمانگاهی، دانشکده دامپزشکی دانشگاه تهران، تهران، ایران.

هدف- پیدا کردن اندازه طبیعی ضخامت کپسول عدسی در خرگوش اهلی بوسیله اولتراسونوگرافی.

طرح مطالعه- مطالعه تجربی در شریط زنده و مطالعه میدانی.

حیوانات- 12 سر خرگوش بالغ و نابالغ اهلی.

روش کار- چشم‌های دوازده سر خرگوش بدون بیهوشی با ترانس دیسر خطی فرکانس بالا سونوگرافی شد و اندازه ضخامت کپسول قدامی و خلفی عدسی بر حسب میلی‌متر اندازه‌گیری گردید.

تمام اندازه‌گیری‌ها بوسیله یک نفر متخصص رادیولوژی انجام گرفت و نتایج بدست آمده توسط فرد رادیولوژیست دیگری تأیید گردید. میانگین و انحراف معیار توسط نرم افزار SPSS بررسی آماری شدند.

نتایج- اندازه ضخامت کپسول قدامی و خلفی دو هر دو چشم $0/03255 \pm 0/3979$ بود. اندازه میانگین و انحراف معیار 75 سر خرگوش در یک مطالعه کلینیکی $0/02552 \pm 0/3933$ بود.

نتیجه‌گیری و کاربرد بالینی- ضخامت کپسول قدامی و خلفی را به وسیله اولتراسونوگرافی می‌توان اندازه گرفت و این معیار می‌تواند شاخصی برای تشخیص ایجاد کاتاراکت کپسولی چه به صورت اکتسابی و چه به صورت تجربی در خرگوش باشد. اختلاف معنی‌داری بین ضخامت کپسول خلفی و قدامی عدسی دو چشم وجود نداشت و این اندازه ارتباطی با جنس و وزن و سن حیوان وجود نداشت.

کلید واژگان- خرگوش، چشم، عدسی، اولتراسونوگرافی.