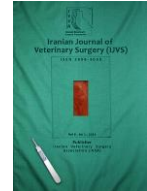



Iranian Veterinary Surgery Association

Iranian Journal of Veterinary Surgery

Journal homepage: www.ivsajournals.com

Original Article

The Effects of Honey, Curcumin, Ginger, *Nigella sativa* and Their Mixture on the Radial Bone Defect Repair in Rat Model: Histological and Biomechanical Study

Mohammad Mahmoudi-Fard*, Seifollah Dehghani-Nazhvani, Behrouz Nikahval

Department of Surgery, School of Veterinary Medicine, Shiraz University, Shiraz, Iran.

ARTICLE INFO	ABSTRACT
<p><i>Article History:</i></p> <p>Received 25 February 2022 Revised 15 May 2022 Accepted 28 May 2022 Online 30 May 2022</p> <hr/> <p><i>Keywords:</i></p> <p>Bone healing Honey Curcumin Ginger <i>Nigella Sativa</i> Rats</p>	<p>Honey, curcumin, ginger, and <i>Nigella sativa</i> are known for their antioxidant, immune stimulation properties, and wound healing effects. This study was conducted to determine the effect of these compounds and their mixture on the bone healing of the radial bone defect model in rats. One hundred and ten radial bone defects in 55 healthy male rats were randomly divided into 11 groups (10 rats per group). Groups 1-5 received honey, curcumin, ginger, and <i>Nigella sativa</i> orally by gavage, and groups 6-10 received the same materials locally by rubbing them on the sutured skin. The bone repair effects of these materials were evaluated by histopathology and biomechanical examinations. Using honey, curcumin, ginger, and <i>Nigella sativa</i> exhibited a beneficial effect to promote bone healing in this study. The biomechanical and histopathologic evaluations showed that the honey (oral), the mixture of honey and curcumin (oral), and the mixture of honey and <i>Nigella sativa</i> (topical) groups exhibited significantly better results on the 52nd postoperative day compared to the other groups.</p>

Introduction

Fracture healing is a complex, well-orchestrated, regenerative process initiated in response to injury, resulting in optimal skeletal repair and restoration of skeletal function. During the repair process, the pathway of normal embryonic development is recapitulated with the coordinated participation of several cell types.¹ All four components involved in the

injury site, including the cortex, periosteal tissue, bone marrow, and the external soft tissues, contribute in the healing process at different extent, depending on multiple parameters present at the injured tissue such as growth factors, hormones, nutrients, pH, oxygen tension, the electrical environment, and the mechanical stability that has been obtained.^{2,3}

Unrefined honey has anti-inflammatory, anti-bacterial and anti-oxidant properties.⁴ The antibacterial

*Correspondence to: Mohammad Mahmoudi-Fard, Department of Veterinary Surgery, School of Veterinary Medicine, Shiraz University, Shiraz, Iran, Email: mmfard1366@yahoo.com

www.ivsajournals.com© Iranian Journal of Veterinary Surgery, 2022

<https://doi.org/10.30500/ivsa.2021.262771.1238>



This work is licensed under the Creative Commons Attribution-Non Commercial 4.0 International License. To view a copy of this license, visit <http://creativecommons.org/licenses/by-nc/4.0/>.

action is due to its acidity, hydrogen peroxide content, osmotic effects, nutritional and antioxidant content, stimulation of immunity, and unidentified compounds.⁵ Based on the positive effects on bone density, honey has the potential to be used as an alternative treatment for postmenopausal osteoporosis due to its anti-oxidative and anti-inflammatory properties against bone loss.⁶ Ginger has starring potential for treating a number of ailments including degenerative disorders (arthritis and rheumatism), digestive health (indigestion, constipation, and ulcer), cardiovascular disorders (atherosclerosis and hypertension), vomiting, diabetes mellitus, and cancer. It also has anti-inflammatory and anti-oxidative properties for controlling the process of aging,^{7,8} and has been reported to promote angiogenesis.⁹ Curcumin has also been shown to possess anti-oxidant properties.¹⁰ Curcumin can regulate bone remodeling via increasing apoptosis,¹¹ and inhibits bone resorption by osteoclasts,¹² and also inhibits osteoclastogenesis by receptor activator of Nuclear Factor Kappa B Ligand (RANKL).¹³ The systemic application of *Nigella sativa* seed extract demonstrated incredibly positive effects on bone healing in experimental osteoporotic model.^{14,15} The purpose of this study was to compare the healing properties of honey, curcumin, ginger and *Nigella sativa* by each other and their combination by honey to assess their effects on bone healing in radial fracture animal model in rats.

Materials and Methods

Fifty-five adult, male, Sprague-Dawley Albino rats (mean weight = 350 ± 52 g) were used in this study. We observed the recommendations made by the Shiraz University Animal Rights Committee in all procedures. Also during the experiment, care was taken for all rats in accordance with the animal health guidelines published by the National Institutes of Health (NIH). The animals were kept under a 12 h light/dark cycle and room temperature of $22 \pm 3^\circ$ C. One hundred and ten radial bone defects were created in 55 rats which were randomly divided into 11 groups (5 rats per group). Groups 1-5 received honey, curcumin, ginger, and *Nigella sativa* orally by gavage and groups 6-10 received the same materials locally by rubbing them on the sutured skin daily for 15 days. The oral groups received the materials by gavage using 100 mg/0.5 ml, once a day for 15 days, including: Group 1: honey, Group 2: mixture of honey and curcumin (500 mg capsule), Group 3: mixture of honey and *Nigella sativa*

(1000 mg capsule), Group 4: mixture of honey and ginger (250 mg capsule), Group 5: mixture of honey, curcumin, *Nigella sativa*, and ginger. The local treatment groups received the material's respected oils by rubbing them on the sutured skin once a day for 15 days, including: Group 6: honey, Group 7: mixture of honey and curcumin (8 mg/kg),¹⁶ Group 8: mixture of honey and *Nigella sativa* (500 mg/kg),¹⁷ Group 9: mixture honey and ginger (100 mg/kg).¹⁸ Group 10: mixture of honey, curcumin, *Nigella sativa*, and ginger,¹⁹ Group 11: negative control group.

Before initiating the study process the animals were moved to new cages to get familiar with the new environment and diet. The water and food were freely accessible throughout the experiment. The rats were restrained on the table and the radial bone area prepared for an aseptic operation. In order to induce a bone defect, a 3 mm bone piece was harvested by approaching the midshaft of radius, under general anesthesia using ketamine (10%, 50 mg/kg, Alfamine, Alfasan, Woerden, Holland) and xylazine (2%, 10 mg/kg, Alfazyne, Alfasan, Woerden, Holland). After the bone piece was harvested, the defects were washed with normal saline, then the muscle and skin were sutured routinely. Analgesic and antibiotic treatment were administered by intramuscular injection of enrofloxacin (Enrofan 5%, 5 mg/kg) and meloxicam (Meloxivet 2%, 1 mg/kg) for 3 days.^{20,21} The animals were euthanized on 52nd postoperative day by rapid intracardiac injection of potassium chloride after inducing deep anesthesia.²² The radius and ulna complex were dissected and the healing area of the radius was evaluated macroscopically.

Histopathologic Evaluation

The dissected radius and ulna complexes (5 radius in each group) were fixed in 10% neutral buffered formalin solution, decalcified, routinely processed and 5 μ m in thickness tissue sections were stained by Hematoxylin and Eosin staining.

Biomechanical Evaluation

The samples intended for biomechanical assessments (5 radius in each group) were wrapped by soaked sterile gauze and kept at -70° C. The three-point bending test was performed by a universal tensile testing machine (Instron, London, UK).²³ The Extension on max force, yield point, max force and failure point were measured and calculated. All the extracted data from the load deformation curve were presented as Mean \pm Standard Error of Mean (SEM).²⁴

Results

During the 52 days of the study, there were no wound complications or local reactions. All animals had normal activity and mild weight gain at the end of the study period.

The histopathologic and biomechanical results of this study indicated that the bone healing in the honey (oral), the mixture of honey and curcumin (oral), and the mixture of honey and ginger (topical) groups improved significantly compared to the other groups. The detailed data are presented in the Tables 1, 2, 3, and 4. The information obtained is written based on scoreboard.²⁵ Statistical analysis of histopathologic and biomechanical results are shown in Tables 5 and 6, respectively.

The biomechanical results are presented in Figure 1. As shown in the figure, a significant superiority was seen in the group received oral honey and curcumin compared to the control group. Also the group received local honey and ginger showed a significantly better repair compared to the control group ($p = 0.006$). Groups receiving the mixture of honey and curcumin (oral) ($p = 0.015$), the mixture of honey and ginger (topical) ($p = 0.017$), and the mixture of honey and *Nigella sativa* (local) were significantly better

compared to the control group. The mixture of honey and *Nigella sativa* (oral) ($p = 0.860$), the mixture of honey and ginger (oral) ($p = 0.082$), the mixture of honey, curcumin, *Nigella sativa*, and ginger (oral) ($p = 0.388$), the honey (topical) ($p = 0.281$), the mixture of honey and curcumin (topical) ($p = 0.276$), the mixture of honey and ginger (topical) ($p = 0.061$) and the mixture of honey, curcumin, *Nigella sativa*, and ginger (topical) ($p = 0.322$) groups had not significant differences compared to the control group.

The histopathologic results are presented in Figure 2. The figure shows that the honey (oral) group had a significantly ($p = 0.004$) better result compared to the other groups. Also, the mixture of honey and curcumin (oral) ($p = 0.016$) and the mixture of honey and ginger (topical) ($p = 0.028$) had significantly better repair compared to the control group. The mixture of honey and *Nigella sativa* (oral) ($p = 0.999$), the mixture of honey and ginger (oral) ($p = 0.999$), the mixture of honey, curcumin, *Nigella sativa*, and ginger (oral) ($p = 0.999$), honey (topical) ($p = 0.999$), the mixture of honey and curcumin (topical) ($p = 0.267$), the mixture of honey and ginger (topical) ($p = 0.999$) and the mixture of honey, curcumin, *Nigella sativa*, and ginger (topical) ($p = 0.215$) had not significant differences compared to the control group.

Table 1. The results of radial bone histopathology in rats at 52 days post operation received oral medication (Mean \pm SEM).

Group	Marrow	Cortical bone	Cancellous bone	Proximal union	Distal union
G1	3.75 \pm 0.25	3.75 \pm 0.25	4.00 \pm 0.00	3.75 \pm 0.25	3.75 \pm 0.25
G2	3.75 \pm 0.25	3.50 \pm 0.50	3.50 \pm 0.28	3.25 \pm 0.48	3.25 \pm 0.48
G3	1.50 \pm 0.64	1.75 \pm 0.63	2.25 \pm 0.85	2.00 \pm 0.70	2.00 \pm 0.71
G4	1.60 \pm 0.24	1.20 \pm 0.37	3.00 \pm 0.32	2.00 \pm 0.00	2.00 \pm 0.00
G5	1.00 \pm 0.41	1.50 \pm 0.50	1.75 \pm 0.63	1.50 \pm 0.50	1.50 \pm 0.50

G1: honey, G2: mixture of honey and curcumin, G3: mixture of honey and *Nigella sativa*, G4: mixture of honey and ginger, G5: mixture of honey, curcumin, *Nigella sativa*, and ginger.

Table 2. The results of radial bone histopathology in rats at 52 postoperative day received medication locally (Mean \pm SEM).

Group	Marrow	Cortical Bone	Cancellous bone	Proximal Union	Distal Union
G6	1.60 \pm 0.68	1.80 \pm 0.58	2.00 \pm 0.63	1.80 \pm 0.58	1.80 \pm 0.58
G7	3.00 \pm 0.32	3.00 \pm 0.45	3.00 \pm 0.32	2.40 \pm 0.51	2.40 \pm 0.51
G8	3.25 \pm 0.75	3.75 \pm 0.25	3.75 \pm 0.25	3.25 \pm 0.48	3.25 \pm 0.48
G9	1.67 \pm 0.33	2.33 \pm 0.33	2.67 \pm 0.33	2.00 \pm 0.00	2.00 \pm 0.00
G10	2.67 \pm 0.33	3.00 \pm 0.00	3.33 \pm 0.33	3.00 \pm 0.00	3.00 \pm 0.00

G6: honey, G7: mixture of honey and curcumin, G8: mixture of honey and *Nigella Sativa*, G9: mixture of honey and ginger, G10: mixture of honey, curcumin, *Nigella sativa*, and Ginger, G11: negative control.

Table 3. The results of radial bone biomechanical study in rats at 52 days post operation received oral medication (Mean \pm SEM).

Group	Extension on max force(mm)	Yield point (N)	Max force (N)	Failure point(N)
G1	2.51 \pm 0.21	35.23 \pm 3.58	37.08 \pm 3.56	29.63 \pm 4.74
G2	2.76 \pm 0.07	38.72 \pm 2.76	41.81 \pm 2.52	40.94 \pm 2.24
G3	2.22 \pm 0.18	27.60 \pm 3.45	28.99 \pm 3.60	26.60 \pm 3.13
G4	2.40 \pm 0.54	36.12 \pm 4.84	42.74 \pm 6.72	32.2 \pm 3.78
G5	2.07 \pm 0.26	28.95 \pm 4.48	32.59 \pm 4.30	26.68 \pm 5.04

G1: honey, G2: mixture of honey and curcumin, G3: mixture of honey and *Nigella sativa*, G4: mixture of honey and ginger, G5: mixture of honey, curcumin, *Nigella sativa*, and ginger.

Table 4. The results of radial bone biomechanical study in rats at 52 days post operation received local medication (Mean \pm SEM).

Group	Extension on max force(mm)	Yield point (N)	Max force(N)	Failure point(N)
G6	2.31 \pm 0.35	28.29 \pm 2.37	30.58 \pm 2.13	27.75 \pm 1.66
G7	1.82 \pm 0.25	27.71 \pm 4.67	33.38 \pm 3.60	32.39 \pm 3.87
G8	1.97 \pm 0.17	40.53 \pm 7.91	43.50 \pm 8.26	42.07 \pm 7.78
G9	2.31 \pm 0.09	34.05 \pm 4.21	36.54 \pm 4.50	33.26 \pm 6.06
G10	2.42 \pm 0.39	33.65 \pm 6.68	36.42 \pm 6.19	34.58 \pm 4.84

G6: honey, G7: mixture of honey and curcumin, G8: mixture of honey and *Nigella sativa*, G9: mixture honey and ginger. G10: mixture of honey, curcumin, *Nigella sativa*, and ginger, G11: negative control.

Table 5. Statistical analysis of histopathology results. Comparing groups together by significant level of $p < 0.05$.

Group	G1	G2	G3	G4	G5	G6	G7	G8	G9	G10	G11
G1	-	0.508	0.026	0.012	0.017	0.012	0.071	0.508	0.028	0.042	0.013
G2	0.508	-	0.058	0.013	0.019	0.048	0.133	1.000	0.032	0.285	0.014
G3	0.026	0.058	-	0.802	0.457	0.902	0.457	0.081	0.858	0.212	0.327
G4	0.012	0.013	0.802	-	0.366	0.672	0.070	0.018	0.353	0.024	0.092
G5	0.017	0.019	0.457	0.366	-	0.455	0.045	0.027	0.195	0.032	0.537
G6	0.012	0.048	0.902	0.672	0.455	-	0.248	0.063	1.000	0.169	0.528
G7	0.071	0.133	0.457	0.070	0.045	0.248	-	0.317	0.219	0.546	0.016
G8	0.508	1.000	0.081	0.018	0.027	0.063	0.137	-	0.105	0.285	0.019
G9	0.028	0.032	0.858	0.353	0.195	1.000	0.219	0.105	-	0.050	0.072
G10	0.042	0.285	0.212	0.024	0.032	0.169	0.546	0.285	0.050	-	0.025
G11	0.013	0.014	0.327	0.092	0.537	0.528	0.016	0.019	0.072	0.025	-

G1: honey, G2: mixture of honey and curcumin, G3: mixture of honey and *Nigella sativa*, G4: mixture of honey and ginger, G5: mixture of honey, curcumin, *Nigella sativa*, and ginger, G6: honey, G7: mixture of honey and curcumin, G8: mixture of honey and *Nigella sativa*, G9: mixture honey and ginger. G10: mixture of honey, curcumin, *Nigella sativa*, and ginger, G11: negative control.

Table 6. Statistical analysis of biomechanical results. Comparing groups together by significant level of $P < 0.05$.

Group	G1	G2	G3	G4	G5	G6	G7	G8	G9	G10	G11
G1	-	1.000	0.083	0.462	0.149	0.014	0.140	0.043	0.480	0.480	0.014
G2	1.000	-	0.083	0.624	0.149	0.014	0.085	0.043	0.480	0.289	0.014
G3	0.083	0.083	-	0.086	0.386	0.806	0.325	0.021	0.157	0.480	0.624
G4	0.462	0.624	0.086	-	0.327	0.117	0.346	0.221	0.456	0.655	0.117
G5	0.149	0.149	0.386	0.327	-	0.806	1.000	0.043	0.289	0.480	0.221
G6	0.014	0.014	0.806	0.117	0.806	-	0.600	0.014	0.025	0.456	0.465
G7	0.140	0.140	0.325	0.346	1.000	0.600	-	0.027	0.177	0.453	0.116
G8	0.043	0.043	0.021	0.221	0.043	0.014	0.027	-	0.077	0.077	0.014
G9	0.480	0.480	0.157	0.456	0.289	0.025	0.177	0.077	-	0.513	0.025
G10	0.480	0.480	0.480	0.655	0.480	0.456	0.453	0.077	0.513	-	0.297
G11	0.014	0.014	0.624	0.117	0.221	0.465	0.116	0.014	0.025	0.29	-

G1: honey, G2: mixture of honey and curcumin, G3: mixture of honey and *Nigella sativa*, G4: mixture of honey and ginger, G5: mixture of honey, curcumin, *Nigella sativa*, and ginger, G6: honey, G7: mixture of honey and curcumin, G8: mixture of honey and *Nigella sativa*, G9: mixture of honey and ginger. G10: mixture of honey, curcumin, *Nigella sativa*, and ginger, G11: negative control.

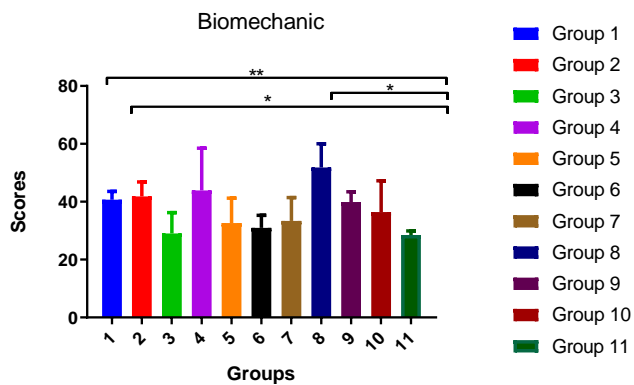


Figure 1. Biomechanical properties of the radius bone defect repair 52 days following injury maximum stress. The honey (orally) (** $p = 0.006$), Honey + curcumin (orally) (* $p = 0.014$), and Honey + *Nigella sativa* (locally) (* $p = 0.016$) had significant differences compared to the control group.

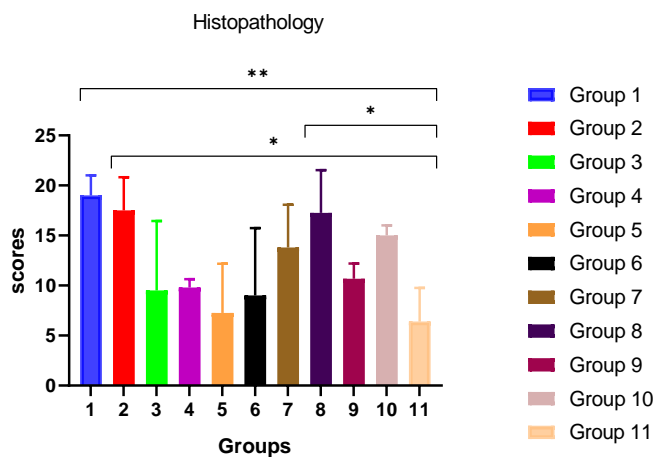


Figure 2. Histopathologic properties of the radius bone defect after 52 days. The Honey (orally) (** $p = 0.0045$), Honey + curcumin (orally) (* $p = 0.015$), and Honey + *Nigella sativa* (locally) (* $p = 0.027$) had significant differences compared to the control group.

Discussion

Considering the beneficial effects of ginger extract on the immune system, wound healing, and its antioxidant and antibacterial properties, ginger has starting potential for treating a number of ailments including degenerative disorders (arthritis and rheumatism). Honey can accentuate bone healing of mandibular small defects in rats.²⁶ It seems that the combination of these materials can be effective on bone healing.

Bone defects and abnormalities are among the most common diseases worldwide. Conventional and traditional treatments using bone alternatives in most cases induce fibrous tissue at the repair site instead of bone formation, in which case, there is a need for supplementary treatments. Among the methods of

healing bone defects, combination of tissue engineering has proved to be more efficient than other treatments.²⁷

According to literature this is the first study using honey with ginger (topically) and curcumin (oral) for bone healing in rat model. The results of the present study confirmed the positive role of honey, curcumin, and ginger in bone healing. Quantitative and qualitative interpretation of the results of the present study demonstrated significant differences between the honey (orally), the mixture of honey and curcumin (orally), and the mixture of honey and ginger (topically) compared to the other groups.

Several studies have reported the antibacterial effect of honey, which results in inhibition of bacterial colonization and promotes wound healing.²⁸ Antibacterial effect of honey is attributed to the riboflavin.²⁸ In addition, honey contains enzymes, such as catalase, which could have an antibacterial effect.²⁹ The pH of honey is low enough (3.2-4.5) to prevent bacterial growth.³⁰ A significant stage of bone repair is vascularization for providing enough oxygen and nutrition for the cells involved in healing process. Some studies reported that honey could accelerate wound healing by granulation tissue formation.^{31,32} Honey is clinically useful in various settings involving soft tissue infections and non-healing wounds.³³ The positive effect on bone density is probably due to honey containing high flavonoids and gluconic acid. Previous investigators claimed that gluconic acid which is the major organic acid in honey and carbohydrate constituents could enhance calcium absorption in the bone of rats.^{34,35} Kaempferol (flavonoids compounds in honey) also has osteogenic effect in ovariectomized rats.³⁶

Curcumin is a natural polyphenol extracted from *Curcuma longa*. It exhibits potent antioxidant and anti-inflammatory activities, inhibiting the production of free radicals, promoting radical scavenging and suppressing the production and release of inflammatory mediators. These properties may facilitate the attenuation of tissue and cellular injury in the liver, heart, kidney, brain, and bone, induced by oxidation or inflammation. Curcumin has a long history of use as a medicinal compound and is known to also have multiple anti-cancer properties.³⁷ The oral and topical administration of curcumin has been reported to be effective in wound repair of normal and diabetic wounds.³⁸ Curcumin-treated wound biopsies showed a large number of infiltrating cells such as macrophages, neutrophils, and fibroblasts as compared to untreated

wound. The presence of myofibroblast in curcumin-treated wounds demonstrated faster wound contraction.³⁹ The treatment led to an increased formation of granulation tissue including greater cellular content, neo-vascularization, and a faster re-epithelialization of wound in both diabetic as well as hydrocortisone-impaired wounds.⁴⁰ Topical application of curcumin can promote re-epithelialization in burn wounds to shorten the wound healing time.⁴¹

Ginger has received significant study as an analgesic in both human,^{42,44} and animal models.⁴⁵⁻⁴⁷ Ginger, in particular, is known to have anti-oxidant and anti-inflammatory properties,^{48,49} and has been reported to promote new blood vessel formation.⁵⁰ Major contribution of the ginger extract, is to increase vascularity and blood flow in the repairing tissue.⁵¹ Topical pretreatment with a combination of two natural products (curcumin and ginger extract) improves healing of subsequently induced abrasion skin wounds in corticosteroid-treated rats.⁵²

The histopathology and biomechanical results of this study indicated that the bone healing in the honey group (oral), the mixture of honey and curcumin (oral), and the mixture of honey and ginger (topically) improved significantly compared to other groups.

Acknowledgment

The authors are grateful to Mr. Moslem Rezaei, Mohsen Norouzi, Daryush Sarikhani and Esmaeil Dehdashti for their technical assistance during all procedures in the Department of Veterinary Surgery. The authors also respect the Shiraz University for their support.

Conflict of Interest

The authors declare no conflict of interest.

References

1. Ferguson C, Alpern E, Miclau T, Helms JA. Does adult fracture repair recapitulate embryonic skeletal formation? *Mechanisms of Development*. 1999; 87: 57-66.
2. Carter DR, Van der Meulen MC, Beaupre GS. Mechanical factors in bone growth and development. *Bone*. 1996; 18S: 5-10.
3. Rockwood Jr CA, Green DP, Bucholz RW, Heckman JD. Fractures in adults, 4th, Philadelphia: Lippincott, USA, 1996.
4. Molan PC. The role of honey in the management of wounds. *Journal of wound care*. 1999; 8(8): 415-418.
5. Al-Waili NS, Salom K, Butler G, Al Ghamdi AA. Honey and microbial infections: A review supporting the use of honey for microbial control. *Journal of Medicinal Food*. 2011; 14(10): 1079-1096.
6. Effendy NM, Norazlina M, Norliza M, Mohamad IN, Shuid AN. The effects of Tualang honey on bone metabolism of postmenopausal women. *Evidence Based Complement Alternat Medicine*. 2012; 93-98.
7. Shukla Y, Singh M. Cancer preventive properties of ginger: A brief review. *Food Chemical Toxicol* 2007; 45: 683-690.
8. Jiang H, Xie Z, Koo HJ, McLaughlin SP, Timmermann BN, Gang DR. Metabolic profiling and phylogenetic analysis of medicinal Zingiber species: Tools for authentication of ginger (*Zingiber officinale* Rosc.) *Phytochemistry*. 2006; 67:232-244.
9. Ali BH, Blunden G, Tanira MO, Nemmar A. Some phytochemical, pharmacological and toxicological properties of ginger (*Zingiber officinale* Roscoe): a review of recent research. *Food Chemical Toxicology*. 2008; 46: 409-420.
10. Panchatcharam M, Miriyala S, Gayathri VS, Suguna L. Curcumin improves wound healing by modulating collagen and decreasing reactive oxygen species. *Molecular Cell Biochemistry*. 2006; 290(1-2): 87-96.
11. Dae-Chul K, Tae K, Younghoon J, Joo-Kyung S. A synergistic bone sparing effect of Curcumin and Alendronate in ovariectomized rat. *Acta Neurochirurgica*. 2012; 154: 2215-2223.
12. French DL, Muir JM, Webber CE. The ovariectomized, mature rat model of postmenopausal osteoporosis: an assessment of the bone sparing effects of Curcumin. *Phytomedicine*. 2008; 15 (12): 1069-1078.
13. Bharti AC, Takada Y, Aggarwal BB. Curcumin (diferuloylmethane) inhibits receptor activator of NF- κ B ligand-induced NF- κ B activation in osteoclast precursors and suppresses osteoclastogenesis. *Journal of Immunology*. 2004; 172(10): 5940-5947.
14. Ezirganli S, Kazancioglu HO, Ozdemir H, Inan DS, Tek M. The effects of *Nigella sativa* Seed extract on bone healing in an experimental model. *Journal of Craniofacial Surgery*. 2016; 27(7): 1905-1909.
15. Cheng C, Alt V, Dimitrakopoulou-Strauss A, Pan L, Thormann U, Schnettler R, Weber K, Strauss LG. Evaluation of new bone formation in normal and osteoporotic rats with a 3-mm femur defect: functional assessment with dynamic PET-CT (dPET-CT) using 2-deoxy-2-[(18)F]fluoro-D-glucose ((18)F-FDG) and (18)F-fluoride. *Molecular Imaging Biol* 2013; 15(3): 336-344.
16. Mukhopadhyay MJ, Saha A, Mukherjee A. Studies on the clastogenic effect of turmeric and curcumin on cyclophosphamide and mitomycin in vivo, *Food Chemistry Toxicol* 1998; 36: 73-76.
17. Tamer A, Gheita, S, Kenawy A. Effectiveness of *Nigella sativa* Oil in the management of rheumatoid arthritis patients: A Placebo controlled study. *Phytotherapy Research*. 2011; 10: 1002-1009.
18. Weidner MS, Sigwart K. Investigation of the teratogenic potential of a *Zingiber officinale* extract in the rat. *Reproductive Toxicology*. 2001; 15: 75-80.
19. Lusania M, Gregg A, Cristina M, Araujo P, D'Arc J, Darin C, deLourdes M, Bianchi p. Effects of the antioxidants curcumin and vitamin C on cisplatin-induced clastogenesis in Wistar rat bone marrow cells. *Mutation*

- Research*. 2000; 465: 131–137.
20. Matthew P, Brennan MD, Albert J, Sinusas MD, Tamas L, Horvath DVM, Collins JG, Martha J. Harding, DVM. Correlation between body weight changes and postoperative pain in rats treated with meloxicam or buprenorphine. *Journal of Lab Animal*. 2009; 38(3): 87–93.
 21. Slate AR, Bandyopadhyay S, Francis KP, Papich MG, Karolewski B, Hod EA, Prestia KA. Efficacy of Enrofloxacin in a Mouse Model of Sepsis. *Journal of American Association for Lab Animal Science*. 2014; 53(4): 381–386.
 22. Tasker L, Methods for the euthanasia of dogs and cats: comparison and recommendations. World Society for Protection of animals. London. 2008.
 23. Oryan A, Alidadi S, Bigham-Sadegh A, Meimandi-Parizi A. Chitosan/gelatin/platelet gel enriched by a combination of hydroxyapatite and beta-tricalcium phosphate in healing of a radial bone defect model in rat, *International Journal of Biological Macromolecule*. 2017; 101: 630–637.
 24. Oryan A, Alidadi S, Bigham-Sadegh A, Moshiri A. Comparative study on the role of gelatin, chitosan and their combination as tissue engineered scaffolds on healing and regeneration of critical sized bone defects: an in vivo study. *Journal of Material Science Material Medicine*. 2016; 27: 155–161.
 25. Oryan A, Bigham S, Teshnizi F. Effects of osteogenic medium on healing of the experimental critical bone defect in a rabbit model. *Journal of bone*. 2008; 63: 53–60.
 26. Hajizadeh F, Derakhshan B, Peimani A, Abbasi Z. Effect of Topical Honey on Mandibular Bone Defect Healing in Rats. *Journal of Contemporary Dental Practice*. 2018; 19(1): 47–51.
 27. Bigham A, Oryan A, Karimi I, Hossini F, Sharifi S, Pakzad A. Effects of honey and hydroxyapatite on bone healing in rats. *Journal Trauma Monthly*. 2018; 23(4): 561–569.
 28. Efem SE. Clinical observations on the wound healing properties of honey. *British Journal of Surgery*. 1988; 75(7): 679–681.
 29. Weston RJ. The contribution of catalase and other natural products to the antibacterial activity of honey: a review. *Food Chemistry*. 2000; 71(2): 235–239.
 30. Singh VV, Pal US, Singh R, Soni N. Honey a sweet approach to alveolar osteitis: a study *National Journal Maxillofac Surgery*. 2014; 5(1): 31–34.
 31. Molan PC. The antibacterial activity of honey. 1. The nature of the antiabcterial activity. *Bee World*. 1992; 73(1): 5–28.
 32. Sazegar G, Seyed Reza AH, Behravan E. The effects of supplemental zinc and honey on wound healing in rats. *Iran Journal of Basic Medical Science*. 2011; 145(1): 3–9.
 33. Namias N. Honey in the management of infections. *Journal of Surgery Infect (Larchmt)*. 2003; 4(2): 219–226.
 34. Fournier P, Dupius Y. Modulation of intestinal absorption of calcium. *Journal of Physiology*. 1975; 70(4): 479–491.
 35. Ariefdjohan MW, Berdine RM, Lachcik PJ, Weaver CM. Acute and chronic effects of honey and its carbohydrate constituents on calcium absorption in rats. *Journal of Agriculture Food Chemistry*. 2008; 56(8): 2649–2654.
 36. Trivedi R, Kumar S, Kumar A, Siddiqui JA, Swarnkar G, Gupta V, Kendurker A, Dwivedi AK, Romero JR, Kaempferol has osteogenic effect in ovariectomized adult Sprague-Dawley rats. *Molecular Cellular Endocrinology*. 2008; 289(1-2): 85–93.
 37. Moran JM, Roncero-Martin R, Francisco J. Rodriguez V, Julian F, Calderon G, Purification R, Vicente, Maria L. Canal M, Juan D, Pedrera Z, Effects of Curcumin on the Proliferation and Mineralization of Human Osteoblast-Like Cells: Implications of Nitric Oxide. *International Journal of Molecular Sciences*. 2012; 13(12): 16104–16118.
 38. Leung A. Encyclopedia of common natural ingredients used in food, drugs, and cosmetics. John Wiley, New York, NY. 1980; 313–314.
 39. Sidhu GS, Singh AK, Thaloor D, Banaudha KK, Patnaik GK, Srimal RC, Maheshwari RK. Enhancement of wound healing by curcumin in animals. *Wound Repair and Regeneration* 1998; 6(2): 167–177.
 40. Sidhu GS, Mani H, Gaddipati JP, Singh AK, Seth P, Banaudha KK, Patnaik GK, Maheshwari RK. Curcumin enhances wound healing in streptozotocin induced diabetic rats and genetically diabetic mice. *Wound Repair and Regeneration*. 1999; 7(5): 362–374.
 41. Kulac M, Aktas C, Tulubas F, Uygur R, Kanter M, Erboğa M, Mehmet C, Topcu B, Aslan O, The effects of topical treatment with curcumin on burn wound healing in rats. *Journal of Molecular Histology*. 2013; 44(1): 83–90.
 42. Bartels EM, Folmer VN, Bliddal H, Altman RD, Juhl C, Tarp S, Zhang W, Christensen R. Efficacy and safety of ginger in osteoarthritis patients: A meta-analysis of randomized placebo-controlled trials. *Osteoarthritis Cartilage*. 2015; 23: 13–21.
 43. Rahnema P, Montazeri A, Huseini HF, Kianbakht S, Naseri M. Effect of *Zingiber officinale* R. rhizomes (ginger) on pain relief in primary dysmenorrhea: A placebo randomized trial. *BMC Complement Alternative* 2012; 12: 92–96.
 44. Terry R, Posadzki P, Watson LK, Ernst E. The use of ginger (*Zingiber officinale*) for the treatment of pain: A systematic review of clinical trials. *Pain Medicine*. 2011; 12: 1808–1818.
 45. Darvishzadeh-Mahani F, Esmaeili-Mahani S, Komeili G, Sheibani V, Zare L. Ginger (*Zingiber officinale Roscoe*) prevents the development of morphine analgesic tolerance and physical dependence in rats. *Journal of Ethnopharmacology*. 2012; 141: 901–907,
 46. Reid SA, Speedy DB, Thompson JM, Noakes TD, Mulligan G, Page T, Campbell RG, Milne C. Study of hematological and biochemical parameters in runners completing a standard marathon. *Clinical Journal of Sport Medicine*. 2004; 14: 344–353.
 47. Sepahvand R, Esmaeili-Mahani S, Arzi A, Rasouljan B, Abbasnejad M. Ginger (*Zingiber officinale Roscoe*) elicits antinociceptive properties and potentiates morphine-induced analgesia in the rat radiant heat tail-flick test. *Journal of Medical Food*. 2010; 13: 1397–1401.
 48. Ali BH, Blunden G, Tanira MO, Nemmar A. Some phytochemical, pharmacological and toxicological properties of ginger (*Zingiber officinale Roscoe*): a review of recent research. *Food Chemical Toxicol* 2008; 46: 409–420.
 49. Lantz RC, Chen GJ, Sarihan M, Solyom AM, Jolad SD,

- Timmermann BN. The effect of extracts from ginger rhizome on inflammatory mediator production. 2007; 14: 123-128.
50. Qadir M, Imran B, Farhan M. Effect of ginger extract on angiogenesis using CAM assay. *Bangladesh Journal of Pharmacol* 2017; 12: 348-353.
51. Bhagavathula N, Roscoe L, Warner M, DaSilva, BS, Shannon D, McClintock BS; Adam B, Muhammad N, Aslam MD, Kent J, Johnson MD, James, P. A combination of curcumin and ginger extract improves abrasion wound healing in corticosteroid-impaired hairless rat skin. *Wound Repair and Regeneration*, 2009; 17: 360-366.
52. Dehghani SN, Bahrololum ME, Ghaderi AA, Ghadirian SB, Faghihi Z, Javidi M, Emami MJ. Hydroxyapatite stem cell repair of radial fracture gap in rabbits, *Online Journal of Veterinary Research*. 2017; 21(9): 616-619.