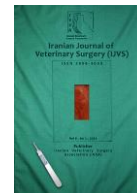



Iranian Veterinary Surgery Association

## Iranian Journal of Veterinary Surgery

Journal homepage: [www.ivsajournals.com](http://www.ivsajournals.com)

### Clinical Report

## Idiopathic Congenital Cervical Megaesophagus in a Goat Kid

Masoud Ahmadnejad<sup>1</sup>, Ghader Jalilzadeh-Amin<sup>1\*</sup>, Seyed Mohammad Hashemi-Asl<sup>2</sup>

<sup>1</sup> Department of Internal Medicine and Clinical Pathology, Faculty of Veterinary Medicine, Urmia University, Urmia, Iran. <sup>2</sup> Department of Surgery and Diagnostic Imaging, Faculty of Veterinary Medicine, Urmia University, Urmia, Iran.

| ARTICLE INFO   | ABSTRACT  |
|--|---|
| <p><i>Article History:</i></p> <p>Received 2 February 2021<br/>Revised 5 April 2021<br/>Accepted 21 April 2021<br/>Online 21 April 2021</p> <hr/> <p><i>Keywords:</i></p> <p>Megaesophagus<br/>Congenital<br/>Goat<br/>Dysphagia<br/>Regurgitation</p> | <p>Megaesophagus is atony and dilatation of the esophagus that is usually congenitally but acquired cases also happen. Salivation, regurgitation, aspiration pneumonia, and esophagitis are complications of the megaesophagus. Megaesophagus has been reported in various animals including horses, cows, buffaloes, goats, sheep, dogs, and cats but the occurrence is rare in ruminants. The exact etiology of the megaesophagus remains unknown. A two-day-old goat kid from a goat herd was referred to veterinary education and teaching hospital who regurgitate after milk feeding and sometimes cough. An Enlargement was felt under the throat after milk feeding. Two similar cases in this herd had died with these symptoms in the past month. All vital signs and complete blood cell count of the animal were normal. Lateral plain radiographs and contrast radiographs with barium contrast were performed for further examination. Radiographic findings confirmed the congenital cervical megaesophagus. Esophageal massage to the down direction and the forelimb raising after eating a small amount of milk was also recommended for this animal as a treatment protocol. It was recommended that the bucks should be culled to control the possible genetic origin. In our follow-up after a week, the kid was alive, but dead in the second week. This report presents the descriptions of clinical and radiographical findings of a congenital cervical megaesophagus in a kid. The complications can be relatively controlled with special care, but it is unlikely that the animal can be kept alive for long periods.</p> |

### Case Description

A two days old goat kid weighing about 2.5 kg with a history of milk regurgitation from the mouth referred to the The Urmia University Veterinary Education and Teaching Hospital. The kid had no problem at birth and looked healthy. The kid sucked directly from its mother's udders but usually coughing occurs after

drinking milk. According to the history taking from the farmer, two other kids were born with this problem and died within a week in the last month. The kid was alert on examination and all vital clinical signs and measurement of complete blood cell count were normal in normal range. The kid was presented with a history of regurgitation and coughing after each milking period. After drinking the milk, a soft swelling was felt at the

\* Correspondence to: Ghader Jalilzadeh-Amin; Department of Clinical Sciences, Faculty of Veterinary Medicine, Urmia University, Urmia, Iran. E-mail: [g.jalilzadeh@gmail.com](mailto:g.jalilzadeh@gmail.com); [g.jalilzadeh@urmia.ac.ir](mailto:g.jalilzadeh@urmia.ac.ir)  
www.ivsajournals.com © Iranian Journal of Veterinary Surgery, 2021  
<https://doi.org/10.30500/IVSA.2021.271465.1247>



This work is licensed under the Creative Commons Attribution-NonCommercial 4.0 International License. To view a copy of this license, visit <http://creativecommons.org/licenses/by-nc/4.0/>.

cervical region and in the inlet of the thorax. No other abnormal findings were observed on clinical examination.

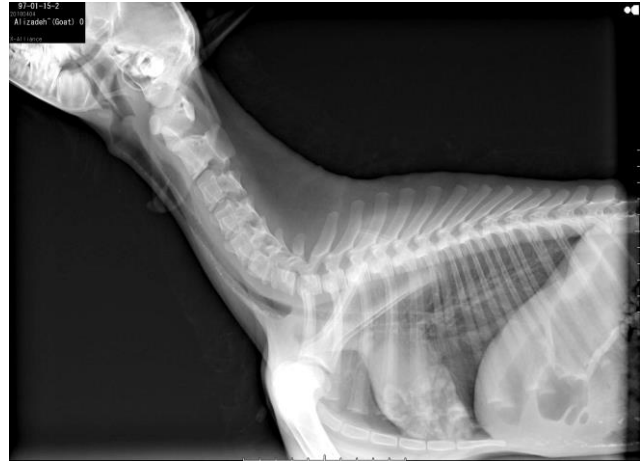For further examination, a plain lateral radiograph of the neck and chest was performed without chemical sedation (Figure 1). Survey radiograph showed some food and air residues in the cervical esophagus and heterogeneous opacity on the heart ventricles. The lungs were also normal on this radiograph. Barium contrast radiography (esophagogram) was suggested for specific esophageal examinations. 15 ml of 33% barium sulfate suspension was fed to the animal using a drencher and the radiograph was taken (Figure 2). Radiographic findings showed remaining of the barium in the cervical esophagus. A few minutes later, the radiograph was repeated from the same place to confirm the absence of barium drainage from the esophagus, and the cervical megaesophagus was approved (Figure 3). In both plain and contrast radiography, a heterogeneous opacity was observed on the heart ventricles. According to our previous experiences, this finding can be associated with necrosis and calcification. According to radiographic findings, congenital cervical megaesophagus was confirmed in this case.

### Treatment and Outcome

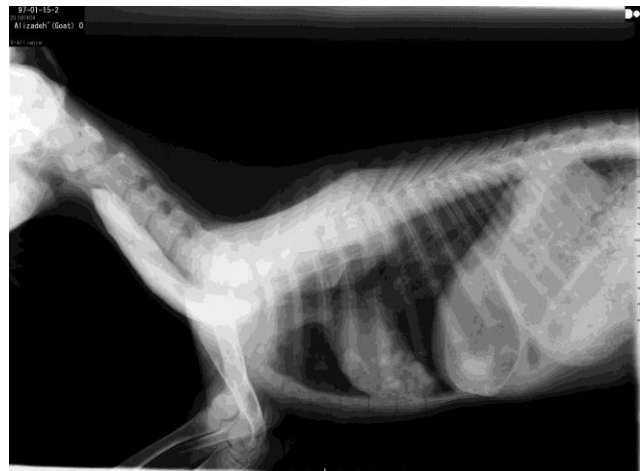In this case, it was recommended that milk feeding be done manually and accompanied by massaging the esophagus in down direction. Raising the forelimb after eating and feeding of small amount of milk for each meal also was recommended. Culling of the buck was recommended to remove the possible genetic origin of the disease from the herd. In our follow-up after a week, the kid was alive, but its general condition was not good and the next week the kid was died.

### Clinical Relevance

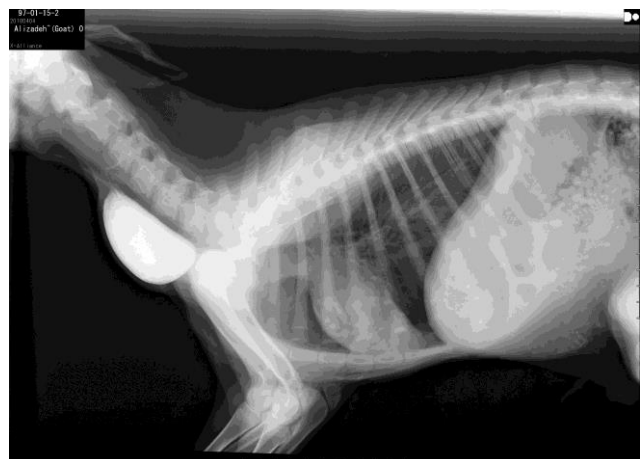
Megaesophagus is atony and dilatation of the esophagus that is usually congenitally but acquired cases also happen. Megaesophagus associated with dysfunction of the esophagus, especially in the esophageal sphincter. Normally, food passes through the esophagus with smoky movements, but in the megaesophagus, saliva, food, and water remain inside the esophagus. Salivation, regurgitation, aspiration pneumonia, esophagitis, gastric ulceration, and esophagus stenosis are some of the complications associated with megaesophagus. Radiography,



**Figure 1:** Plain lateral radiograph of the neck and chest in a kid with congenital cervical megaesophagus. Some food and air residues are seen in the cervical esophagus. Also, calcified heterogeneous opacity is visible on the heart ventricles.



**Figure 2:** Contrast lateral radiography immediately after ingestion of the barium sulfate. In this view, barium accumulation is seen in the cervical esophagus.



**Figure 3:** Survey lateral radiograph from the same area with barium administration. Accumulation of barium sulfate is seen in a sac-like shape in the esophagus, suggested the accumulation of the contrast matter at the lowest level of esophagus lumen in the cervical region.

electromyography, and measurement of esophageal lumen pressure can be used to diagnose megaesophagus.<sup>1-3</sup>

Megaesophagus has been reported in various animals including horses, cows, buffaloes, goats, sheep, dogs, and cats.<sup>4-11</sup> The occurrence of megaesophagus is rare in ruminants and is associated with regurgitation symptoms. In most cases, the etiology of megaesophagus remains unknown, but organophosphate poisoning, vagal neuropathy, and myopathy of the esophageal muscles in lambs are suspected causes.<sup>3</sup> One of the possible and unproven causes of megaesophagus is plant toxins that cause segmental muscle necrosis.<sup>6</sup> Genetics are involved in the occurrence of megaesophagus in dogs and cats. A report in a bovine megaesophagus has been associated with a hiatal hernia that may have been associated with vagus nerve involvement.<sup>12</sup> There were no signs of vagal nerve involvement (Horner's syndrome) in the present case.

Today, various methods are used to diagnose esophageal abnormalities. In this case, due to the very clear findings of contrast radiography, there was no need for other examinations. Due to the relatively aggressive nature of the electromyography and esophageal manometry procedure and the small size of the body, radiography was preferred in the present case.

A case of megaesophagus from a two-year-old goat has been reported to regurgitate after eating food and water and chronic weight loss. Megaesophagus was confirmed by radiography, but its etiology remained unknown. The animal died after one month without surgical intervention.<sup>13</sup> In a report in a Sunan adult goat, the megaesophagus was seen with thymoma in the thoracic cavity that showed signs of bloating and regurgitation<sup>14</sup>. There were no signs of mass or tumor in our clinical examination or radiograph of the present case but like the previous two reports, this animal also had regurgitation.

There is a report of megaesophagus in 2-5-year-old Brazilian goat and sheep with segmental necrosis in esophageal and skeletal muscle. The diagnostic test for bluetongue was negative and despite the epidemiological evidence for the involvement of plant toxins in the occurrence of this disease, no corroborative evidence was found for this issue.<sup>6</sup> No bluetongue test was performed in the present case and no evidence of maternal or infant poisoning was found.

There is a report of the occurrence of a congenital megaesophagus in a 15-day-old Holstein calf that has been radiographically confirmed and euthanized for bad prognosis. Except for two contractions at the surface of the aortic arch and the location of the dorsal branches of the vagus nerve, no macroscopic defects that caused megaesophagus were observed in this case.<sup>7</sup> Aspiration pneumonia is one of the reported complications of megaesophagus and esophageal ectasia. In our case, there were no clinical signs of respiratory problems in the kids. In an adult sheep, megaesophagus was associated with recurrent bloating,<sup>15</sup> but in our case, there was no sign of bloating in the animal.

In a report, acquired megaesophagus was detected in a seven-month-old Holstein calf by contrast radiography. Manual assistance in nutrition, fluid therapy, and antibiotic therapy improved clinical signs, but relapses of regurgitation and cough continued.<sup>16</sup> A one-month-old calf was diagnosed with megaesophagus by contrast radiography and attempts to treat aspiration pneumonia with antibiotics and metoclopramide failed, and the animal died.<sup>17</sup> In our case, although aspiration pneumonia did not develop in the animal at the time of referral, the treatment was not successful. Newer therapies, such as neural therapy, have been used to treat megaesophagus in animals, but there is still no reliable way to megaesophagus treatment.<sup>5</sup>

Our findings in the present case show that barium contrast radiography is a useful non-invasive method for diagnosing megaesophagus in the kid. The complications of megaesophagus can be relatively controlled with special care for a week, but it is unlikely that the animal can be kept alive for long periods. The occurrence of several cases in a herd indicates that this problem might be inherited in goats and it needs more investigation and removing the buck may be helpful in this situation.

### Conflict of Interest

The authors declare no conflicts of interest related to this report.

### References

1. Constable P, Hinchcliff K, Done S, Grünberg W. *Veterinary medicine-e-book: a textbook of the diseases of cattle, horses, sheep, pigs and goats*. 2016.

2. Smith B. Large Animal Internal Medicine, 5<sup>th</sup> Edn. 2024.
3. Watrous BJ, Pearson EG, Smith BB, Snyder SP, Blythe LL, Riebold TW, Hedstrom OR. Megaesophagus in 15 llamas: a retrospective study (1985–1993). *Journal of Veterinary Internal Medicine*. 1995;9(2):92-99.
4. Abu-seida AM, Torad FA, Hassan EA, Ali KM. Feline hypertrophic osteopathy associated with congenital megaesophagus: two case reports and literature review. *Journal of the Hellenic Veterinary Medical Society*. 2020;71(3):2413.
5. Lima G, Vianna LR, Castro A. Neural therapy in the treatment of congenital megaesophagus in dog: case report. *Pubvet*. 2019;13(9):1-6.
6. Nascimento EM, Campos ÉM, Maia LÂ, Medeiros RM, Alcântara MD, Vilar SD, Riet-Correa F. Megaesophagus in sheep and goats. *Ciência Rural*. 2016;46:1450-1455.
7. Ulutas B, Sarierler M, Bayramli G, Ocal K. Macroscopic findings of idiopathic congenital megaesophagus in a calf. *Veterinary Record*. 2006;158(1):26–27.
8. Ross C E, Rebhun WC. Megaesophagus in a cow. *Journal of the American Veterinary Medical Association*. 1986;188(6):623–624.
9. Albarella S, Ciotola F, D’Anza E, Coletta A, Zicarelli L, Peretti V. Congenital Malformations in River Buffalo (*Bubalus bubalis*). *Animals*. 2017;7(12):9.
10. Ndikuwera J, Odiawo GO, Usenik EA. Idiopathic megaesophagus in a pregnant heifer. *Veterinary Record*. 1990;126(7):165–166.
11. Vestweber JG, Leipold HW, Knighton RG. Idiopathic megaesophagus in a calf: clinical and pathologic features. *Journal of the American Veterinary Medical Association*. 1985;187(12):1369–1370.
12. Anderson NV, Vestweber JG, Voisin AJ, Mills LJ. Hiatal hernia and segmental megaesophagus in a cow. *Journal of the American Veterinary Medical Association*. 1984; 84(2):193–195.
13. Mozaffari AA, Dariushvosough D. Idiopathic megaesophagus in a goat: clinical and radiological features. *Iranian Journal of Veterinary Surgery*. 2007;2(2):94–97.
14. Parish SM, Middleton JR, Baldwin TJ. Clinical megaesophagus in a goat with thymoma. *Veterinary Record*. 1996;139(4):94.
15. do Prado Guirro EC, Martin CC, Hilgert AR, Pagliosa GM, Silva MM. Clinical, radiographic and pathological analyses of megaesophagus in sheep – Case report. *Revista Veterinária em Foco*. 2017;15(1):45-57.
16. Jalilzadeh-Amin G, Hashemiasl S. Megaesophagus in the upper cervical oesophagus in a steer: A case report. *Veterinary Medicine (Praha)*. 2015;60(1):48–51.
17. Ismail AM, Gopalakrishnan A, Arunaman CS, Shammi M, Kavitha S, Sumathi D, Jayathangaraj MG, Joseph C. Secondary Aspiration Pneumonia in a Calf. *Indian Veterinary Journal*. 2019 Jul;96(07):63-64.