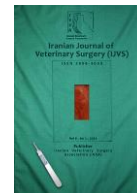



Iranian Veterinary Surgery Association

IRANIAN JOURNAL OF VETERINARY SURGERY

Journal homepage: www.ivsajournals.com



Short Communication

Ultrasonographic Evaluation of the Effect of *Nigella Sativa* Oil on Prostate Dimensions in Adult Iranian Mixed-Breed Dogs

Roham Vali^{1*}, Satar Safarpour², Yasaman Daneshvar²

¹Department of Clinical Sciences, School of Veterinary Medicine, Kazerun Branch, Islamic Azad University, Kazerun, Iran.

²D.V.M, School of Veterinary Medicine, Kazerun Branch, Islamic Azad University, Kazerun, Iran.

Received: 18 May 2020
Accepted: 6 October 2020
Online: 6 October 2020

Keywords:

Ultrasonographic;
Measurements;
Nigella Sativa;
Prostate;
Iranian mixed-breed dogs.

Abstract

Objective- The aim of the present study was to assess the effect of *Nigella sativa* oil on prostate dimensions in adult dogs.

Design- Experimental study

Animals- Five adult male dogs

Procedures- In this research, 5 adult male Iranian mixed-breed dogs with a mean age of 7.30 ± 2.77 years and a mean weight of 27 ± 5.7 kg with clinical symptoms of prostatitis were selected. Sagittal and transverse ultrasound images were performed by using a 5 MHZ convex transducer.

Results- In the obtained images desired parameters such as length, width and height of the prostate gland were measured before and after administration of *Nigella sativa*. Results showed significant differences between all measured parameters before and after drug administration ($p < 0.05$).

Conclusion and Clinical Relevance- This study confirms that *Nigella sativa* oil can reduce prostatic dimensions in adult male dogs. So, it can be used as a safe and effective drug for the treatment of prostate-related diseases such as benign prostatic hyperplasia in dogs.

* Correspondence to: Roham Vali, Assistant Professor, Department of Clinical Sciences, School of Veterinary Medicine, Kazerun Branch, Islamic Azad University, Kazerun, Iran. E-mail: rohamvali@gmail.com



1. Introduction

Nigella sativa is a flowering plant, originated from south eastern Asia, both seeds and oil extracted from this plant are used in medicinal purposes. In traditional medicine for thousands of years, the seeds, oils and extracts of *Nigella sativa* have been used as an anticancer agent.¹ Much of the biological activities of the seeds have been shown to be due to thymoquinone, the major component of the essential oil, which is also present in the fixed oil. Thymoquinone is a relatively safe compound, particularly when given orally to experimental animals.² The prostate gland is located ventral to the colon and caudal to the neck of the urinary bladder, in an abdominal or pelvic position.³ Its size varies with the weight and breed of the dog for example it is physiologically bigger in breeds like Westies and Scottish Terriers than others. It is commonly accepted that, after 5 years of age, most dogs (> 60%) show a certain degree of prostatic hypertrophy.⁴ The prostate is clearly enlarged and hypertrophic in nearly 100% of dogs around the age of 10 to 12 years. It is located in the pelvis in young dogs, and becomes more abdominal and then fully abdominal after 8-12 years.⁵ Benign enlargement of the prostate gland associated with glandular hyperplasia or squamous metaplasia has been shown to start in dogs as early as 2 years of age. It is often considered as a common finding related to age but can lead to urologic and digestive disorders.⁶ Therefore, identification and characterization of benign prostatic hyperplasia (BPH) is important. In one study, 95% of intact beagles over 9 years of age were affected. Prostate enlargement may be symmetrical or asymmetrical or associated with loss of the bilobed shape in transverse section. The diagnosis of prostatic disorders requires a gland assessment by physical and imaging examinations. The ultrasonographic appearance of the prostate gland provides information on the shape, dimensions, lobular structure, and echotexture of the gland parenchyma.⁷ It also shows the prostate urethra and is feasible for an assessment of the gland capsule and

adjacent tissues. The aim of the present study is to assess the effect of *Nigella sativa* oil on prostate dimensions in adult Iranian mixed-breed dogs

2. Materials and Methods

Five adult Iranian mixed-breed male dogs aged 7.30 ± 2.77 years and the mean weight of 27 ± 5.7 kg were used in this study. Physical, abdominal, and rectal examinations were performed in all dogs. Prostatic specific antigen (PSA) test of all dogs were above 0.005 ng/dl and were candidate for castration. The obtained results were recorded for each dog. The dogs were sedated with 2 mg/kg aceethylpromazine given intramuscularly. After cleaning and washing, hair was clipped and shaved on both sides of prepuce. Transabdominal ultrasonography was performed by using a 5 MHz convex transducer (BK Medical minifocus). Coupling gel was applied on the skin to improve contact. For each dog, sagittal and transverse images of the prostate gland were obtained. After initial ultrasound, all dogs received *Nigella sativa* oil (2 ml/kg/day) orally according to Padmaa⁸ for two month. At the end of the treatment period, the dogs were sonographed and images were taken again and prostate dimensions were measured. True sagittal position was confirmed by observing the hypoechoic urethral tract.

Ultrasonographic Measurements

In sagittal and transverse images the following parameters were measured before and after administration of *Nigella sativa*.

1. Prostatic length: The length is well measurable on the sagittal images and was defined as the maximum diameter of the gland along the urethral axis (Figure 1).
2. Prostatic height: The height of the prostate is measureable on both sagittal and transverse images and defined as the diameter of prostate on a line separating the two lobes of the gland (Figure 1).

3. Prostatic width: the width is measurable on the transverse images and was defined as the maximum diameter perpendicular to the axis of the height (Figure 2). All images should be provided where the transducer is perpendicular to the skin to avoid oblique sections of the prostate.

3. Results

In images the shape, echotexture and symmetry of the prostate gland less changed.

Table 1 summarizes the results of measurements in both sagittal and transverse images from the prostate gland of all dogs before and after administration of *Nigella sativa* oil that describe the location and size of the prostate. In ultrasound images two month after medication all prostate dimensions decreased and showed significant differences compared with before administration of *Nigella sativa*. Prostatic depth and prostatic height showed maximum and minimum reduction respectively. In Table 2 the results of our study compared with that of other reports.

4. Discussion

Benign prostatic hyperplasia is a common disorder in old intact male dogs. The common clinical signs observed in dogs with benign prostatic hyperplasia are dripping of prostatic sanguineous fluid from the penile tip, hematuria,

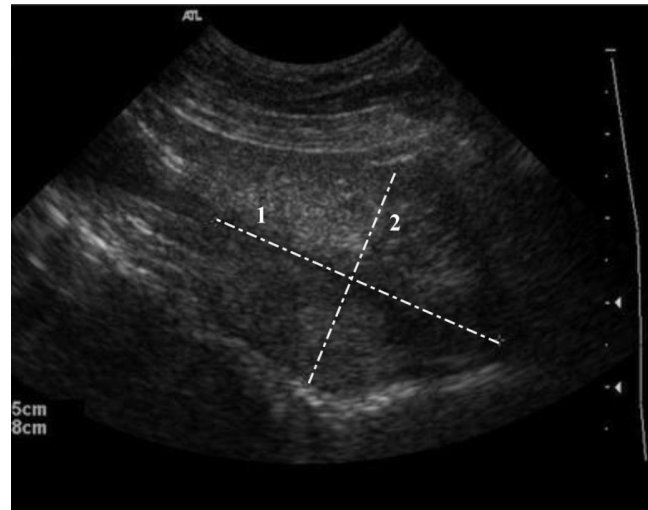


Figure 1. Sagittal ultrasonographic image from the prostate that indicating the measured parameters. Parameters: 1 = Length, 2 = Height

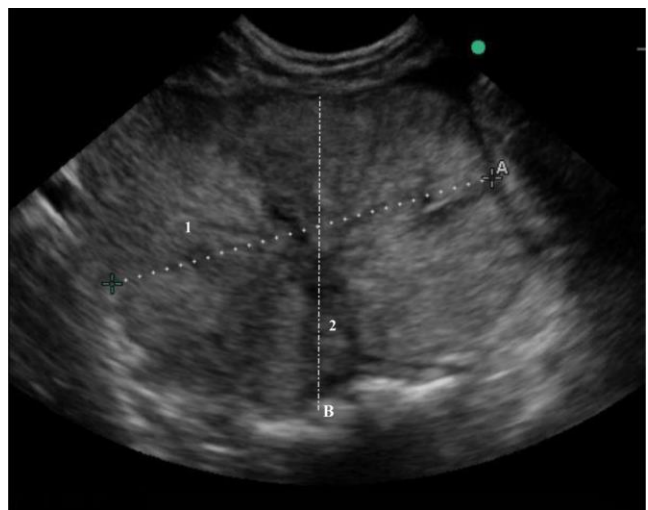


Figure 2. Transverse ultrasonographic image from the prostate that indicating the measured parameters. Parameters: 1 = Depth, 2 = Height

Table 1. Ultrasonographic prostatic measurements in 5 adult Iranian mixed-breed dogs before and after administration of *Nigella sativa*.

Parameter (cm)	Before	After	Min	Max	p Value
Prostatic Length	6.55 ± 0.12	5.71 ± 0.97	4.45	8.28	0.023
Prostatic Height	4.36 ± 0.35	3.86 ± 0.32	3.48	4.15	0.046
Prostatic Depth	5.69 ± 0.85	4.79 ± 0.92	4.25	6.44	0.00002

Table 2. Comparison between the results of this study and other reports.

Prostatic length (cm)	Prostatic height (cm)	Prostatic depth (cm)	Reference
6.55 ± 0.12	4.36 ± 0.35	5.69 ± 0.85	This study
6.23 ± 0.82	4.08 ± 0.33	5.11 ± 0.06	Vali. (2018) ¹³
3.4 ± 1.10	2.8 ± 0.08	3.3 ± 0.09	Ruel <i>et al.</i> (1998) ¹⁰
5.4 ± 1.30	2.34 ± 1.11	-	Atalan <i>et al.</i> (1999) ⁷
3.35 ± 0.4	2.78 ± 0.5	3.42 ± 0.53	Ghadiri <i>et al.</i> (2013) ¹²

stranguria, and constipation.⁶ Previous studies have shown the role of several herbs in the treatment of benign prostatic hyperplasia including. An antiproliferative effect of nettle root extract has been observed both in an *in vivo* and *in vitro* model. A significant antiproliferative effect of the extract was found in human prostatic epithelial cells, whereas stromal cell growth remained unaltered.⁹ Another study concluded that some hydrophobic constituents such as steroids in the stinging nettle roots inhibited the membrane Na⁺,K⁽⁺⁾-ATPase activity of the prostate, which may subsequently suppress prostate-cell metabolism and growth.⁹ Studies on *Nigella sativa* showed that the crude oil and thymoquinone extracted from its seeds and oil are effective against many diseases like cancer, cardiovascular complications, diabetes, asthma, kidney disease, etc.¹ It is effective against cancer in blood system, lung, kidney, liver, prostate, breast, cervix, and skin with much safety.² There are published studies on radiographic and ultrasonographic measurements of prostate gland in humans and dogs.^{7,10,11,12} Several hypotheses are on the causes of the prostate diseases. One suggests that benign prostatic hyperplasia mainly affects older dogs than young ones.⁴ According to this theory, benign prostatic hyperplasia is an age related disease that seen in most breeds.^{3,4} Debiak and Balicki were studied to evaluate the prostate gland size and location in 33 male dogs of various breeds. They showed that the application of transabdominal imaging technique produced images with good quality details from the cranial prostate region in all the examined animals from the cases with a normal size of the prostate gland.³ Zohil *et al.* compared two techniques of ultrasound imaging for prostate gland scanning. They reported that when the prostate is not enlarged and is located in pelvis area, transrectal ultrasonography well show the changes in echotexture and capsule of prostate gland, while enlarged prostate were observed in abdominal portion and well seen with transabdominal ultrasonography.⁵ In another study conducted by the author on 10 adult intact Iranian mixed-breed dogs, the desired

parameters in this study were measured. Atalan *et al.* measured prostatic dimensions in different breeds of dogs in a wide variety of body weight and age with both radiography and ultrasonography method, then compared the results.⁷ According to these authors, ultrasonography is more accurate in differentiation of soft tissues and fluids. They also reported the amount of prostatic length and width were 5.4 ± 1.30 and 4.3 ± 1.11 cm, respectively.¹¹ Ruel *et al.* evaluated the prostate in 100 healthy adult intact male dogs. They compared prostatic parameters with parameters related to body size such as height and weight. They found significant positive correlations were between all prostatic parameters and parameters related to body size and age.¹⁰ The amount of prostatic length and width in mentioned study were 3.4 ± 1.1 and 3.3 ± 0.9 cm.¹⁰ Ghadiri *et al.* measured the prostatic dimensions in 10 intact male dogs referred to veterinary teaching hospital that required euthanasia for reasons other than prostatic disease. Their body weights ranged 16-23 kg and their ages between 2 to 4 years old.¹² In our study according to mean age of dogs (over 7 years old) transabdominal ultrasonography were used and prostatic dimensions and changes were recorded. The findings of the present study differed from mentioned studies especially Ruel *et al.* and Ghadiri *et al.* We obtained greater prostatic dimensions than above studies. In our study prostatic dimensions (length, Depth, and Height) before administration of *Nigella sativa* were as 6.55 ± 0.12 , 5.69 ± 0.85 , and 4.36 ± 0.35 cm, respectively. Differences between above studies were probably due to differences in breed, age and number of dogs, on the other hand all dogs in present study showed clinical signs of prostate enlargement. In another study prostatic dimensions in 10 adult Iranian mixed-breed dogs were measured, the amounts of that study are close in agreement with the present study.¹³ The findings of Atalan *et al.* were slightly in agreement with the results obtained before administration of *Nigella sativa* in this study. The amount of our study after administration of *Nigella sativa* showed lesser than pre-medication. In the oil of *Nigella*

sativa there was four pharmacologically important components: thymoquinone, dithymoquinone, thymohydroquinone (THQ), and thymol (THY). Much of the biological activities of the seeds have been shown to be due to thymoquinone, the major component of the essential oil, which is also present in the fixed oil.^{1,2}

In conclusion, measurements of this study confirm that *Nigella sativa* oil can reduce prostatic dimensions in dogs. So, it can be used as a safe and effective drug for treatment of prostate-related diseases such as benign prostatic hyperplasia in Iranian mixed-breed dogs.

Conflict of Interests

The Authors declare there is no conflict of interest.

References

1. Srinivasan K. Cumin (*Cuminum cyminum*) and black cumin (*Nigella sativa*) seeds: traditional uses, chemical constituents, and nutraceutical effects. *Food Quality and Safety*, 2018; 2(1): 1–16.
2. Ali BH, Blunden, G. Pharmacological and toxicological properties of *Nigella sativa*. *Phytother Research*, 2003; 17: 299–305.
3. Debiak, P., Balicki, I. Diagnostic imaging of the canine prostate gland subject to its location and size. *Bulletin of the Veterinary Institute in Pulawy*, 2009; 53: 313-317.
4. Berry SJ, Coffey DS, Ewing LL. Effects of aging on prostate growth in beagles. *American Journal of Physiology*, 1986; 250: 1039-1046.
5. Zohil AM, Castellano C. Prepubic and transrectal ultrasonography of the canine prostate: A comparative study. *Veterinary Radiology & Ultrasound*, 1995; 36: 393-396.
6. Lévy X, Nizański W, von Heimendahl A, Mimouni P. Diagnosis of common prostatic conditions in dogs: an update. *Reproduction in Domestic Animals*, 2014; 49: 50-57.
7. Atalan G, Holt PE, Barr FJ, Brown PJ. Ultrasonographic estimation of prostatic size in canine cadavers. *Research in Veterinary Science*, 1999; 67: 7-15.
8. Padmaa MP. *Nigella sativa*– A comprehensive review, *Indian Journal of Natural Products and Resource*, 2010; 1(4): 409-429.
9. Konrad L, Müller HH Lenz C. Antiproliferative effect on human prostate cancer cells by a stinging nettle root (*Urtica dioica*) extract. *Planta Medica*, 2000; 66(1): 44-47.
10. Ruel Y, Barthez PY, Mailles A, Begon D. Ultrasonographic evaluation of the prostate in healthy intact dogs. *Veterinary Radiology and Ultrasound*, 1998; 39(3): 212-216.
11. Atalan G, Barr FJ, Holt PE. Comparison of ultrasonographic and radiographic measurements of canine prostate dimensions. *Veterinary Radiology and Ultrasound*, 1999; 40: 408-412.
12. Ghadiri A, Avizeh R, Baniadam A, Ranjbar A. comparison of transabdominal and transrectal ultrasonography of the prostate gland in dogs. *Iranian Journal of Veterinary Surgery*, 2013; 8(2): 43-48.
13. Vali R. Ultrasonographic measurements of prostatic dimensions in adult Iranian mix breed dogs. *Journal of Alternative Veterinary Medicine*, 2018; 2(5): 266-272.