



Clinical Report

Ocular Dermoid Cyst in a Four-Month-Old Holstein Calf

Rahman Allahvirdizadeh¹, Rahim mohammadi², Aliasghar Tehrani³, Vahid Najarnezhad^{1*}

¹Department of Internal Medicine, Faculty of Veterinary Medicine, Urmia University, Urmia, Iran.

²Department of Surgery and Diagnostic Imaging, Faculty of Veterinary Medicine, Urmia University, Urmia, Iran.

³Department of Pathobiology, Faculty of Veterinary Medicine, Urmia University, Urmia, Iran.

Received: 8 December 2019

Accepted: 7 April 2020

Online: 7 April 2020

Keywords:

Dermoid cyst;

Holstein calves;

Eye;

Histopathology.

Abstract

Case Description- A four-month-old female Holstein calf was presented to the Veterinary Teaching Hospital of Urmia University with a history of abnormal hairy growth on the right eye since birth.

Clinical Findings- On general examination, the animal was alert. Body temperature, heart rate, respiratory rate, menace test, and pupillary light reflex were normal. On ophthalmic examination, a hairy mass was observed on the conjunctivae, third eyelid, sclera, and cornea of the right eye. Histopathological examination revealed the mass with three distinct areas of skin. It was diagnosed as an ocular dermoid cyst and surgical treatment was warranted.

Treatment and Outcome- The mass was surgically excised to prevent damage to the anterior chamber of the eye. Ocular healing was satisfactory in a 4 week follow up.

Clinical Relevance- This report described an ocular dermoid cyst in a four-month Holstein calf. There was just lacrimation, possibly due to irritation caused by the hairs. The ocular dermoid cyst could be excised surgically, and the prognosis is good.

* Correspondence to: Vahid Najarnezhad; Department of Internal Medicine, Faculty of Veterinary Medicine, Urmia University, Urmia, Iran. E-mail: v.najarnezhad@urmia.ac.ir



1. Case Description and Clinical Findings

In July 2019, a 4 months old male Holstein calf was presented to the Veterinary Teaching Hospital of Urmia University with a history of abnormal hairy growth on the right eye since birth. On general examination, the animal was alert. Body temperature, heart rate, respiratory rate, and capillary refill time were 39.4°C, 90 beats per minute, 38 breaths per minute, and 3 seconds, respectively. On ophthalmic examination, a hairy mass was observed on the conjunctivae, third eyelid, sclera, and cornea of the right eye (Figure 1). There was lacrimation possibly due to irritation caused by the hairs (Figure 2). The menace test and pupillary Light reflex were normal and the animal did not show visual impairment. No other ocular abnormalities were observed in the eye. The blood parameters including total white blood cells (WBC), granulocytes (GR), lymphocytes (LY), monocytes (MO), eosinophil (EO), red blood cells (RBC), hematocrit (HCT), platelets (PLT), total protein (TP) and fibrinogen concentrations, were within normal ranges.

Histopathological examination revealed the mass with three distinct areas of skin (Figure 3). Its surface showed non-keratinized squamous tissue. The dermal layer was consisted of thick collagen with hair follicles and sebaceous glands, and hair follicles with several rows of large epithelial cells and with adherent structures (Figure 4). Apocrine glands were covered by cubic epithelial cells with large openings in the hypodermis area (Figure 5).

2. Treatment and Outcome

Auriculopalpebral nerve block was performed with 5 ml lidocaine hydrochloride 2% (Aburaihan Pharmaceutical Co., Tehran, Iran) and local anesthesia was also performed around the eyelid. The mass was surgically excised to prevent damage to the anterior chamber of the eye. The excised tissue was submitted for histopathology. Post operatively systemic antibiotic including gentamicin (Nasr

Pharmaceutical Co., Fariman, Iran) 4 mg/kg, IM, q 24 h for 5 days, and flunixin meglumine (Erfan Daroo Co., Tehran, Iran) 0.5 mg/kg, IM, q 24 h for 4 days were administered. Topical oxytetracycline ointment (Kimia Pharmaceutical Co., Tehran, Iran) was also administered q 12 h for 5 days. The healing was satisfactory by a 4-week follow up.

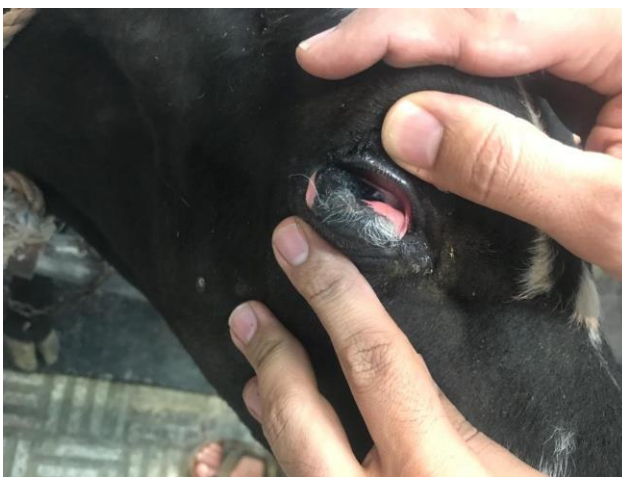

Figure 1. Hairy mass on the conjunctivae, third eyelid, sclera and cornea of the right eye.

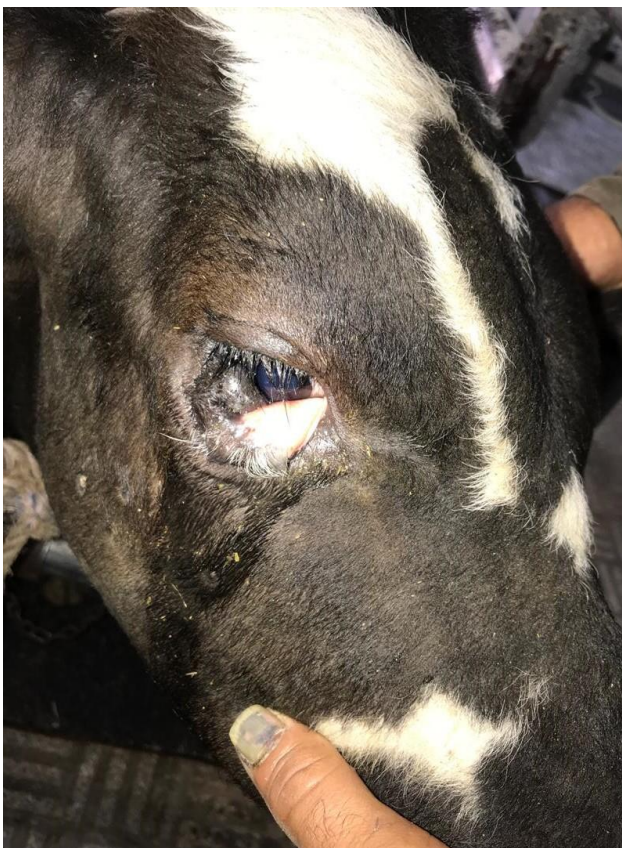

Figure 2. Lacrimation due to irritation caused by the hairs.

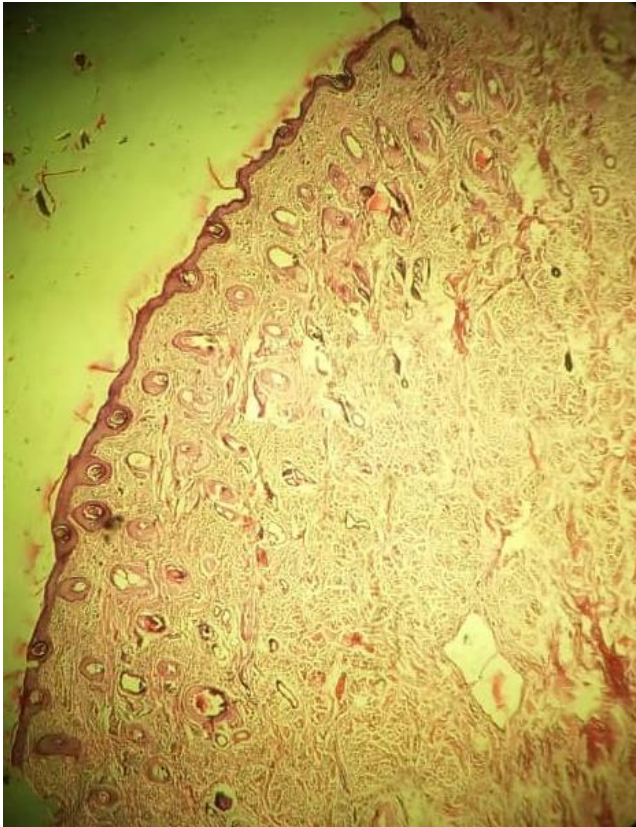


Figure 3. Three distinct areas of skin including epidermis, dermis and hypodermis in dermoid cyst (hematoxylin and eosin, $\times 10$).

3. Clinical Relevance

Ocular dermoid cysts are developmental choristomas that originate from aberrant primordial tissues and are histologically characterized with squamous cell lining, keratinoid or mucoid content, occasionally associated with the fatty component and calcified structure.¹ It can be unilateral or bilateral and may be associated with other ocular manifestation or with other malformations. Hair from the lesions is predominantly responsible for the associated irritation resulting in chronic inflammation of the conjunctivae and cornea and may cause visual impairment.²⁻⁴ Dermoids may affect the eyelids, conjunctiva, nictitans, sclera, and cornea.⁵ The present report describes a case of an ocular dermoid cyst in a Holstein calf.

According to history, clinical and histopathological findings, it was revealed that the calf had a congenital malformation of ocular dermoid cyst on right eye. Dermoid

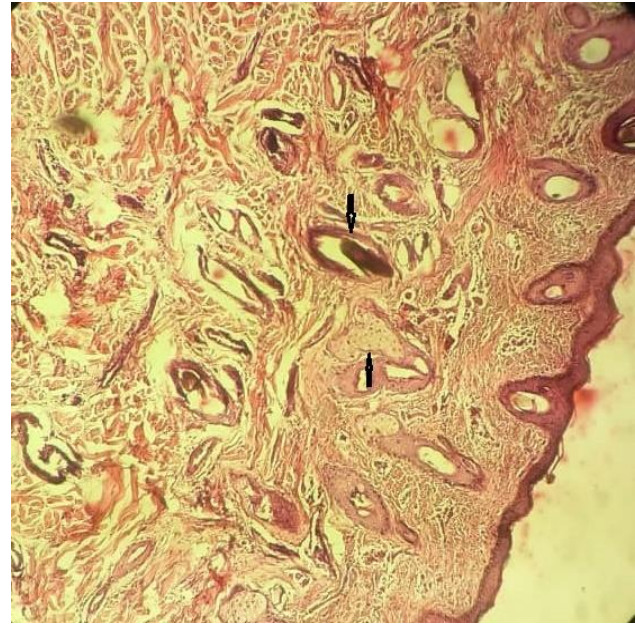


Figure 4. Arrows show thick collagen with hair follicles and sebaceous glands in dermal layer of dermoid cyst (hematoxylin and eosin, $\times 40$)

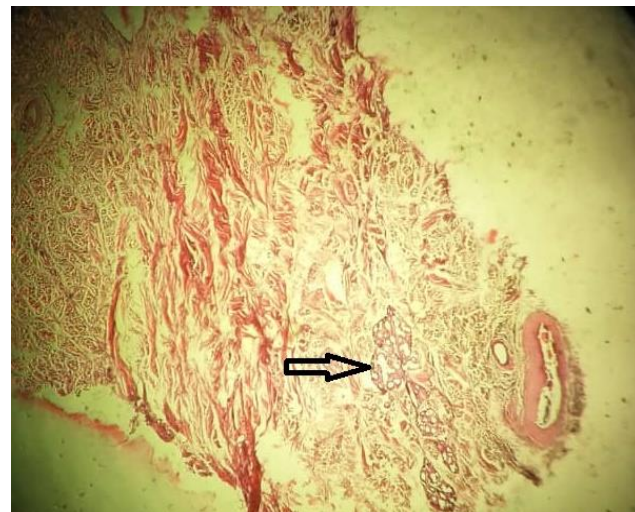


Figure 5. Arrow shows apocrine glands covered by cubic epithelial cells with large openings in the hypodermis area (hematoxylin and eosin, $\times 40$)

cyst was successfully removed. Post-operative recovery was satisfactory and reexamination did not show any sign of reoccurrence of dermoid cyst one month later. Dermoids have been reported frequently in human, cattle, horse, buffalo, camel, sheep, goat, pig, dog, and cat,^{5,6} but ocular dermoid cysts are not common in cattle. Ocular dermoids are christomas of normal tissue formation at abnormal locations.^{7,8} In this case, a skin-like tissue was grown on the conjunctivae, third eyelid, and sclera of the eye.

Ocular dermoids are a congenital overgrowth of heterotrophic defect which appear at the incorrect site of the eyes.^{7,8} They have also been reported as being acquired secondary to the traumatic displacement of epithelial tissue.⁹ Sarrafzadeh-Rezaei *et al.* reported a congenital ocular dermoid cyst in the form of a soft, fluctuant, non-tender, hyperaemic cystic mass overlying at the lower eyelid of the left eye.¹⁰ The findings of the present case were in agreement with Kiliç, who reported that Holstein Friesians crossbred calf was affected with unilateral dermoid on the right eye.¹¹ Dermoid may be located in the third eyelid, cornea, conjunctiva, corneconjunctival junction, and limbus region.¹² Tunio *et al.* reported a dermoid tissue of approximately 1cm size on the lower part of the eyelid in the cornea of Thari breed cattle calf.¹³ Bekele *et al.* reported a hairy growth on the limbus and bulbar conjunctiva of the left eye in a three-week-old crossbred calf.¹⁴ Similar findings were observed in this case which the dermoid cyst was located on the conjunctivae, third eyelid, sclera, and cornea. Dermoids may contain the dermis, epidermis, hair follicle, and sebaceous gland.⁶ The mass in the present case contained hair follicles along with skin like appendages.

Treatment of dermoids has to be done by exenteration, enucleation, cryotherapy, evisceration, lamellar keratotomy, or combination of technique.⁸ Superficial lamellar keratectomy has been found to be a more successful technique for corneal dermoid excision.¹⁰ In the present case, a partial wedge resection of the conjunctiva was performed for treatment. This made the calf to recover uneventfully without reoccurrence.

References

1. Nishie A, Yoshimitsu K, Honda H, Irie H, Aibe H, Shinozaki K, Mizumoto K, Matsuo Y, Masuda K. Presacral dermoid cyst with scanty fat component: usefulness of chemical shift and diffusion-weighted MR imaging. *Computerized Medical Imaging and Graphics*, 2003; 27: 293–296.
2. Moore CP, Shaner JB, Halenda RM, Rosenfeld CS, Suedmeyer WK. Congenital ocular anomalies and ventricular septal defect in a dromedary camel (*Camelus dromedarius*). *Journal of Zoo and Wildlife Medicine*, 1999; 30(3): 423-430.
3. Yeraham I, Perl S, Liberboim M. Ocular dermoid in dairy cattle - 12 years survey. *Revue de Médecine Vétérinaire*, 2002; 153(2): 91-92.
4. Barkyoumb SD, Leipold HW. Nature and cause of bilateral ocular dermoids in Hereford cattle. *Veterinary Pathology*, 1984; 21(3): 316-324.
5. Lawson DD. Corneal dermoids in animals. *Veterinary Record*, 1975; 97: 449-450.
6. Constable PD, Hinchcliff KW, Done SH, Grunberg W. *Veterinary Medicine: A textbook of the diseases of cattle, sheep, goats, pigs and horses*. 11th ed. Saunders Elsevier. Philadelphia, 2017.
7. Golubovic SZ, Latkovic Z, Horvatic-Obradovic M. Surgical treatment of large corneal dermoid. *Documenta Ophthalmologica*, 1995; 91(1): 25-32.
8. Kiliç N. Cardiopulmonary, biochemical, and haematological changes after detomidine-midazolam-ketamine anaesthesia in calves. *Bulletin of the Veterinary Institute in Pulawy*, 2008; 52(3): 423-426.
9. Hillyer LI, Jackson AP, Quinn GC, Day MJ. Epidermal (infundibular) and dermoid cysts in the dorsal midline of a three-year-old thoroughbred-cross gelding. *Veterinary Dermatology*, 2003; 14(4): 205–209.
10. Sarrafzadeh-Rezaei F, Farshid AA, Saifzadeh S. Congenital ocular dermoid cyst in a river buffalo (*Bubalus bubalis*) calf. *Journal of Veterinary Medicine Series A*, 2006; 54: 51-54.
11. Kiliç N, Toplu N, Epikmen ET. Surgical Treatment of Corneal Large Dermoid in a Simmental Calf. *Acta Scientiae Veterinariae*, 2012; 40(2): 1-5.
12. Mansour AM, Barber JC, Reinecke RD, Wang FM. Ocular choristomas. *Survey of Ophthalmology*, 1989; 33(5): 339-358.
13. Tunio A, Bughio S, Abro SH, Kalhoro DH, Memon AA. Eye dermoid in a thari breed cattle calf and its surgical management: A case study. *Pakistan Journal of Agriculture Engineering and Veterinary Sciences*, 2016; 32(2): 295-299.
14. Bekele T, Bhokre AP, Mekonnen B, Tesfaye W, Alemu B, Tintagu T, Gebrekidan B. Ocular dermoid in crossbred calf- A case report. *Ethiopian Veterinary Journal*, 2014; 18(1): 105-108.