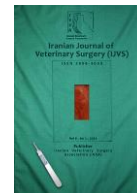



Iranian Veterinary Surgery Association

IRANIAN JOURNAL OF VETERINARY SURGERY

Journal homepage: www.ivsajournals.com

ORIGINAL ARTICLE

Beneficial Effects of Nanocurcumin Loaded Chitosan Biofilm on Healing of Full Thickness Excisional Wounds in Diabetic Rats

Hamid Shamsi¹, Mohammad Velayati¹, Hakim Rahimzadeh¹, Negin Mozafari², Ramin Mazaheri-Khameneh^{3*}

¹ Educated, Faculty of Veterinary Medicine, Urmia University, Urmia, Iran.

² Department of Clinical Sciences, Faculty of Veterinary Medicine, University of Tabriz, Tabriz, Iran.

³ Department of Surgery and Diagnostic Imaging, Faculty of Veterinary Medicine, Urmia University, Urmia, Iran.

Abstract

Objective- In diabetes impaired wound healing and other tissue abnormalities are considered as major concerns. The novel therapeutic options for treatment of wound in diabetic patients are urgently needed. The aim of the present study was to assess beneficial effects of chitosan nanocurcumin biofilm on healing of full thickness excisional wounds in diabetic rats.

Design- Experimental Study

Animals- Forty male diabetic Wistar rats

Procedures- The animals were randomized into four groups of ten animals each. Induction of diabetes was achieved using 60 mg/kg streptozotocin. In group I, 0.1 ml sterile saline 0.9% solution was added to the wounds with no dressing. In group II, the wounds were dressed with chitosan thin-film membranes. In group III, the wounds were treated with curcumin nanoparticles. In group IV, animals with were dressed with chitosan nanocurcumin biofilm.

Results- Planimetric, histological and quantitative morphometric studies and determination of hydroxyproline levels showed that there was significant difference between animals in group IV compared to other groups ($p = 0.001$).

Conclusion and Clinical Relevance- Chitosan nanocurcumin biofilm improved healing of diabetic wound in rats

Received: 12 November 2019

Accepted: 15 February 2020

Online: 15 February 2020

Keywords:

Chitosan nanocurcumin;

Biofilm;

Diabetic rat;

Wound.

* Correspondence to: Ramin Mazaheri-Khameneh, Department of Surgery and Diagnostic Imaging, Faculty of Veterinary Medicine, Urmia University, Urmia, Iran. E-mail: r.mazaheri@urmia.ac.ir

www.ivsajournals.com© Iranian Journal of Veterinary Surgery, 2020

This work is licensed under the Creative Commons Attribution-NonCommercial 4.0 International License. To view a copy of this license, visit <http://creativecommons.org/licenses/by-nc/4.0/>.

DOI: 10.30500/ivsaj.2020.208499.1203



1. Introduction

Functional biomaterials research has built on new drug delivery systems and enhanced scaffolds for regenerative medicine that is recently one of the most developing fields in the life sciences.¹ In diabetes impaired wound healing and other tissue abnormalities are considered as a major concern.² The biochemical mechanisms involved in the healing process are mainly associated with disorders in collagen production that consequently end up delayed re-epithelialization in wounds, compromised migration and proliferation of keratinocytes and fibroblasts.³ Various treatments have been adopted to solve this complex clinical problem, however, only a few have been proven to be effective.⁴

The prevalence of diabetes has become a major clinical problem and a serious issue for public health. The impaired wound healing in diabetic patients is one of the complications.⁵ Lack of cellular and molecular signals required for normal wound repair process such as angiogenesis, granulation tissue formation, epithelialization, and remodeling are encountered in diabetic patients that contribute to the poor healing of diabetic wound. The normal healing process in healthy individuals occur at an optimal rate, however, it is usually delayed or even completely compromised in diabetic patient.⁵

In cases of severe distortion of the tissue architecture, the healing process may not lead to morphofunctional normality but result in the formation of disoriented connective tissue with a fibrous appearance.^{6,7} This abnormal tissue architecture reduces the mechanical strength and leads to scar formation. Biomaterials can assist the proper physiological reconstruction of the skin and reduce or prevent scar tissue formation. Chitin, chitosan, and their oligomers have been found to promote wound healing, especially in the phases of proliferation and matrix formation.⁸ Chitosan and its oligomers are well

known for their interesting biological properties, which have led to various applications. Lysozyme slowly hydrolyzes chitosan membrane and produces chito-oligomers that stimulate correct deposition, assembly and orientation of collagen fibrils in extracellular matrix components.⁹ Moreover, it has been indicated that chitosan membrane stimulates the migration of inflammatory cells and promotes cellular organization.^{10,11}

Various agents, anti-inflammatory and antioxidant free radical scavengers have been reported with promising beneficial effects on wound healing.¹² Curcumin is the main phenolic pigment extracted from turmeric, the powdered rhizome of *Curcuma longa*, along with demethoxy curcumin and bisdemethoxy curcumin.¹³ Extensive research indicates that curcumin possesses potent antioxidant, anti-inflammatory, properties, and it also inhibits lipid peroxidation and scavenges superoxide anion, singlet oxygen, nitric oxide, and hydroxyl radicals.¹⁴⁻¹⁶ Data regarding curcumin properties potentially relevant for wound healing has been promising.¹⁷ However, its poor water solubility and fast degradation profile make it compromise over its bioavailability way below the threshold level on administration. Over a period of time, a lot of emphasis has been given to improve the biodistribution of native curcumin, but it is only recently that the application of the field of nanotherapeutics has significantly improved its therapeutic efficacy. This is through the development of nanorange formulations of curcumin, popularly known as the nanocurcumin.¹⁸

The aim of the present study was to assess beneficial effects of chitosan nanocurcumin biofilm on healing of full thickness excisional wounds in diabetic rats. The assessments were based on excision wound model and planimetric studies, histological preparation and quantitative morphometric studies and determination of hydroxyproline levels.

2. Materials and Methods

All reagents were research grade and purchased from Sigma-Aldrich, St. Louis, MO. and used without further purification

Induction of Diabetes

For insulin-deficient diabetes, rats were fasted overnight before receiving a single intraperitoneal injection (60 mg/kg in 0.9% sterile saline) of streptozotocin (STZ). Hyperglycemia (15 mmol/l or greater) was confirmed 2 days later by measurement of tail-vein blood glucose concentration (Ames Glucostix; Myles, Elkhart, IN). The rats underwent the procedures three days after induction of diabetes.

Synthesis and Characterization of Nanocurcumin

Nanocurcumin was synthesized based on a method described by others.¹⁹ Curcumin solution was prepared by dissolving curcumin powder in ethanol. Under ultrasonication condition, this solution was added to boiling water in drop-wise mode. The solution was sonicated for about 30 minutes. After which, the mixture was stirred at 800 rpm for about 20 minutes till we obtained the orange colored precipitate. Afterward, the supernatant was removed and the obtained pellet was used for the study. The particle size of the nano-curcumin powder was determined using transmission electron microscope (TEM, JEM-HR 2100, Japan) and accelerating voltage 200 kV.

Preparation and Characterization of Chitosan Nanocurcumin Biofilm

Chitosan was dissolved in 2% aqueous acetic acid solution at room temperature with stirring to prepare chitosan solution. Nanocurcumin-loaded chitosan (50:50) nanocomposite was prepared. Nanocurcumin with

concentration of 5 wt% was dissolved in ethanol with chitosan (50:50). The resulting solution was stirred carefully few hours until a homogenous yellow color solution was obtained. Finally, the solution was poured into glass Petri dish and left to evaporate the solvent at room temperature overnight and chitosan nanocurcumin biofilm was harvested. The homogeneity of the samples and distribution of the curcumin powder in the polymer matrix was investigated by Scanning electron microscope, (SEM/EDX, Philips XL30, Japan). The infrared spectrum was recorded by a JASCO FT/ IR 300 E Fourier transform infrared (FTIR) Spectrometer (Tokyo, Japan).

The Procedure for Wound Creation

Rats were anesthetized by an intraperitoneal injection of ketamine (70 mg/kg of BW) and xylazine (5mg/kg of BW), the hair on their back was shaved and the skin cleansed with 70% alcohol solution. Following shaving and aseptic preparation, a circular excision wound was made by cutting away approximately 115 mm² full thickness of predetermined area on the anterior-dorsal side of each rat. The rats were returned to individual cages and they were examined daily.

Study Design and Animals

This study was carried out in strict accordance with the guidelines of the Ethics Committee of the International Association for the Study of Pain.²⁰ Forty male rats were randomized into four groups of ten animals each. Forty male diabetic rats were randomized into four groups of ten animals each. Induction of diabetes was achieved using 60 mg/kg streptozotocin. In group I, 0.1 ml sterile saline 0.9% solution was added to the wounds with no dressing. In group II, the wounds were dressed with chitosan thin-film membranes. In group III, the wounds were treated with curcumin nanoparticles. In group IV, animals with were dressed with chitosan nanocurcumin biofilm.

Excision Wound Model and Wound Area Measurements

Wound-healing property was evaluated by wound contraction percentage and wound closure time. Photographs were taken immediately after wounding and on days 6, 9, 12, 15, 18 and 21 post-wounding by a digital camera while a ruler was placed near the wounds. The wound areas were analyzed by Measuring Tool of Adobe Acrobat 9 Pro Extended software (Adobe Systems Inc, San Jose, CA, USA) and wound contraction percentage was calculated using the following formula:

$$\text{Percentage of wound contraction} = (A_0 - A_t) / A_0 \times 100$$

Where A_0 is the original wound area and A_t is the wound area at the time of imaging. Animal houses were in standard environmental conditions of temperature ($22 \pm 3^\circ \text{C}$), humidity ($60 \pm 5\%$), and a 12 h light/dark cycle. The animals were maintained on standard pellet diet and tap water. All rats were closely observed for any infection and if they showed signs of infection were separated, excluded from the study and replaced.

Histology and Morphometric Studies

The tissue samples were taken on 7, 14, 21 days after surgery from periphery of the wound along with normal skin and fixed in 10% buffered formalin, dehydrated and embedded in paraffin wax, sectioned at $5 \mu\text{m}$ and stained with hematoxylin and eosin (H&E) and Masson's trichrome stains. Photomicrographs were obtained under light microscope to assess the predominant stage of wound healing. Three parallel sections were obtained from each specimen. Cellular infiltration including the number of mononuclear cells, polymorphonuclear cells and fibroblastic aggregation were quantitatively evaluated. Acute hemorrhage, congestion, vascularization, epithelialization, collagen production and density were also evaluated qualitatively. Morphological findings were scored using image analyzing software (Image-Pro Express, version 6.0.0.319, Media Cybernetics, Silver

Springs, MD, USA). The histological parameters were classified according to the intensity of occurrence in five levels (- absence; + discrete; ++ moderate; +++ intense; ++++ very intense).¹⁸

Determination of Hydroxyproline Levels

On the day 21 after surgery, a piece of skin from the healed wound area was collected and analyzed for hydroxyproline content. As a major part of collagen, hydroxyproline has an essential role in collagen stability. The collagen is the major component of extracellular tissue, which gives support and strength. Tissues were dried in a hot air oven at $60\text{--}70^\circ \text{C}$ to constant weight and were hydrolyzed in 6N HCl at 130°C for 4 h in sealed tubes. The hydrolysate was neutralized to pH 7.0 and was subjected to chloramine-T oxidation for 20 minutes. The reaction was terminated by addition of 0.4 M perchloric acid and color was developed with the help of Ehrlich reagent at 60°C and measured at 557 nm using UV-visible spectrophotometer.

Statistical Analyses

Differences among groups were evaluated by Kruskal–Wallis variance analysis. When the p -value from the Kruskal–Wallis test statistics was statistically significant, multiple comparison tests were used to know differences. Comparison among days was assessed by Mann–Whitney U-test. The Bonferroni correction was applied for all possible multiple comparisons. SPSS 18 (SPSS Inc., Chicago, IL, USA) was used for statistical analysis. A p -value was set at 0.05.

3. Results

Characterization of Curcumin Nanoparticles and Chitosan Nanocurcumin Biofilm

Figures 1 and 2 show TEM, SEM and FTIR spectra of chitosan, nanocurcumin particles and chitosan nanocurcumin conduit. TEM micrograph of the

nanocurcumin shows that the particles are in nano ranges of less than 100 nm in diameter (Figure 1). The nanocurcumin loaded chitosan has shown all the characteristic bands of the pure blend with a slight shift of the bands at 1160, 1582, and 1672 cm^{-1} . The stretching vibration at 3627 cm^{-1} corresponding to OH/ NH₂ groups has shifted to 3647 cm^{-1} , indicating that the nanocurcumin has been bonded to the functional groups of the chitosan (Figure 2).

Reduction in Wound Area

Wound contraction percentage in different groups within the study period is shown in Table 1. The healing rate of wounds in group IV was significantly different compared to groups III and II ($p = 0.001$).

Histological and Morphometric Findings

There were significant differences in comparisons of group IV and III, particularly in terms of cellular infiltration, acute hemorrhage, congestion, edema, collagen production and density, reepithelialisation and neovascularization. During the study period, scores for reepithelialisation and neovascularization were significantly higher in group IV rats than groups III and II ($p = 0.001$). Polymorphonuclear (PMN) and mononuclear (MNC) cell count, fibroblast cell proliferation and also Mean Rank of the qualitative study of acute hemorrhage, edema and collagen production score in group IV were significantly higher than those of groups III and II ($p = 0.001$) (Table 2, Figures 3-6).

Hydroxyproline Content of Wound

Proline is hydroxylated to form hydroxyproline after protein synthesis. Hydroxyproline contents in groups I to IV were found to be 48.60 ± 2.77 , 67.70 ± 2.10 , 75.10 ± 3.15 , and 73.15 ± 2.19 mg/g, respectively. Hydroxyproline contents were significantly increased in the group IV

which implies more collagen deposition compared to groups III and II ($p = 0.001$).

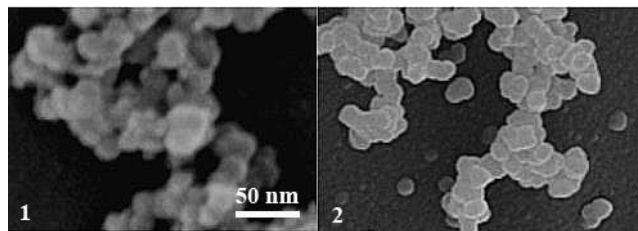


Figure 1. (1) TEM micrograph of nanocurcumin particles with approximate average size of 50 nm in diameter. (2) SEM micrograph of nanocurcumin loaded chitosan biofilm.

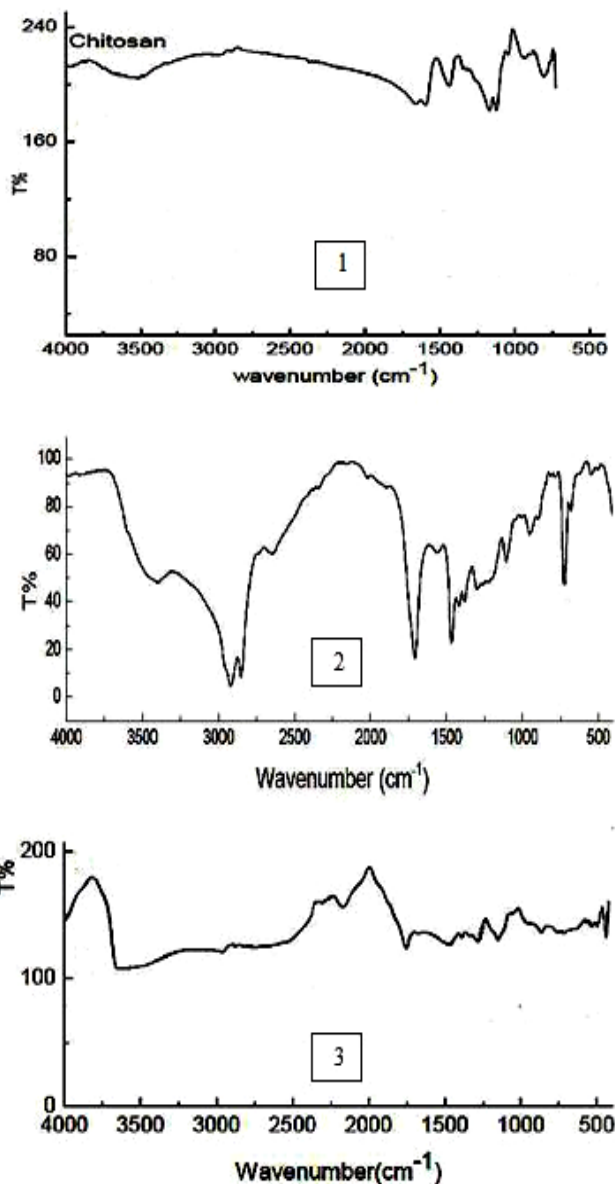


Figure 2. (1) FTIR spectrum of chitosan. (2) FTIR spectrum of curcumin nano particles. (3) FTIR spectrum of nanocurcumin loaded chitosan biofilm.

Table 1. Effects on circular excision wound contraction area (mm²). Values are given as mean \pm SEM.

Groups	Wound area in days (mm ²)					
	Day 6	Day 9	Day 12	Day 15	Day 18	Day 21
Group I	230.16 \pm 4.90	104.30 \pm 5.10	88.75 \pm 3.60	41.70 \pm 3.30	23.28 \pm 2.15	7.88 \pm 3.38
Group II	222.20 \pm 4.15	190.78 \pm 4.75	170.88 \pm 3.25	128.50 \pm 2.10	70.60 \pm 2.11	63.30 \pm 2.70
Group III	221.24 \pm 4.15	193.55 \pm 4.50	175.35 \pm 3.18	128.50 \pm 3.68	75.10 \pm 2.17	68.67 \pm 2.29
Group IV	101.10 \pm 3.12*	73.60 \pm 2.15*	33.75 \pm 2.25*	15.30 \pm 1.55*	5.50 \pm 0.75*	0.00 \pm 0.00*

The treated groups are compared by Student t-test with other groups. *: The mean difference was significant at the .05 level vs. groups II and III.

Table 2. Evaluation of Intensity of histological parameters in experimental groups.

Groups	Days	Acute Hemorrhage	Congestion	Vascularization	Epithelialization	Collagen
Group I	7	+++	+++	+	-	+
	14	++	+	++	+	++
	21	-	-	++	++	++
Group II	7	+++	+++	-	-	-
	14	+++	++	+	+	+
	21	++	++	+	+	+
Group III	7	+++	+++	-	+	+
	14	++	+	+	++	++
	21	+	+	+	++	++
Group IV	7	+*	+*	++*	++*	++*
	14	-	-	++*	++*	++*
	21	-	-	++++*	+++*	+++*

Classification of histological parameters according to the intensity of occurrence: - absence; + discrete; ++ moderate; +++ intense; ++++ very intense. Histopathological damages were assessed as explained under material and methods on days, 7, 14 and 21 of lesion. * P <0.05 vs. groups II and III.

4. Discussion

Wound healing process in diabetic patient is impaired and delayed due to high blood glucose levels. High blood glucose hampers proliferation of cells and decreases collagen production that result in decrease in chemotaxis and phagocytosis.²¹ Elevated blood glucose level, a reduction in the levels of growth factors, and the inhibition of fibroblast proliferation have all been suggested to contribute to the observed impairment in wound healing.²¹ STZ induced diabetes in rats is one of the most extensively studied models of diabetes. In this study, therefore, STZ induced diabetic rats were used as the model of diabetes to study diabetic wound healing.

Wound healing is characterized by reepithelialization, granulation tissue growth and remodeling of extracellular matrix. Although the wound healing process occurs by itself, spontaneously, and does not require much help, there are various risk factors such as infection, supply of blood, nutritional status and other factors that influence the resolution of this process.²²

Several reports have demonstrated a beneficial effect of chitosan as a biologically active dressing in wound management. It has been reported that the application of chitosan to the open wounds in dogs induced exudate, which has a high growth factor activity, and induced infiltration by inflammatory cells and granulation tissue formation accompanied by angiogenesis.²³⁻²⁵

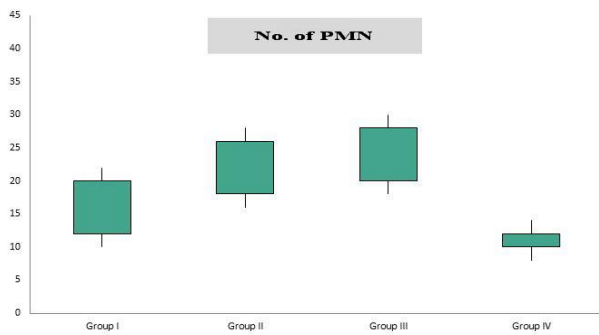


Figure 3. Box-and-whisker plots of number of polymorphonuclear cells (PMN) in excisional model of the rat's skin in experimental groups. Results were expressed as mean \pm SEM.

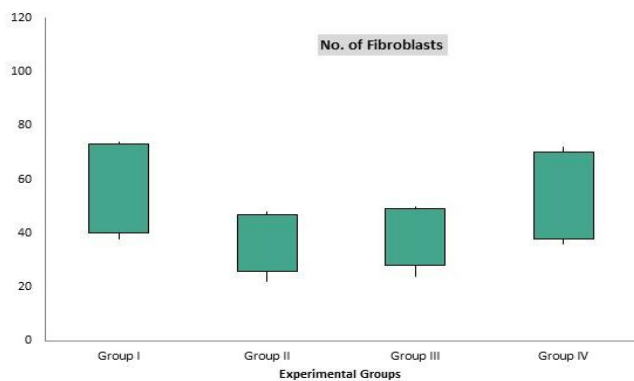


Figure 4. Box-and-whisker plots of number of fibroblasts in excisional model of the rat's skin in experimental groups. Results were expressed as mean \pm SEM.

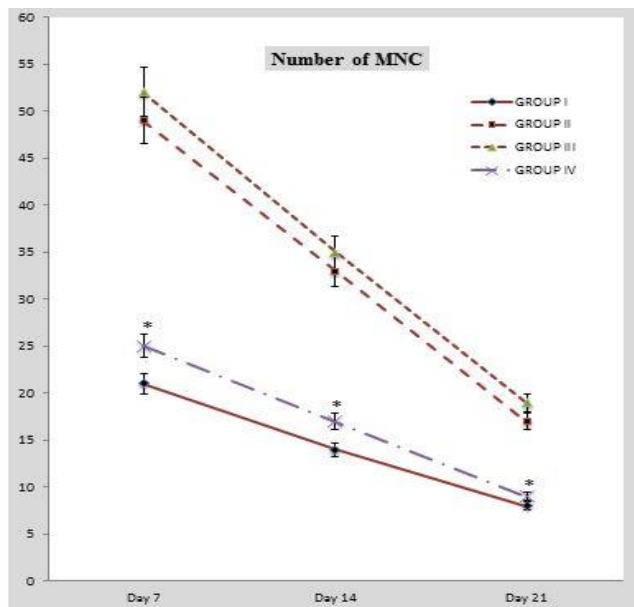


Figure 5. Line graph indicating number of mononuclear cells (MNC) in excisional model of the rat's skin in experimental groups. Results were expressed as mean \pm SEM. * $p < 0.05$ vs groups II and III.

Chitosan-membrane-based wound products have been investigated both in laboratory animals and humans, but are still at the early stage of development. Since 1980, chitosan and its derivatives have been used in skin and wound management products in Japan. Beschitin W, an artificial skin prepared from chitin threads, has been developed for human use and is on the market.^{26,27}

Various studies reveals that curcumin plays important role in formation of granulation tissue, neo-vascularization and a faster re-epithelialization of wound in both diabetic as well as hydrocortisone impaired wounds.²⁸ Curcumin scavenges the free radical effectively and reduces the oxidative stress. The decreased oxidative stress lowers the inflammatory response and inhibits the expression of transcription gene NF- κ B (nuclear transcription factor- κ B) by modulating through tumor necrosis factor.^{29,30} Curcumin also downregulates the expression of inflammatory mediators, cell surface adhesion molecules, and cyclin D1 which are important players of inflammatory and anti-inflammatory responses.³¹ Curcumin pretreatment enhances the synthesis of collagen, hexosamine, DNA, nitrite, and histologic assessment of wound biopsy specimens showed improved collagen deposition and an increase in fibroblast and vascular densities suggesting that curcumin may be able to improve radiation-induced delay in wound repair.³²

The inflammation phase is considered as a main step in order to eliminate cellular debris from tissue as well as extensive response for microbial infection.^{33,34} Therefore, rapid inflammatory response is necessary to control the inflammation. Neutrophils, macrophages and lymphocytes infiltrate to the site of injury during inflammatory stage.^{33,35} Light microscopic analyses showed that in group V mononuclear immune cell infiltration was significantly increased on day 8 post operation. This situation plays a critical role in eliminating the infection and provoking the healing process by considering the key role of inflammatory cells (especially macrophages) in organizing the granulation tissue. Therefore, the anti-inflammatory impact of nanocurcumin may largely correlates with these agents.

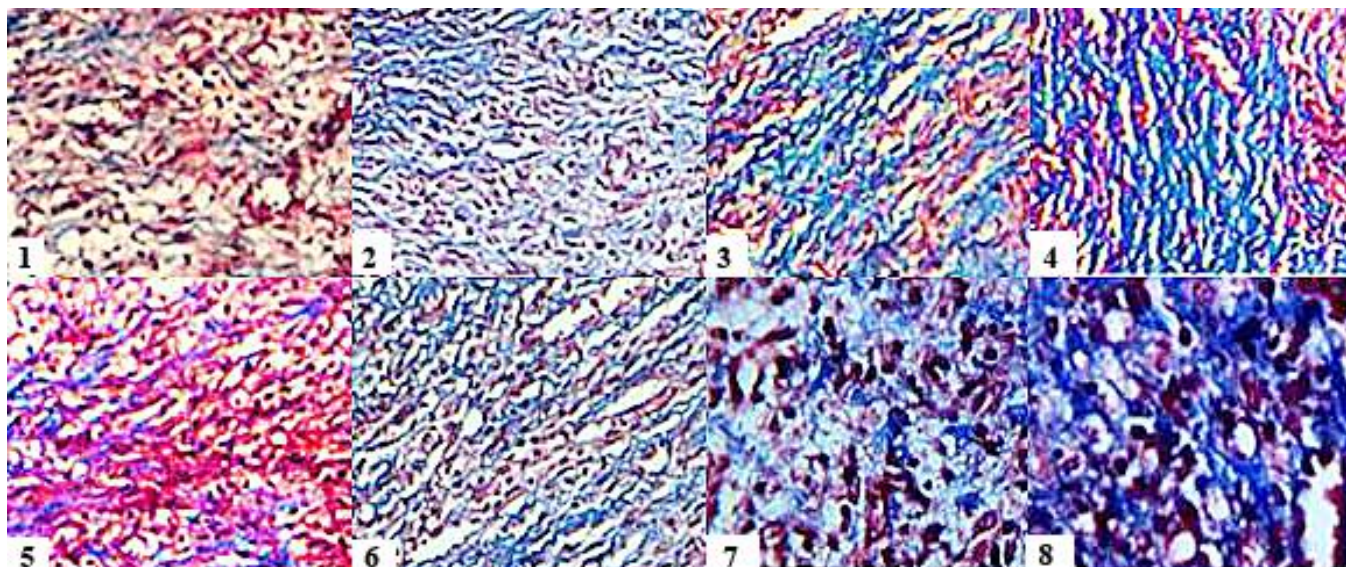


Figure 6. Histological characteristics of rat skin on the 7th (1-4) and 14th day (5-8) after wound creation in excisional wound model. 1 and 5: Group I, 2 and 6: Group II, 3 and 7: Group III, 4 and 8: Group IV. Wounds with surrounding skin were prepared for histological microscopic evaluation by Masson's trichrome staining ($\times 400$).

The observations of our study showed that chitosan nanocurcumin biofilm resulted in enhanced cellular proliferation. The fibroblasts and fibrocytes distribution in one mm² of the wound site was significantly higher in comparison with other groups. Regarding the key role of fibroblasts and fibrocytes in synthesis of collagen, we could hypothesize that elevated collagen deposition in group IV was attributed to high cellularity of fibroblasts and fibrocytes.

In excisional wound model there was a significant decrease in wound area. This indicated improved collagen maturation by increased cross linking. The balance between synthesis and breakdown and so deposition of collagen is important in wound healing and development of wound strength.^{36,37} Increase in hydroxyproline content in group IV indicated increased collagen content, since hydroxyproline is the direct estimate of collagen synthesis. The key point to end of the inflammation is the apoptotic activity of immune cells. Apoptosis is considered a vital component of various processes including normal cell turnover, proper development and functioning of the immune system, hormone-dependent atrophy, embryonic development, and chemical-induced cell death.³⁸ In the inflammation response, the mediators induce the

infiltration of activated immune cells into inflammation site to protect the tissue against the pathogen infection. In the end of the inflammation, apoptosis of the immune cells and the apoptotic cells are cleared by macrophages. The clearance by macrophages of cells apoptosis is a key point phenomenon associated with actively tissue formation from wound inflammation.³⁹⁻⁴¹ Thus, our results showed that chitosan nanocurcumin biofilm could improve healing of diabetic wounds.

Acknowledgments

We would like to thank Tabriz University of Medical Sciences for their technical help.

Conflict of Interests

None.

References

1. Venkatasubbu GD, Anusuya T. Investigation on Curcumin nanocomposite for wound dressing. *International Journal of Biological Macromolecules*, 2017; 98: 366-378.
2. Almeida SA, Salomé GM, Dutra, RAA, Ferreira LM. Feelings of powerlessness in individuals with either

- venous or diabetic foot ulcers. *Journal of Tissue Viability*, 2014; 23(3): 109-114.
3. Lee CH, Chang SH, Chen WJ, Hung KC, Lin YH, Liu SJ, Hsieh MJ, Pang JH, Juang JH. Augmentation of diabetic wound healing and enhancement of Collagen content using nanofibrous glucophage-loaded Collagen/PLGA scaffold membranes. *Journal of Colloid and Interface Science*, 2015; 439: 88–97
 4. Romero-Cerecero O, Zamilpa A, Díaz-García ER, Tortoriello J. Pharmacological effect of *Ageratina pichinchensis* on wound healing in diabetic rats and genotoxicity evaluation. *Journal of Ethnopharmacology*, 2014; 156: 222–227.
 5. Greenhalgh DG. Wound healing and diabetes mellitus. *Clinics in Plastic Surgery*, 2003; 30(1): 37-45.
 6. Kamar SS, Abdel-Kader DH, Rashed LA. Beneficial effect of Curcumin Nanoparticles-Hydrogel on excisional skin wound healing in type-I diabetic rat: Histological and immunohistochemical studies. *Annals of Anatomy*, 2019; 222: 94-102.
 7. Karri VV, Kuppusamy G, Talluri SV, Mannemala SS, Kollipara R, Wadhvani AD, Mulukutla S, Raju KR, Malayandi R. Curcumin loaded chitosan nanoparticles impregnated into collagen-alginate scaffolds for diabetic wound healing. *International Journal of Biological Macromolecules*, 2016; 93(Pt B): 1519-1529.
 8. Biagini G, Muzzarelli RAA, Giardiono R, Castaldini C. Biological material for wound healing. In: Brine CJ, Sanford PA, Zikakis JP, eds. *Advances in chitin and chitosan*. Elsevier, London, UK, 1992: 16–23.
 9. Muzzarelli RAA, Monica MB, Pugnali A, Biagini G. Biochemistry. Histology and clinical uses of chitins and chitosans in wound healing. In: Jolles P, Muzzarelli RAA, eds. *Chitin and chitinases*. Birkhauser Verlag, Basel, Switzerland; 1999: 251–264.
 10. Minami S, Okamoto Y, Tanioka S. Effects of chitosan on wound healing. In: Yalpani M, edr. *Carbohydrates and carbohydrate polymers*. ATL Press, Mount Prospect, IL, USA, 1992: 142-152.
 11. Minami S, Okamoto Y, Matsuhashi A, Sashiwa H, Saimoto Y, Shigemasa T, et al. Application of chitin and chitosan in small animals. In: Brine CJ, Sanford PA, Zikakis JP, eds. *Advances in chitin and chitosan*. Elsevier Applied Science, Landon and New York, 1992: 70–78.
 12. Rouhollahi E, Moghadamtousi SZ, Hajiaghaalipour F, Zahedifard M, Tayeby F, Awang K, Abdulla MA, Mohamed Z. Curcuma purpurascens BI. rhizome accelerates rat excisional wound healing: involvement of Hsp70/Bax proteins, antioxidant defense, and angiogenesis activity. *Drug Design, Development and Therapy*, 2015; 9: 5805-5813.
 13. Pizzo P, Scapin C, Vitadello M, Florean C, Gorza L. Grp 94 acts as a mediator of curcumin-induced antioxidant defence in myogenic cells. *Journal of Cellular and Molecular Medicine*, 2010; 14(4): 970–981.
 14. Aggarwal B B, Harikumar KB. Potential therapeutic effects of curcumin: the anti-inflammatory agent against neurodegenerative cardiovascular, pulmonary, metabolic, autoimmune and neoplastic diseases. *International Journal of Biochemistry & Cell Biology*, 2009; 41(1): 40-59.
 15. Wang Y, Lu Z, Wu H, Lv F. Study on the antibiotic activity of microcapsule curcumin against foodborne pathogens. *International Journal of Food Microbiology*, 2009; 136(1): 71-74.
 16. Jovanovic SV, Boone CW, Steenken S, Trinoga M, Kaskey RB. How curcumin works preferentially with water-soluble antioxidants. *Journal of the American Chemical Society*, 2001; 123(13): 3064–3068.
 17. Tejada S, Manayi A, Daglia M, Nabavi S, Sureda A, Hajheydari Z, Gortzi O, Pazoki-Toroudi H, M Nabavi S. Wound healing effects of curcumin: A short review. *Current Pharmaceutical Biotechnology*, 2016; 17(11): 1002-1007.
 18. Flora G, Gupta D, Tiwari A. Curcumin nanoparticles: a promising therapeutic advancement over native curcumin. *Critical Reviews in Therapeutic Drug Carrier Systems*, 2013; 30(4):331- 368.
 19. Kamel NA, Soliman AAF, Rozik NN, Abd-Elmessieh SL. Biophysical investigation of curcumin based nanocomposite for wound dressing application. *Journal of Applied Pharmaceutical Science*. 2018; 8(05): 35-44
 20. Zimmermann M. Ethical guidelines for investigations of experimental pain in conscious animals. *Pain*, 1983; 16: 109-110.
 21. Gonçalves RV, Novaes RD, Sarandy MM, Damasceno EM, da Matta SL, de Gouveia NM, Freitas MB, Espindola FS. 5 α -Dihydrotestosterone enhances wound healing in diabetic rats. *Life Sciences*, 2016; 152: 67-75.
 22. Peters EJ, Lipsky BA. Diagnosis and management of infection in the diabetic foot. *Medical Clinics of North America*, 2013; 97(5): 911-946
 23. Okamoto Y, Sibazaki K, Minami S, Matsuhashi A, Tanioka S, Shigemasa Y. Evaluation of chitin and chitosan on open wound healing in dogs. *Journal of*

- Veterinary Medical Science*, 1995; 57: 851–854.
24. Okamoto Y, Tomita T, Minami S, Matsuhashi A, Kumazawa NH, Tanioka SI, Shigemasa Y. Effects of chitosan on experimental abscess with *Staphylococcus aureus* in dogs. *Journal of Veterinary Medical Science*, 1995; 57(4): 765-767.
 25. Mizuno K, Yamamura K, Yano K, Osada T, Saeki S, Takimoto N, Sakurai T, Nimura Y. Effect of chitosan film containing basic fibroblast growth factor on wound healing in genetically diabetic mice. *Journal of Biomedical Materials Research Part A*, 2003; 64(1): 177-181.
 26. Koji K. Clinical application of chitin artificial skin (Beschitin W). In: Brine CJ, Sanford PA, Zikakis JP, eds. *Advances in chitin and chitosan*. Elsevier Applied Science, Landon and New York, 1992: 9-15.
 27. Azad AK, Sermsintham N, Chandkrachang S, Stevens WF. Chitosan membrane as a wound-healing dressing: characterization and clinical application. *Journal of Biomedical Materials Research Part B*, 2004; 69: 216-222.
 28. Prasad R, Kumar D, Kant V, Tandan SK, Dinesh Kumar. Curcumin enhanced cutaneous wound healing by modulating cytokines and transforming growth factor in excision wound model in rats. *International Journal of Current Microbiology and Applied Sciences*, 2017(7): 2263-2273.
 29. Bharti AC, Donaton N, Singh S, Aggarwal BB. Curcumin (diferuloylmethane) down-regulates the constitutive activation of nuclear factor-kappa B & I kappa B alpha kinase in human multiple myeloma cells, leading to suppression of proliferation and induction of apoptosis. *Blood*, 2003; 101(3): 1053–1062.
 30. Aggarwal BB. Signalling pathways of the TNF superfamily: a double-edged sword. *Nature Reviews Immunology*, 2003; 3: 745–756.
 31. Aggarwal BB, Shishodia S. Suppression of the nuclear factor-kappa B activation pathway by spice-derived phytochemicals: reasoning for seasoning. *Annals of the New York Academy of Sciences*, 2004; 1030: 434-441
 32. Jagetia GC, Rajanikant GK. Curcumin treatment enhances the repair and regeneration of wounds in mice exposed to hemibody gamma irradiation. *Plastic and Reconstructive Surgery*, 2005; 115(2): 515–528.
 33. Berridge MJ. Cell Stress, Inflammatory Responses and Cell Death. *Cellular Signaling and Biology*, 2014;2-14(1):1-30.
 34. Boyce ST, Lalley AL. Tissue engineering of skin and regenerative medicine for wound care. *Burns and Trauma*, 2018; 6: 4.
 35. Rodero M, Khosrotehrani K. Skin wound healing modulation by macrophages. *International Journal of Clinical and Experimental Pathology*, 2010; 3(7): 643–653.
 36. Mehrtash M, Mohammadi R, Hobbenaghi R. Effect of adipose derived nucleated cell fractions with chitosan biodegradable film on wound healing in rats. *Wound Medicine*, 2015; 10-11: 1-8
 37. Siamak Kazemi-Darabadi; Ghasem Akbari; Seyed-Hossein Jarolmasjed; Amir-Ali Shahbazfar. A Histopathologic Study of Effects of Olive Oil Plus Lime Water on Third-Degree Burn in Mouse Model. *Iranian Journal of Veterinary Surgery*, 2017; 12(1): 55-63.
 38. Elmore S. Apoptosis: a review of programmed cell death. *Toxicologic Pathology*, 2007; 35(4): 495-516.
 39. Wu YS, Chen SN. Apoptotic cell: linkage of inflammation and wound healing. *Frontiers in Pharmacology*, 2014; 5: 1.
 40. Rostami H, Mohammadi R, Asri-Rezaei S, Tehrani AA. Evaluation of application of chitosan/nano sodium selenite biodegradable film on full thickness excisional wound healing in rats. *Iranian Journal of Veterinary Surgery*, 2018; 13(1): 15-24.
 41. Shabrandi A, Azizi S, Hobbenaghi R, Ownagh A, Keshipour S. The healing effect of chitosan supported nano-CeO₂ on experimental excisional wound infected with *Pseudomonas aeruginosa* in rat. *Iranian Journal of Veterinary Surgery*, 2017; 12(2): 9-20.