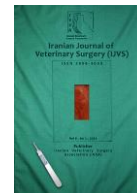



Iranian Veterinary Surgery Association

IRANIAN JOURNAL OF VETERINARY SURGERY

Journal homepage: www.ivsajournals.com

Clinical Report

Umbilical Hernia with Extensive Adhesion and Evisceration in a Bovine Calf

Pravin Mishra¹, Md. Muket Mahmud², Vivek Kumar Yadav³, Moinul Hasan^{1*}

¹ Department of Surgery and Obstetrics, Faculty of Veterinary Science, Bangladesh Agricultural University, Mymensingh.

² Department of Microbiology and Hygiene, Faculty of Veterinary Science, Bangladesh Agricultural University, Mymensingh.

³ Faculty of Veterinary Science, Bangladesh Agricultural University, Mymensingh.

Received: 20 October 2019

Accepted: 27 January 2020

Online: 27 January 2020

Keywords:

Calf;

Umbilical hernia;

Adhesion;

Evisceration;

Electrocauterization.

Abstract

Case Description- Umbilical hernia is occasionally seen with different levels of complexity in animals. This emergency condition requires quick diagnosis and is corrected with various surgical approaches. The aim of this paper is to report the surgical correction of an eviscerated umbilical hernia with extensive adhesion in a bovine calf. Twenty days old indigenous male bovine calf was presented for surgical treatment of an umbilical hernia with extensive adhesion and evisceration.

Clinical Findings- Physical examination through palpation revealed evisceration of umbilical content with extensive adhesion.

Treatment and Outcome- The surgical procedure was carried out aseptically following standard procedure. The bovine calf recovered without any complication two weeks after surgery.

Clinical Relevance- It can be concluded that surgical management along with administration of antibiotic, antihistaminic and anti-inflammatory drugs are effective for successful management of eviscerated umbilical hernia with extensive adhesion in the bovine calf.

* Correspondence to: Moinul Hasan; Department of Surgery and Obstetrics, Faculty of Veterinary Science, Bangladesh Agricultural University, Mymensingh. E-mail: moinul.vet@bau.edu.bd



1. Introduction

A hernia is the abnormal exit of tissue or an organ, such as the bowel, through the wall of the cavity in which it normally resides.¹ Congenital ventro-abdominal imperfections are quite common in neonatal calves.² The reasons for defective closure of ventro-abdominal mid-line wall with protrusion of abdominal viscera are faulty development of somatopleura and inappropriate closure of umbilical opening at birth. Moreover, permanent ventral abdominal wall defect results from hypoplasia of abdominal muscles.³ Umbilical hernia is one of the major congenital disorders causing mortality in calves.⁴ There are several reports with different approaches used to correct umbilical hernias.⁶ Umbilical hernia can be surgically corrected mainly through two techniques, namely hernioplasty and herniorrhaphy. But, recurrence is common after herniorrhaphy and seen throughout the year.⁷ Emergency surgery is performed in the presence of complications such as obstruction, strangulation, and evisceration. We report a case of umbilical hernia with extensive adhesion and evisceration in a bovine calf and correction approach used successfully.

2. Case Description and Clinical Findings

Twenty days old indigenous male bovine calf was brought to Veterinary Teaching Hospital, Bangladesh Agricultural University, Mymensingh, Bangladesh having body weight

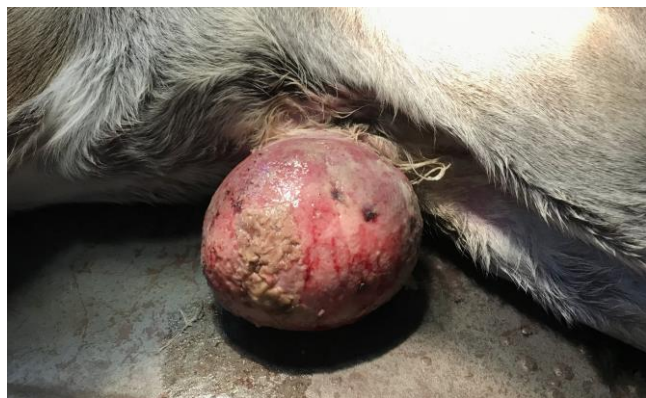

Figure 1. Evisceration of umbilical content with extensive adhesion

40 kg with the complaint of umbilical hernia. Physical examination through palpation revealed evisceration of umbilical content with extensive adhesion (Figure 1). Umbilical herniorrhaphy was recommended for the treatment of this condition. Rectal temperature (38.3° C), pulse rate (70/min) and respiration rate (30/min) were recorded before surgery.

3. Treatment and Outcome

The animal was prepared as routine for surgery and kept in dorsoventral position. The calf received 0.30 mg/kg 5% dextrose saline (ACME Laboratories Ltd. Bangladesh) intravenously. Xylazine (Xylaxin, Indian Immunologicals Ltd., India) was injected intramuscularly IM (0.1 mg/kg BW) for sedation and atropine sulphate (Atropine Sulphate Vet, Chemist Laboratories Ltd., Bangladesh) was injected (0.05 mg/kg body weight, BW) (IM) to control salivation. Later, local infiltration of 2% lidocaine hydrochloride (Jasocaine, Jayson Pharmaceuticals Ltd., Bangladesh) was done for local analgesia in an inverted V shaped pattern from cranial to caudal aspect of hernial ring.

The surgical area was shaved, scrubbed with Povidone Iodine 10% (Povisep, Jayson Pharmaceuticals Ltd., Bangladesh) and draped. The surgical site was then painted with sterile gauze soaked in tincture iodine for the skin scrub. Electrocauterizer was used to incise the eviscerated part of umbilical hernia containing parts of small intestine. The eviscerated part of small intestine was introduced back into the abdominal cavity through digital manipulation. Bleeding were checked using artery forceps and electrocauterizer. The ring was closed by placing a series of overlapping Mayo-mattress sutures through its edges using No. 1-0 polyglactin 910 (Vicryl, Ethicon, Johnson and Johnson Private Limited, India). Muscles were sutured using chromic No. 1-0 catgut (Mersutures, Catgut Ethicon, Johnson and Johnson Private Limited, India) with simple continuous suture pattern. The skin flaps were apposed by simple interrupted suture pattern using No. 1 nylon

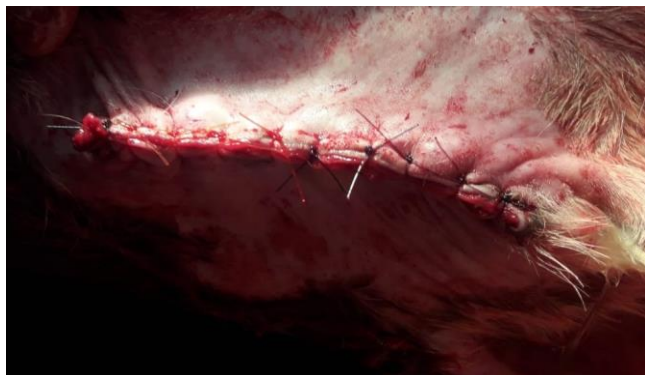


Figure 2. Apposition of skin using nylon by simple interrupted suture

(Ethilon, monofilament polyamide, Johnson and Johnson Private Limited, India) (Figure 2).

Antibiotic preparation, ampicillin (Ampicin Vet, Square pharmaceuticals Ltd., Bangladesh) was given IM (15 mg/kg BW) twice daily for 5 days. Antihistaminic preparation, pheniramine maleate (Asta Vet, ACME Laboratories Ltd., Bangladesh) was administered IM (1 mg/kg BW) once daily for 3 days and ketoprofen (Ketovet, Techno Drugs Ltd., Bangladesh) was administered IM (3 mg/kg BW) once daily for 3 days as anti-inflammatory medication.

4. Clinical Relevance

In evisceration, the hernial contents, mostly intestine, break through the skin overlying the sac and come into direct contact with the external environment.⁵ Evisceration of intestine may occur spontaneously after gradual worsening of the hernia and thinning of the wall or it may be abrupt caused by trauma or sudden straining.⁸ Evisceration is an emergency disorder necessitating prompt diagnosis and surgical treatment for the survivability of the affected calf.² In this case study, the calf recovered successfully without any complications after two weeks of surgery. The prognosis of surgical intervention with intestinal evisceration in calves is good.² In the present case, clinical parameters (rectal temperature, pulse rate and respiration rate) were found normal which indicated the normal physiological condition of the calf. The case was found in

a male bovine calf. Jaman *et al.* reported that the condition is more prevalent in neonatal male calves.⁷ However, Prasad *et al* found more cases in female calves.² Various literatures stated the causes of this type of affection which are mainly of two types; congenital and acquired.⁹⁻¹¹ In our case the reason of this might be congenital as this was seen from its birth time and no evidence of any injury was present.

It can be concluded that surgical management along with administration of antibiotic, antihistamine and anti-inflammatory medication are effective for successful management of eviscerated umbilical hernia with extensive adhesion in bovine calves.

Acknowledgment

We thank the supporting staff of Veterinary Teaching Hospital of Bangladesh Agricultural University, Mymensingh for their technical helps during surgical procedures and Rajesh Jha, PhD, Associate Professor of Animal Nutrition, University of Hawaii at Manoa, USA for linguistic corrections.

Conflict of Interests

The author does not have any conflict of interest.

References

1. Fitzgibbons RJ, Jr Forse RA. Clinical practice. Groin hernias in adults. *The New England Journal of Medicine*, 2015; 372(8): 756–763.
2. Prasad CK, Maruthi ST, Sagar RS, Belakeri P, Mahantesh MT. Surgical management of intestinal evisceration in neonatal calves. *Intas Polivet*, 2017; 18(2): 346-347.
3. Sharda R, Tiwari SK, Naik N. Intestinal evisceration in a cow calf and its surgical management. *Intas Polivet*, 2012; 13: 44-45.
4. Nath SK, Sen AB, Rahman MM, Das S, Ersam R, Alam MR. Umbilical hernia in calves in Sylhet region. *International Journal of Advanced Multidisciplinary Research*, 2016; 3(7): 19–25.
5. Arora E, Gandhi S, Bhandarwar A, Quraishi AH, Wagh A, Tandur A, Wakle D. Umbilical hernia with

- evisceration. Two cases and a review of the literature. *The Journal of Emergency Medicine*, 2018; 55(2): e27-31.
6. Rahman MM, Sultana S, Ali MZ. Prevalence of umbilical hernia of calves and its risk factors at Tangail Sadar of Bangladesh. *Asian-Australasian Journal of Bioscience and Biotechnology*, 2017; 2(2): 154-158.
 7. Jaman MM, Mishra P, Rahman M, Alam MM. Clinical and laboratory investigation on the recurrence of the umbilical hernia after herniorrhaphy in bovine calves. *Journal of the Bangladesh Agricultural University*, 2018; 16(3): 464-470.
 8. Good DW, Royds JE, Smith MJ, Neary PC, Eguare E. Umbilical hernia rupture with evisceration of omentum from massive ascites: a case report. *Journal of Medical Case Reports*, 2011; 5(1): 170.
 9. Farman RH, Al-Husseiny SH, Al-Ameer AN. Surgical treatment of hernia in cattle: A review. *Al-Qadisiyah Journal of Veterinary Medicine Sciences*, 2018; 17(2): 61-68.
 10. Inguinal Hernias: Causes, Types, Repair & Surgery Options Website. HealthEngine. Available At: <https://healthengine.com.au/info/hernia-repair>. Accessed Dec 13, 2018.
 11. Van Wesseem KJP, Simons MP, Plaisier PW, Lange JF. The etiology of indirect inguinal hernias: congenital and/or acquired? *Hernia*, 2003; 7(2): 76-79.