



Radiographic Measurement of Vertebral Heart Scale (VHS) in New Zealand White Rabbits

Abdolvahed Moarabi, Bahman Mosallanejad*, Alireza Ghadiri, Reza Avizeh

Abstract

Objective- The aim of the present survey was to evaluate whether the results of cardiac measurements using the VHS are a useful indicator of the origin of normal rabbits.

Design- Experimental study.

Animals- Forty seven adult healthy New Zealand White rabbits (25 male, 22 female) with age 10-18 months and weight 1.5-2.5 Kg.

Procedures- To assess the influence of breed on the vertebral heart scale of rabbits, the VHS was measured and compared on left to right and right to left lateral views. Lengths of the long and short axis were determined with a ruler in millimeters. The dimensions were scaled against the length of the vertebrae beginning with the fourth thoracic vertebra.

Results- Mean \pm SD long axis dimensions were 4.3 ± 0.30 vertebrae and mean \pm SD short axis dimensions 3.1 ± 0.32 vertebrae. The VHS was 7.6 ± 0.32 vertebrae (mean \pm SD) on right-to-left lateral and 7.3 ± 0.31 vertebrae on left-to-right lateral radiographs. The obtained VHS on right to left lateral views were larger than left to right lateral radiographs, nevertheless no significant differences were observed in RL-long axis and RL-vertebral heart size ($P > 0.05$).

Conclusion and Clinical Relevance- The vertebral heart scale method is easy to use and objective for clinical practice. The obtained data showed that the long axis and short axis of the heart had not significantly different in male and female rabbits together. Also, no significant changes were observed according to age. These values are useful as new diagnostic indices for cardiac disease in rabbits.

Key Words- New Zealand white, Rabbit, Vertebral heart scale (VHS).

Introduction

The companion rabbits (*Oryctolagus cuniculus*) are increasing in popularity as a pet in Iran. Cardiac diseases are highly emergent events among exotic animals, special in companion rabbits.¹ As in other pet species, diagnosis of cardiac disease is made using a combination of history, physical examination findings and diagnostic testing, usually including thoracic radiography.¹ Imaging studies are important for definitive diagnosis before treatment in small animals particular rabbits.¹ Chest radiography is easier to perform than echocardiography in many animals such as dog and cat.² Cardiac size are evaluated primarily using vertebral heart size (VHS) as reported in dogs and many other animals.^{1,2}

However, while some reports have described the evaluation of cardiac size using VHS in cross breeds of rabbit³, none have provided information for New Zealand White rabbits. Different methods have been developed to evaluate the animal's cardiac silhouette on thoracic radiographs. Comparison of the cardiac silhouette with previous radiographs of the same animal or with radiographs of an animal of the same breed and size can be inaccurate when made by inexperienced observers.⁴ A frequently used tool to quantify cardiac size is the vertebral heart size (VHS), which is based on the strong correlation between heart weight and body length in cats.^{2,3} Radiological evaluation of the exotic animal thorax is one of the most important and frequently performed diagnostic tests in small animal practice.^{1,5} Important information about heart disease is often obtained from thoracic radiographs. Domestic rabbits vary in size based on sex, neutering status, age and time of year.¹ There are more variations in the normal canine heart than in any other organ, and the heart is inherently variable in size because of its

Department of Clinical Sciences, College of Veterinary Medicine, Shahid Chamran University of Ahvaz, Ahvaz, Iran.

Address all correspondence to Bahman Mosallanejad (DVM, DVSc)

E-mail: bmosallanejad@scu.ac.ir

contractility during the cardiac cycle. Additionally, there is considerable breed variation with regards to normal heart size and shape in different species.^{4,6} Thoracic radiographs are very helpful in the diagnosis of heart disease and provide information available with any other modalities. The vertebral heart scale is a method for objectively evaluating the dimensions of the cardiac silhouette in thoracic radiographs. Using this method, the cardiac long and short axes are measured on the lateral thoracic view and are then compared with the thoracic spine. The VHS is the vertebral scale sum of the long and short axes, each measured caudally from the cranial edge of the 4th thoracic vertebra.⁷ Normal VHS values have been established for cats^{8,9} and ferrets¹⁰ as well as for different canine breeds.^{4, 6, 11, 12} The aim of the present study was to identify relational expressions that can be used in diagnosing cardiac disorders in rabbits. The obtained results will be a useful indicator for the origin of normal rabbits, so we attempted to determine standard cardiac dimensions in this breed of rabbits with using of VHS.

Materials and Methods

Forty seven adult healthy rabbits were selected for the study from New Zealand breed (25male, 22female). The healthy rabbits were 10-18 month old (mean, 15 month), and weighed between 1.5-2.5 kg (mean, 2.1 kg). The rabbits were privately owned and had normal cardiovascular examinations based on history, physical examination, auscultation and electrocardiogram. The rabbits were anesthetized with intramuscular ketamine (20 mg/kg) and acepromazine (0.02 mg/kg).¹⁰ Radiographs were taken during inspiration.¹ The radiographic examinations included left lateral (LL) and right lateral (RL) recumbency views. In lateral radiographs of rabbits, the cardiac long axis was measured from the ventral border of the left main stem bronchus to the cardiac apex in centimeter. Measurement was made with a standard caliper on each of the radiographs using the method described by Buchanan and Bucheler.² The radiographs were analyzed independently by each author, and the results tabulated. The caliper was then repositioned over the thoracic vertebrae, and the distance from the cranial

edge of fourth thoracic vertebra (T4) was measured caudally. The distance of the caudal caliper point was estimated to the nearest 0.1 centimeter. The short axis was measured at the level of the dorsal border of the caudal vena cava to reflect left atrium. The measurements of the long and short axes were recorded in terms of the numbers of vertebrae covered and the two numbers were then added together to give the value of the VHS in each RL and LL views (Fig.1 and 2). Radiographs were surveyed by only person.

Statistical analysis

All statistical analyses were performed using SPSS version 16 software package. For all measurements, the mean± standard deviations (SD) were calculated. For all animals, a paired t-test was used to determine differences between mean averages of the LVHS (left vertebral heart scale) to RVHS (right vertebral heart scale) views, RVHS and LVHS of two sexes (male and female), as separated tests and pearson correlation test to find relationship between sex and measurement of LVHS and RVHS. For all statistical test, values of p<0.05 were considered significant.

Results

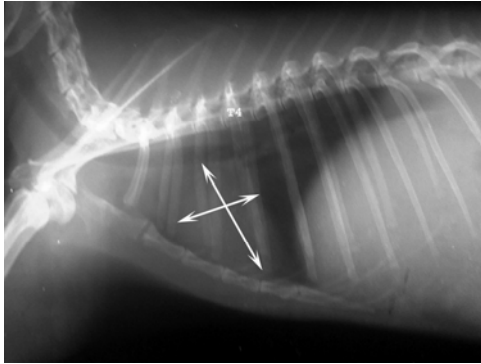
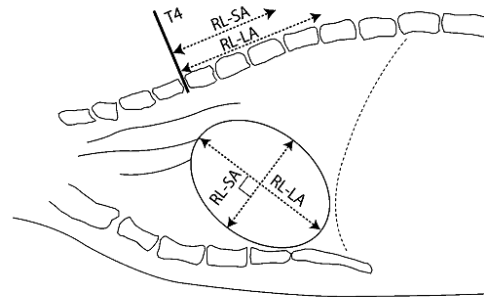
The sum of the long and short axis of the heart (VHS) was compared with the number of vertebrae (T4) in New Zealand rabbits. Distribution of VHS range was 6.9 to 7.8 vertebrae (Fig 1 and 2). The mean± SD of short axes were 3.1 ± 0.32 vertebrae and the mean ± SD of long axes were 4.3 ± 0.30 vertebrae. VHS in females was (7.3 ± 0.31 in LR, and 6.9 ± 0.28 in RL) and in males was (7.8 ± 0.33 in LR, and 7.4 ± 0.34). In this study, the size of the heart takes up space in the chest was also compared. The value obtained is 2 -2.5 intercostal space. No significant difference was found between males and females. Also in this study no significant changes were observed according to age. The mean age of females (1.3 years) was lower than that of males (1.4 years). Mean weight of females was 2.1 kg versus 1.8 kg for males. The mean age of females and males was equal (1.35 years).

Table 1- Radiographic measurements divided by gender in New Zealand White Rabbits (Left to right)

Measurement	VHS (mm)	Long axis (mm)	Short axis (mm)
	mean±SD	mean±SD	mean±SD
Male	7.8±0.33	4.5±0.23	3.3±0.30
Female	7.3±0.31	4.2±0.27	3.1±0.32
Male and Female	7.6±0.32	4.3±0.30	3.2±0.25

Table 2- Radiographic measurements divided by gender in New Zealand White Rabbits (Right to left)

Measurement	VHS (mm)	Long axis (mm)	Short axis (mm)
	mean±SD	mean±SD	mean±SD
Male	7.4±0.34	4.2±0.30	3.2±0.32
Female	6.9±0.28	3.9±0.29	3.0±0.22
Male and Female	7.3±0.31	4.16±0.32	3.1±0.31

**Figure 1-** Right lateral position (RL) radiographic view of a normal thorax.**Figure 2-** Right lateral position (RL) radiographic view of a normal rabbit thorax. LA: long axis; SA: short axis; VHS= LA+SA.

Discussion

In veterinary medicine determination of heart size is important in evaluating patients with heart disease. In this study heart sizes were compared with thoracic vertebrae in 47 clinically normal rabbits (New Zealand breed) without thoracic radiographic abnormalities. It was aimed to determine the heart sizes of rabbits according the vertebral heart size (VHS). The VHS is a method for objectively determining the size of the canine cardiac silhouette on thoracic radiographs.^{4,11,12} This technique is particularly useful for evaluating the cardiac enlargement associated with eccentric hypertrophy due to volume overload.^{13,14} It is easy to perform, and the measurements are relatively independent of both patient related (i.e., thoracic conformation, gender and side of lateral recumbency).³ Little reports have described cardiomyopathy, valvulopathy, endocarditis and ventricular septal defect among cardiac diseases in rabbits, and these diseases have been evaluated by auscultation of heart murmurs, echocardiography, or electrocardiography.^{1,3} Since the rabbit has a narrow thoracic cavity compared with other mammals and a large heart relative to the thoracic cavity even in a normal state, special evaluation criteria are necessary. In particular, chest radiography provides important information concerning cardiac dilation. In rabbits, evaluation criteria based on VHS as a common index of cardiac dilation have yet to determined,

enhancing the clinical significance of this study. Onuma et al. with study on 27 rabbits, observed significant differences ($P<0.05$) in RL-long axis (RL-LA) and RL-vertebral heart size (RL-VHS). RL-LA was 4.22 ± 0.25 and 4.48 ± 0.3 , and RL-VHS was 7.55 ± 0.38 and 7.99 ± 0.58 vertebrae, in the <1.6 kg ($n=12$) and >1.6 kg ($n=15$) groups, respectively.³ Stepien et al. showed that ventrodorsal views were larger than corresponding measurements in lateral views.¹⁰ Weight and most absolute measurements differed significantly between male and female ferret ($P<0.05$), but the differences in absolute measurements were not apparent when related to measures of body size (Ratio and modified VHS methods).¹⁰ A significant difference was also found between right-to-left (left lateral recumbency) and left-to-right lateral (right lateral recumbency) radiographs, with a larger VHS on left-to-right lateral views.³ In our study, the mean VHS of all groups of rabbits (male and female) on the left to right lateral radiographs were 7.3 ± 0.3 and for right to left lateral were measured 7.6 ± 0.3 vertebrae. As well as, for all rabbits, the mean VHS on right to left lateral radiographs had not significant difference compared with the mean VHS in left to right radiographs. We think that in clinical practice the lateral radiographic position may be preferred to the VD position, because the lateral radiographic position is more comfortable and causes less stress for the patients with suspected cardiac disease. It can be due to their particular cecum.

Various reports in cats and dogs have suggested that relating absolute cardiac measurements to a thoracic feature reflective of body size would minimize false positive diagnoses of cardiomegaly related to body size or magnification of the radiographic image.^{15,16,17} The mean VHS in dogs of Whippet breed on lateral radiographs was significantly larger than the VHS reported by Buchanan and Bucheler.⁶ Rabbit thoracic cavity morphology is fairly consistent, but the body weight of intact rabbits can vary depending on sex, time of year and breeding status.³ Due to the divergent X-ray beam and the left-sided position of the heart within the thorax, the degree of enlargement of the cardiac silhouette is always larger on left-to-right lateral than on right-to-left lateral radiographs.⁶ The degree of enlargement also depends on the relation between the distances from tube to object and object to film.⁶ Gravity and tilting of the heart within the thorax due to different recumbent positions also influence the cardiac silhouette.¹³ In this study, distribution of VHS range was 5.5 to 6.9 vertebrae. The mean \pm SD of short axes were 2.3 ± 0.32 vertebrae and the mean \pm SD of long axes were 4.3 ± 0.30 vertebrae. VHS was 7.3 ± 0.31 in

females and 7.8 ± 0.33 vertebrae in males. As observed above, among the measured items, RL-VHS in particular should be added as a new item of measurement for predicting cardiac function in rabbits, as well as in other animals. In this study rabbit heart size were compared with intercostals space. The values obtained in male and female rabbits 2 to 2.5 intercostal spaces, respectively. In conclusion, the obtained data showed that the long axis and short axis of the heart had not significantly different in male and female rabbits together. Also, no significant changes were observed according to age. The results are a prelude for future studies.

Acknowledgements

We would like to mention the greatly appreciation of Research Council of Shahid Chamran University of Ahvaz for the financial support.

References

1. Harcourt-Brown F. Textbook of Rabbit Medicine. Butterworth-Heinemann, 2002; 335-348.
2. Buchanan JW, Bucheler J. Vertebral scale system to measure canine heart size in radiographs. *J Am Vet Med Assoc* 1995; 206: 194–199.
3. Onuma M, Ono S, Ishida T, et al. Radiographic measurement of cardiac size in 27 rabbits. *J Vet Med Sci* 2010; 72: 529-531.
4. Lamb CR, Tyler M, Boswood A, et al. Assessment of the value of the vertebral heart scale in the radiographic diagnosis of cardiac diseases in dogs. *Vet Rec* 2000; 146: 687–690.
5. Nakayama H, Nakayama T, Hamlin RL. Correlation of cardiac enlargement as assessed by vertebral heart size and echocardiographic and electrocardiographic findings in dogs with evolving cardiomegaly due to rapid ventricular pacing. *J Vet Intern Med* 2001; 15: 217–221.
6. Bavegems V, Van AC, Duchateau L, et al. Vertebral heart size ranges specific for Whippets. *Vet Radiol Ultrasound* 2005; 46: 400–403.
7. Buchanan JW. Vertebral scale system to measure heart size in radiographs. *Vet Clin N Am Small Anim Pract* 2000; 30: 379–393.
8. Ghadiri A, Avizeh R, Fazli Gh. Vertebral heart scale of common large breeds of dogs in Iran. *Int J Vet Res* 2010; 4: 107-111.
9. Litster AL, Buchanan JW. Vertebral scale system to measure heart size in radiographs of cats. *J Am Vet Med Assoc* 2000; 216: 210–214.
10. Stepien RL, Benson KG, Forrest LJ. Radiographic measurement of cardiac size in normal ferrets. *Vet Radiol Ultrasound* 1999; 40: 606-610.
11. Lamb CR, Wikeley H, Boswood A, et al. Use of breed-specific ranges for the vertebral scale as an aid to the radiographic diagnosis of cardiac diseases in dogs. *Vet Rec* 2001; 148: 707–711.
12. Marin LM, Brown J, McBrien C, et al. Vertebral heart size in retired racing greyhounds. *Vet Radiol Ultrasound* 2007; 48: 332–334.
13. Owens JM, Biery DN. Radiographic interpretation for the small animal clinician. 2 nd edition . Williams and Wilkins Company 1999: 190.
14. Root CR, Bahr RJ. The heart and great vessels in Textbook of diagnostic veterinary radiology, Thrall DE 4th edition. W.B. Saunders Company, Philadelphia, 2002; 402-419.
15. Suter PF, Lord PF. Thoracic radiography: A text atlas of thoracic diseases of the dog and cat. Wettswil, Switzerland 1984.
16. Toal RL, Losonsky JM, Coulter DB, et al. Influence of cardiac cycle on the radiographic appearance of the feline heart. *Vet Radiol* 1985; 26: 63-69.
17. Toombs JP, Ogburn PN. Evaluation canine cardiovascular silhouettes: radiographic methods and normal radiographic anatomy. *Compend Contin Edu Pract Vet* 1985; 7: 579-587.

چکیده

اندازه‌گیری شاخص‌های رادیوگرافی قلب بر اساس مقیاس مهره‌ای (VHS) در خرگوش‌های سفید نیوزیلندی

عبدالواحد معربی، بهمن مصلی‌نژاد^{*}، علیرضا غدیری، رضا آویزه

گروه علوم درمانگاهی، دانشکده دامپزشکی، دانشگاه شهید چمران اهواز، اهواز، ایران.

هدف- هدف از انجام تحقیق حاضر، ارزیابی نتایج حاصل از اندازه‌گیری‌های قلبی بر اساس VHS است که می‌تواند بعنوان یک شاخص مناسب برای خرگوش‌های سالم مطرح باشد.

طرح- مطالعه تجربی

حیوانات- ۴۷ سر خرگوش سالم از نژاد سفید نیوزیلندی (۲۵ سر نر و ۲۲ سر ماده) با سن ۱۸-۱۰ ماه و وزن ۲/۵-۱/۵ کیلوگرم **روش کار-** برای بررسی تاثیر نژاد بر روی VHS، رادیوگرافی از نمای جانبی خوابیده به راست و چپ تهیه و اندازه‌گیری شد. در راستای انجام این تحقیق، طول محور بلند و کوتاه قلب توسط خط‌کش استاندارد و بر حسب میلی‌متر تعیین شد. اندازه‌های بدست‌آمده از چهارمین مهره سینه‌ای به بعد و بر اساس تعداد مهره‌ها مشخص گردید.

نتایج- میانگین \pm انحراف معیار محور بلند قلب $۰/۳۰ \pm ۴/۳۰$ و محور کوتاه $۰/۳۲ \pm ۳/۱$ اندازه مهره بدست آمد. میانگین \pm انحراف معیار VHS در نمای راست به چپ $۰/۳۲ \pm ۷/۶$ و در نمای چپ به راست $۰/۳۱ \pm ۷/۳$ مهره بود. VHS بدست آمده در نمای جانبی خوابیده به چپ بیشتر از نمای خوابیده به راست بود، با این وجود تفاوت معنی‌داری در اندازه محورهای قلب و میزان VHS در نمای جانبی چپ به راست و راست به چپ دیده نشد ($P > ۰/۰۵$).

نتیجه‌گیری و کاربرد بالینی- مقیاس مهره‌ای قلب (VHS) یک روش آسان جهت کاربرد در موارد بالینی می‌باشد. اطلاعات بدست آمده نشان داد که تفاوت معنی‌داری در محور بلند و کوتاه قلب، بین جنس نر و ماده وجود ندارد. همچنین تفاوت معنی‌داری بر اساس سن دیده نشد. این مقادیر بعنوان یک شاخص جدید برای بیماری‌های قلبی در خرگوش مطرح می‌باشند.

کلمات کلیدی- سفید نیوزیلندی، خرگوش، مقیاس مهره‌ای قلب (VHS).

